This is a digital copy of a book that was preserved for generations on library shelves before it was carefully scanned by Google as part of a project to make the world's books discoverable online.

It has survived long enough for the copyright to expire and the book to enter the public domain. A public domain book is one that was never subject to copyright or whose legal copyright term has expired. Whether a book is in the public domain may vary country to country. Public domain books are our gateways to the past, representing a wealth of history, culture and knowledge that's often difficult to discover.

Marks, notations and other marginalia present in the original volume will appear in this file - a reminder of this book's long journey from the publisher to a library and finally to you.

Usage guidelines

Google is proud to partner with libraries to digitize public domain materials and make them widely accessible. Public domain books belong to the public and we are merely their custodians. Nevertheless, this work is expensive, so in order to keep providing this resource, we have taken steps to prevent abuse by commercial parties, including placing technical restrictions on automated querying.

We also ask that you:

+ *Make non-commercial use of the files* We designed Google Book Search for use by individuals, and we request that you use these files for personal, non-commercial purposes.
+ *Refrain from automated querying* Do not send automated queries of any sort to Google's system: If you are conducting research on machine translation, optical character recognition or other areas where access to a large amount of text is helpful, please contact us. We encourage the use of public domain materials for these purposes and may be able to help.
+ *Maintain attribution* The Google "watermark" you see on each file is essential for informing people about this project and helping them find additional materials through Google Book Search. Please do not remove it.
+ *Keep it legal* Whatever your use, remember that you are responsible for ensuring that what you are doing is legal. Do not assume that just because we believe a book is in the public domain for users in the United States, that the work is also in the public domain for users in other countries. Whether a book is still in copyright varies from country to country, and we can't offer guidance on whether any specific use of any specific book is allowed. Please do not assume that a book's appearance in Google Book Search means it can be used in any manner anywhere in the world. Copyright infringement liability can be quite severe.

About Google Book Search

Google's mission is to organize the world's information and to make it universally accessible and useful. Google Book Search helps readers discover the world's books while helping authors and publishers reach new audiences. You can search through the full text of this book on the web at `http://books.google.com/`

LANE MEDICAL LIBRARY STANFORD

Bruguiere 1904. Fav.

LANE

MEDICAL LIBRARY

GIFT

Dr. P.S.Bruguiere

TUMOURS

INNOCENT AND MALIGNANT

TUMOURS

INNOCENT AND MALIGNANT

Their Clinical Characters and Appropriate Treatment

BY

J. BLAND-SUTTON

SURGEON TO THE CHELSEA HOSPITAL FOR WOMEN
ASSISTANT SURGEON TO THE MIDDLESEX HOSPITAL, LONDON

THIRD EDITION

CHICAGO
W. T. KEENER & CO.
1903

First Edition, October, 1893.
Reprinted, 1894. *New Edition*, 1901.
New and Revised Edition, 1903.

364
1903

PREFACE TO THE THIRD EDITION.

In preparing the first edition of this book it was one of my objects not only to furnish the known facts of malignant tumours in general, but also to place before the reader the peculiarities of cancer and sarcoma in relation to the various organs of the body. I attempted what was and still is an impossible task. During the last ten years the great interest taken in this subject has been followed by an increase in what may be called particular knowledge. Careful investigations have brought to light the extraordinary tumour of the uterus known as deciduoma, and have established its frequent and in a sense remarkable relationship with myxomatous disease of the chorion. In this edition I have described deciduoma with the sarcomata provisionally, fully realising the importance of many valuable observations which point to its association with perversions of the chorionic villi.

Our knowledge of primary cancer of the Fallopian tube is now sufficiently extensive and precise to make it a clinical entity: it is now possible to distinguish clinically between cancer and sarcoma of the kidney, and to differentiate renal from adrenal tumours.

Myelomata have been rescued from the banal society of the sarcomata, and the same good fortune has befallen ovarian fibroids. Additions have been made to the chapters on uterine fibroids. They include observations on latent fibroids; the malicious association of fibroids and pregnancy, as well as a

66933

consideration of the perils which fibroids may entail after the menopause—for these bodies, even in obsolescence, are very often mischievous and insidiously lethal.

In this edition the term epithelioma has been abandoned on the suggestion of a very competent critic, and throughout the book is replaced by the phrase squamous-celled cancer. The section on echinococcus colonies has been restored, as its omission from the last edition caused disappointment to many.

I have not discussed the causes of cancer or of sarcoma; they still remain unknown. We must not forget that the causes of the so-called benign tumours are as mysterious as of those that are malign. Until the causes of tumours are detected (and perhaps even then), the only effectual mode of treatment consists in removing them, whenever this is practicable, at the earliest possible moment.

J. BLAND-SUTTON.

47, *Brook Street, W.*,
June, 1903.

EXTRACT FROM THE PREFACE TO THE FIRST EDITION.

(October, 1893.)

Very early in the practice of my profession I became convinced of the great increase in diagnostic power that results from the combination of pathological and clinical knowledge. In 1885 I began to collect materials, from man and other vertebrates, in order to make myself acquainted with the histological peculiarities of tumours. In order to do this I determined to eliminate all those conditions, often classed with tumours, which have been demonstrated to depend on micro-organisms. Attention was first devoted to cysts, and the results of the investigation were embodied in my Hunterian and Erasmus Wilson Lectures, delivered at the Royal College of Surgeons during the years 1886, '87, '88, '89, '90 and '91; they dealt particularly with the group of tumours known as Dermoids, and the genus of cysts which I have ventured to name Tubulo-cysts. During the same period I contributed to the Odontological Society of Great Britain a series of papers to show that many tumours of the jaws, vaguely classed as exostoses, are really derived from aberrant development of teeth.

Whenever it seemed desirable to illustrate the nature of a genus of tumours by reference to Comparative Pathology, I have not hesitated to do so. Without this aid, any attempt to

catch the deeper meaning of many tumours is as difficult as endeavours to decipher a palimpsest in which the first characters, written in an unknown tongue, have been imperfectly removed from the parchment and are allowed to mingle with the second inscription.

CONTENTS.

PAGE

Introduction 1

CHAPTER I.

GROUP I.—CONNECTIVE TISSUE TUMOURS . . . 13

CHAPTER II.

Lipomata 19

CHAPTER III.

Chondromata 32

CHAPTER IV.

Osteomata 40

CHAPTER V.

Odontomes and Dental Cysts 47

CHAPTER VI.

Myelomata 64

CHAPTER VII.

Sarcomata: their Histologic Characters 70

CHAPTER VIII.

Sarcomata: Melanosis, and Melano-sarcomata 78

CHAPTER IX.

Sarcomata: their General Characters 85

CHAPTER X.

Sarcomata of Bones 95

CHAPTER XI.

Sarcomata of the Skull, Jaws, and Vertebræ 105

CHAPTER XII.

Sarcomata of Secreting Glands 111

CHAPTER XIII.

Sarcomata of the Kidney and Adrenal 121

CHAPTER XIV. PAGE
NEUROMATA AND ALLIED CONDITIONS 134

CHAPTER XV.
NEUROMATA AND ALLIED CONDITIONS (*continued*) 143

CHAPTER XVI.
NEUROMATA: GLIOMA 149

CHAPTER XVII.
ANGEIOMA, LYMPHANGEIOMA, AND ENDOTHELIOMA 156

CHAPTER XVIII.
UTERINE FIBROIDS 169

CHAPTER XIX.
UTERINE FIBROIDS (*continued*) 180

CHAPTER XX.
MODES IN WHICH UTERINE FIBROIDS IMPERIL LIFE 187

CHAPTER XXI.
UTERINE FIBROIDS IN RELATION TO MENSTRUATION, PREGNANCY, AND THE MENOPAUSE 195

CHAPTER XXII.
OVARIAN FIBROIDS 203

CHAPTER XXIII.
GROUP II.—EPITHELIAL TUMOURS 207

CHAPTER XXIV.
CUTANEOUS HORNS 219

CHAPTER XXV.
ADENOMA 225

CHAPTER XXVI.
CARCINOMA (CANCER) 230

CHAPTER XXVII.
CARCINOMA OF THE BREAST 242

CHAPTER XXVIII.
EPITHELIAL TUMOURS OF SEBACEOUS GLANDS AND RODENT CANCER . . 254

CHAPTER XXIX.
EPITHELIAL TUMOURS OF THE THYROID GLAND 261

CHAPTER XXX.
CARCINOMA OF LIPS, MOUTH, TONGUE, PHARYNX, AND LARYNX . . 267

PAGE

CHAPTER XXXI.
CARCINOMA OF THE DIGESTIVE TRACT 275

CHAPTER XXXII.
EPITHELIAL TUMOURS OF THE LIVER, GALL BLADDER, AND PANCREAS . 290

CHAPTER XXXIII.
CARCINOMA OF THE URINARY ORGANS 297

CHAPTER XXXIV.
CARCINOMA OF THE EXTERNAL GENITAL ORGANS 305

CHAPTER XXXV.
EPITHELIAL TUMOURS OF THE UTERUS 311

CHAPTER XXXVI.
EPITHELIAL TUMOURS OF THE UTERUS (*concluded*) 321

CHAPTER XXXVII.
EPITHELIAL TUMOURS OF THE FALLOPIAN TUBE AND THE OVARY . . 328

CHAPTER XXXVIII.
GROUP III.—DERMOIDS 335

CHAPTER XXXIX.
SEQUESTRATION DERMOIDS 342

CHAPTER XL.
SEQUESTRATION DERMOIDS (*concluded*) 348

CHAPTER XLI.
TUBULO-DERMOIDS 359

CHAPTER XLII.
TUBULO-DERMOIDS (*concluded*). BRANCHIAL FISTULÆ . . . 370

CHAPTER XLIII.
CERVICAL AURICLES 377

CHAPTER XLIV.
MOLES. 386

CHAPTER XLV.
OVARIAN DERMOIDS 392

CHAPTER XLVI.
OVARIAN DERMOIDS (*continued*) 403

CHAPTER XLVII.
AXIAL ROTATION OF OVARIAN TUMOURS, ETC. 413

CHAPTER XLVIII. PAGE

TERATOMATA 421

CHAPTER XLIX.

GROUP IV.—CYSTS 433

CHAPTER L.

HYDRONEPHROSIS 440

CHAPTER LI.

CONGENITAL CYSTIC KIDNEY 452

CHAPTER LII.

TUBULO-CYSTS 460

CHAPTER LIII.

TUBULO-CYSTS (*continued*) 466

CHAPTER LIV.

TUBULO-CYSTS (*concluded*) 478

CHAPTER LV.

HYDROCELE 483

CHAPTER LVI.

PSEUDO CYSTS—DIVERTICULA AND BURSÆ 491

CHAPTER LVII.

PSEUDO-CYSTS (*concluded*)—SYNOVIAL CYST, GANGLION, AND BURSA . 500

CHAPTER LVIII.

NEURAL CYSTS 510

CHAPTER LIX.

NEURAL CYSTS (*concluded*) 521

CHAPTER LX.

ECHINOCOCCUS COLONIES (HYDATID CYSTS) 533

INDEX TO TUMOURS 549

INDEX TO ORGANS 553

TUMOURS

INNOCENT AND MALIGNANT:

Their Clinical Characters and Appropriate Treatment.

INTRODUCTION.

Classification.—Any thoughtful individual, on commencing the study of tumours, must doubtless have been struck by the confusion which prevails in oncological literature in regard to the use of such terms as classes, groups, species, varieties, etc. This confusion will be more obvious if the student be acquainted even in a moderate degree with Systematic Zoology. Not that the zoologist can in any way claim to have discovered a perfect method of classification, but he certainly uses the terms genus, species, etc., in a consistent manner.

In the present work an attempt will be made to classify tumours on similar lines to those employed in Biology. The classification adopted is one which will not, in any serious way, involve the Taxonomy (if it be worth such a name) at present in fashion.

It is certain that the efforts of J. Müller (1838) to classify tumours according to their minute structure had a great influence in promoting the study of Oncology. Virchow's labours on the histology of tumours, and especially his success in demonstrating that all the tissues found in them have a physiological prototype, have made it plain that it is impossible, in any useful classification of tumours, to neglect to take into consideration their structural characters.

To-day it must be clear to all who study Virchow's great work, "Die Krankhaften Geschwülste" (1863), in the light of our present knowledge, that he employed the term

tumour in a too comprehensive manner. It is highly desirable to exclude from tumours those formations known as *infective granulomata*, and there can be no doubt that this group will be largely increased in the near future, as it has been in the recent past, at the expense of sarcomata, and, in all probability, of the carcinomata, as our knowledge of the biology of micro-organisms increases.

The abnormal conditions to which the term tumour is now restricted clinically can be arranged in four groups:—

I. Connective tissue tumours.
II. Epithelial tumours.
III. Dermoids.
IV. Cysts.

Each group contains several genera, and each genus comprises one or more species. In the first three groups a genus is determined by the particular tissue composing the tumours.

The groups are formed of a number of genera allied to each other in the possession of a common character. Thus Group I. comprises all tumours composed of connective tissues, whereas in Group II. the essential structural character is the presence of epithelium. Group III. is a very remarkable collection of tumours containing skin or mucous membrane occurring in abnormal situations. Group IV. comprises the important aberrations of pre-existing spaces known as cysts, and though cysts differ in many points from tumours, they are in many of their features so closely allied that it is customary, as well as convenient, to consider them under the term tumour in its most extended sense.

Before beginning the systematic description of the various groups, it is necessary to consider some peculiarities relating to the effects of tumours upon the individual, which are of the greatest clinical importance.

In the connective tissue and the epithelial groups some of the genera display what is known as malignancy; hence it is customary to speak of tumours as being innocent or malignant.

Malignant Tumours.—These exhibit the following characters: (1) They infiltrate the surrounding tissues; (2) they

infect adjacent lymph glands; (3) they tend to recur after removal; (4) they become disseminated in distant organs; and (5) inevitably destroy life.

Innocent Tumours.—These are, as a rule: (1) Encapsuled and, when diffuse, do not infiltrate; (2) they do not infect the lymph glands; (3) nor recur after complete removal;

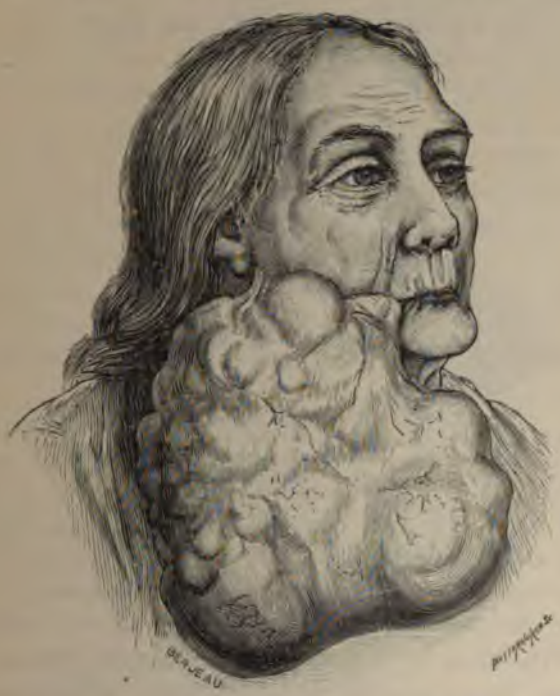

Fig. 1.—Chondroma of the submaxillary gland which had been slowly growing forty-four years.

(4) they do not disseminate; and (5) they only imperil life when they grow in the vicinity of vital organs.

There are two genera of tumours to which the adjective malignant is especially applicable—sarcomata and carcinomata.

It is important to bear in mind that innocent tumours may, and often do, destroy life. The essential difference between an innocent and a malignant tumour may be expressed thus: *The baneful effects of innocent tumours depend*

entirely on their environment, but malignant tumours destroy life whatever their situation.

It may be useful to describe some examples which will illustrate the importance of environment in relation to the destructive effects of tumours of all kinds.

A tumour consisting of hyaline cartilage (a chondroma) is a typical example of a benign species. The specimen represented in Fig. 1 arose in the submaxillary gland of a woman. When first detected it was as big as a cherry. For many years the tumour grew very slowly and caused little inconvenience. After forty-four years the mass became so cumbrous that she submitted to operation at the age of seventy-four.

A very small tumour will sometimes destroy life when it occupies a vital organ. Thus a girl of fourteen years was seized with paraplegia and died in ten days. The cervical segment of the cord contained a tumour of the size and shape of a small olive. (Fig. 2.)



Fig. 2.—The cervical segment of the cord in transverse section, showing a tumour in the grey substance.

Small tumours occasionally cause death even when they are not connected with organs so vital as the spinal cord. For example, the specimen represented in Fig. 3 is a portion of the jejunum of a man who suffered from subacute intestinal obstruction. At the operation the jejunum near the middle of its length was found invaginated by a pedunculated (polypus) tumour which grew from the submucous tissue. Surgical aid was tendered too late, as general peritonitis had become established; the infection spread from an abscess in the pedicle of the tumour. Lipomata of the jejunum have been known to produce a similar disaster (see p. 24).

Some of the most tragic deaths due to tumours structurally benign occur in connection with the air passages. For example, a man thirty-six years of age was found lying on his back in a street adjacent to the Middlesex Hospital, apparently in a fit; when brought into the casualty-room he was dead. At the *post-mortem* examination a tumour was found connected with the cervical section of the windpipe. This tumour was

an enlarged accessory thyroid gland; it was embedded in a thick fibrous capsule, its inner segment being firmly fixed to the trachea in the neighbourhood of the fourth to ninth semi-rings. The tumour, including its capsule, was somewhat larger than a dove's egg (Fig. 4), but it had severely compressed the

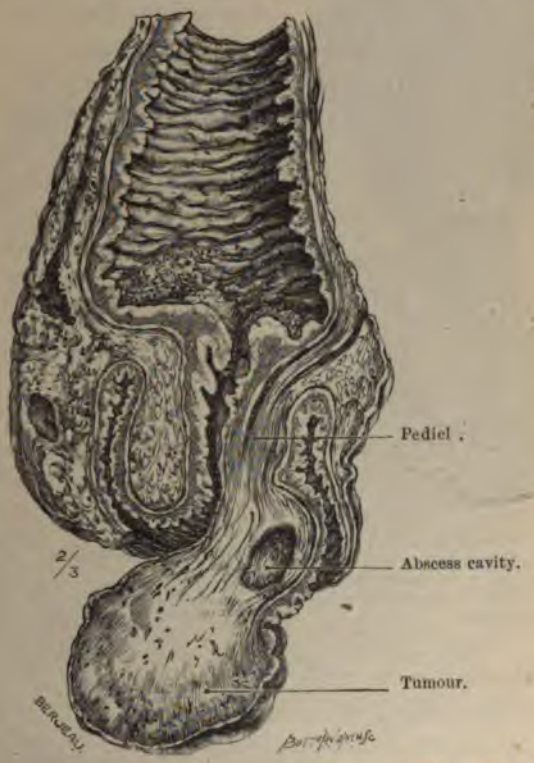

Fig. 3.—Portion of jejunum in section; a pedunculated tumour had invaginated the bowel and produced intestinal obstruction. (From a man 35 years of age.)

trachea, so that on section this presented at the seat of compression the form shown in Fig. 5.

The central part of the tumour exhibited under the microscope the characteristic structure of thyroid gland. The capsule consisted of dense laminæ of fibrous tissue. Had this tumour been recognised during life it could have been easily enucleated from its capsule.

The preceding examples show that the tumours classed as

benign or innocent are only dangerous when from their position they mechanically interfere with vital organs, or obstruct functions necessary to the maintenance of life. Malignant tumours, on the other hand, destroy life in whatever situation they arise. Melanotic tumours illustrate this very well. A man fifty years of age came under my observation with an intra-ocular tumour no larger than a cherry-stone growing from the uveal tract. The eyeball was promptly excised and the tumour, which in this case had a deep black hue, had remained strictly confined to the globe. Within two years this man died with secondary tumours in the liver and many other organs; his skin turned quite black, melanin appeared daily in the urine, and the free fluid in his belly also contained pigment in abundance. The amount of dissemination met with in some of these cases is truly astonishing. On one occasion I counted three thousand discrete spots of pigment in the skin of a man whose eye had been enucleated two years previously for a sarcoma of the uveal tract.

Fig. 4.—An enlarged and encapsuled accessory thyroid gland. It compressed the trachea and produced fatal dyspnœa.

It is when tumours arise in non-vital organs, such as the eye, the finger, or femur, and destroy life in a few months, that malignancy is most significantly expressed. The following is one of the most deadly examples which ever came under my notice. An actor, twenty-four years of age, felt pain in his knee; a month later it was clear that a sarcoma

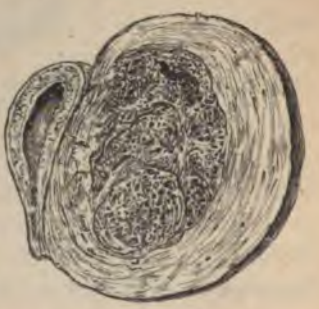

Fig. 5.—Section of the enlarged accessory thyroid gland and trachea, showing the amount of stenosis. (Natural size.)

occupied the lower end of his femur. Two months later he came under my care, and the leg was promptly amputated. The tumour, a periosteal sarcoma, had circumscribed the lower portion of the femur (Fig. 6). A few days after the operation difficulty of breathing began to declare itself, and a month after the operation the man died, slowly suffocated. At the *post-mortem*

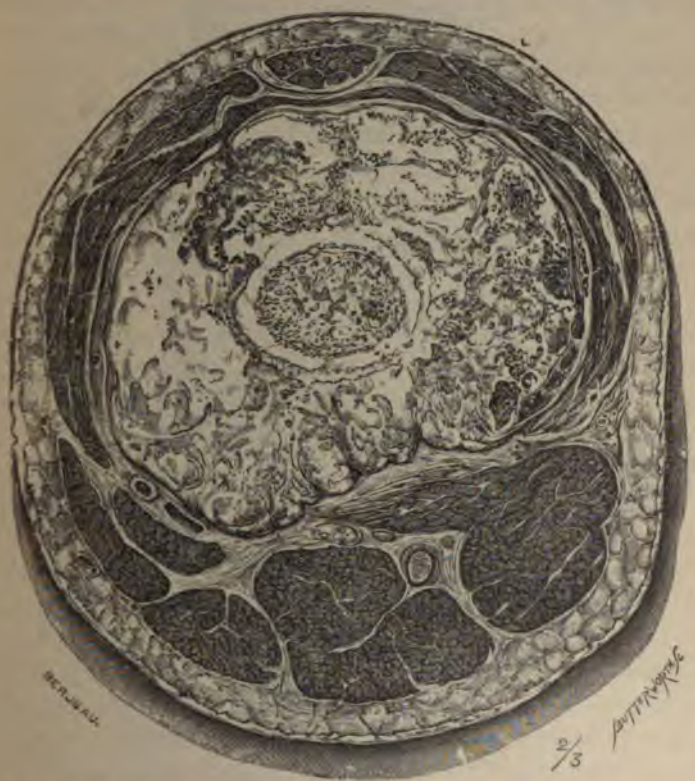

Fig. 6.—An ossifying spindle-celled sarcoma of the femur: in transverse section.

examination secondary deposits were found in the liver, pancreas, and ileum. The lungs were thickly occupied with secondary deposits; and a large conglomerate mass as big as the fist compressed the trachea and adjacent segments of the bronchi. All the secondary deposits were hard and grated under the knife, and some of them seemed to be contained in an imperfectly formed osseous capsule, or shell.

In its general characters—the disposition of the secondary deposits and in the mode by which it destroyed this man—the sarcoma displayed thoroughly the usual features of an ossifying periosteal sarcoma of the femur. This man had no notion that

Fig. 7.—Lobe of a lung in section: the trachea and bronchus are compressed with sarcomatous tissue secondary to an ossifying sarcoma of the femur.

anything was wrong with his thigh until October, and by the middle of the following February he was suffocated by large secondary nodules of sarcoma compressing the bronchi.

Although it is true that malignant tumours destroy life in whatever position they arise, nevertheless, environment exercises great influence in the rapidity as well as the mode in which

they kill. For instance, a cancer of the larynx may cause death from suffocation, but it is more frequently fatal by setting up septic pneumonia in consequence of the inhalation of septic matter from the sloughing surface of the growth. Cancer of the gastric orifices usually entails death from starvation, and malignant disease of the prostate destroys life by leading to renal disorders consequent upon impediment to the free escape of urine from the bladder.

It may be stated almost as an axiom that when a malignant tumour implicates a vital organ it will often destroy life before there has been time for dissemination. When the environment has been unfavourable in this respect death is usually induced by secondary nodules occupying important organs, *e.g.* lungs, liver, brain, etc. This is a matter which will receive careful attention in the description of malignant disease as it attacks different organs. It is, however, a very remarkable fact that while a periosteal sarcoma of the femur is the most deadly tumour which attacks the human frame, a sarcoma of the tibia with the same histologic characters will, with precisely the same treatment (amputation), take as many years to destroy life as the tumour of the femur required months. This would appear to indicate that the two tumours, though structurally alike, really have different causes, yet there are facts which lead us to suspect that variations in tissue actually constitute an altered environment. The only condition which supports this view in a positive way is hydatid disease. The final chapter of this book contains abundant evidence as to the effects of environment on the character of echinococcus colonies, besides illustrating the varied manner in which the surroundings determine the mode by which these parasites often induce the death of human beings, their involuntary intermediate hosts.

Some of the most terrible examples illustrating dangerous environment are inconspicuous solid ovarian tumours and dermoids, incarcerated in the pelvis by a gravid uterus. In many instances the presence of a tumour is unsuspected even when the woman has been hours in labour. Obstruction of this kind is very fatal to the child and often to the mother, and the injuries which women sustain in such circumstances are

in an organ already occupied by a tumour. For example, the uterus may be the seat of a large fibroid, and carcinoma may subsequently arise in the endometrium. Mammary carcinoma and ovarian adenoma occasionally grow concurrently; or cancer may arise in the mamma a year or more after the removal of an ovarian tumour.

Two examples of the co-existence of pyloric cancer and ovarian adenoma have come under my observation, and on one occasion I removed a neuroma from the seventh cervical nerve and a cancerous breast from the same patient on the same day. A very rare combination, observed by Hutchinson, is an adenoma of a mamma embedded in a mammary carcinoma. The woman was forty-six years of age, and had noticed a lump in her breast for twenty years (Fig. 8).

The infiltrating properties of malignant tumours, their powers of dissemination, and the phenomenon of lymph gland infection will be described in the sections relating to sarcomata and carcinomata respectively.

CHAPTER I.

GROUP I.—CONNECTIVE TISSUE TUMOURS.

SINCE Virchow (1863) demonstrated that all the tissues found in tumours have a normal histologic prototype, and as complete ignorance exists as to the pathogenesis or cause of tumours, it is necessary for the purpose of classification to use their histologic features as a base. Hence it is customary to classify the members of the connective tissue group into genera according to the tissue which preponderates. Thus a tumour composed of fat is a fatty tumour (lipoma); one composed mainly of cartilage is called a chondroma, and one of bone is an osteoma, and so on. The subjoined list contains the names of the various genera of the connective tissue group:—

Lipomata (tumours composed of fat).

Chondromata (tumours consisting of hyaline cartilage).

Osteomata (tumours composed of bone).

Odontomes (tumours arising from developing teeth).

Fibromata, Myxomata, and Myomata.

Myelomata (tumours composed of red bone-marrow).

Sarcomata (malignant tumours composed of embryonic connective tissue).

Neuromata. (This genus includes tumours arising from the sheaths of nerves, as well as those which contain nerve cells; and the gliomata.)

Angeiomata.

Lymphangeiomata. (This genus comprises endothelioma as well as lymphatic nævi and cysts.)

It may be regarded as a postulate that the histology and embryology of an organ enable an experienced oncologist to predict the various genera of tumours and cysts to which it may be liable. Thus the tibia of a child contains cartilage, bone, fibrous tissue, young connective tissue, fat and red

marrow. The epiphysial cartilages are the source of chondromata; the bone furnishes osteomata, the periosteum sarcomata, and very rarely lipomata, and myelomata arise in the red marrow. Cancers do not arise primarily in bone, as it lacks epithelium, but they often occur as secondary deposits.

Although our knowledge of the intimate structure of tumours, thanks to differential staining methods, is now sufficient to enable us to indicate from the structure of an organ the genera of tumours to which it may be liable, nevertheless, the most careful study of the minute structure of such organs as the salivary glands would not lead us to suspect their liability to pure chondromata; and it is strange that they should occur in the parotid, submaxillary, and lacrimal glands, and yet be unknown in the pancreas. What oncologist, merely from studying the histology of a normal ovary, would suspect that it would be the point of origin of a dermoid? It is like studying the fauna of a country. For instance, who imagined, until Australia was discovered, the existence of extraordinary mammals like kangaroos and duck moles? But knowledge gained from observation enables us to state that gliomata do not arise in bone, nor myomata in the brain, nor dermoids in the spleen, liver, or kidney, with the same certainty that we assert that at the present period of our planet's history lions do not sport about the ice-fields of Greenland nor humming-birds flit about the flower beds of Hyde Park.

It is, however, necessary to point out that, although the tissues of an organ determine the species of tumour to which it may be liable, their relative frequency can only be gathered from observation.

The variations in the liability of the organs of the body to tumours is a very curious matter. The heart is very rarely occupied by a tumour; on the other hand, the uterus, a muscular organ, is with extreme frequency the seat of myomata. The liability of bones to sarcomata is proverbial, yet a sarcoma of a voluntary muscle is a rarity. A primary tumour of the lung is a phenomenon, but it is common enough in the brain or the eyeball. Sarcomata are frequent in the kidneys, but a primary sarcoma in the liver or spleen is extremely rare. These

and many kindred questions indicate profound imperfections in our knowledge.

Another feature connected with the genera of this group is the inability of even very experienced oncologists to determine in certain cases from the minute structure of a tumour whether it be innocent or malignant. This is a matter of great importance, and, indeed, has led some observers to believe that in certain circumstances an innocent tumour may gradually

Fig. 9.—Lipoma of the sole which had existed for thirty years. It was removed by Percival Pott. (*Museum of St. Bartholomew's Hospital.*)

assume malignant characters. This is a most difficult matter to decide. For example, few pathologists would venture to suggest that a lipoma is likely to become malignant even when very greatly irritated (Fig. 9). The same holds true of angeiomata, osteomata, chondromata, and neuromata ; but the improvements in histological chemistry and increased precision in the use of terms have served to show that sarcomata grow from the uterus and the sheaths of nerves ; also that the tissue of a rapidly growing sarcoma actually undergoes chondrification, and in

certain situations may even form striped spindles identical with the embryonic stages of striated muscle cells.

Experience teaches that the more closely the tissue of a tumour resembles the matrix in which it arises the less likely is it to be malignant.

In deciding questions relating to the innocency or malignancy of tumours, the clinical as well as the histologic features require consideration. When a tumour is encapsuled it is a most favourable feature, but care is required to distinguish between a true capsule and the spurious form of encapsulation exhibited by sarcomata limited by expanded bone or renal tissue. The difference is well exemplified by ovarian tumours: for example, an adenoma of the ovary may grow so large as to weigh more than the body of the individual containing it, yet its capsule remains absolutely defined, though it adhere to bowel, bladder, or even the liver; on the other hand, an ovarian sarcoma of moderate size may infiltrate everything in its neighbourhood.

Perhaps the greatest difficulties in the classification of the tumours of this group occur with those known as fibromata, myxomata, and myomata, and it will be useful to indicate some of them.

Fibromata, or tumours composed of fibrous tissue, were formerly supposed to be very common, but careful histological research has shown that tumours consisting almost entirely of fibrous tissues are rare. For instance, it was the fashion to describe as fibromata those tumours of the uterus now known as myomata and fibro-myomata; traces of this belief linger still in the term "uterine fibroids." Many tumours now recognised as spindle-celled sarcomata were a few years ago named "recurring fibroids." The difficulty of distinguishing between a myoma, a slowly growing spindle-celled sarcoma, and a pure fibroma is well known to skilled histologists.

A tumour with the structure of a fibroma growing on the gums was called an epulis, but the term never had more than a topographical significance. When such a tumour grew on a nerve it was termed a neuroma. Fibroids of the uterus are of such significance that they demand several chapters for their proper consideration. Ovarian fibroids have

recently been extricated from the spindle-celled sarcomata. (Chap. XXII.)

Myxomata.—These are tumours composed of tissue identical with the jelly-like substance which exists in the umbilical cord. Here we have to deal with a difficulty, because there is a very great tendency in many connective tissue tumours to degenerate into this soft gelatinous or myxomatous tissue and become as diffluent as the vitreous body in the eyeball.

The common nasal polypus furnishes an excellent example of this tissue; it consists of cells with long, slender processes interlacing with those of adjacent cells and ramifying in a structureless, unstainable, diffluent mass, the whole being bounded by a thin layer of mucous membrane covered with columnar ciliated epithelium. Nasal polypi may be regarded as pendulous processes of œdematous mucous membrane.

The condition termed an aural polypus has no claim to rank as a tumour; it consists of myxomatous tissue. Jacobson * has suggested that tympanic polypi consisting of myxomatous tissue may arise in vestiges of the fœtal connective tissue which fills the tympanum at birth and slowly disappears as pulmonary respiration is established.

The tumours which have come under my notice and to which the term myxoma most properly applies have grown from the lumbar fascia: they were sessile tumours, and when cut open looked like colourless masses of transparent trembling jelly. These tumours recurred after removal; in one case there were several recurrences extending over a period of ten years. There was no evidence of dissemination. It is probable that they were sarcomata which had undergone myxomatous degeneration. It would be convenient and perfectly justifiable to deprive myxomata of even the rank of species among tumours.

The heart is of all the organs of the body the least liable to tumours, primary or secondary, yet the few examples of primary tumours which have been observed in it are described by the reporters as fibromata, or myxomata, or fibro-myxomata. The chief cases have been collected and the clinical signs analysed

* *Guy's Hosp. Rep.*, 1882, vol. xli. 217.

by Pavlowsky of St. Petersburg in the *Berliner klinische Wochenschrift*, 1895, s. 393.

Myomata, or tumours composed of unstriped muscle fibre, are very rare, and are met with exclusively in organs containing this tissue, *e.g.* the œsophagus, stomach, duodenum, bladder, and uterus.

Attention has already been directed to the difficulty of determining between the fusiform cells of sarcomata and unstriped muscle fibre. This difficulty is further increased by the fact that many malignant tumours composed of spindle cells (sarcomata) contain tracts of cells which present a transverse striation such as is seen in voluntary muscle in its embryonic stage; but it is remarkable that cells with the transverse striation occur in situations where voluntary muscle is not found normally. It is also a fact that tumours consisting of mature striated (voluntary) muscle fibre have not been observed. Much caution needs to be exercised before deciding that a tumour is a myoma; formerly many of the spindle-celled sarcomata of the choroid were regarded as myomata arising in the ciliary muscle. It is also extremely probable that many of the tumours described as myomata from the œsophagus,* stomach, duodenum, bladder,† vagina, and skin ‡ were sarcomata.

* Hilton Fagge, *Trans. Path. Soc.*, vol. xxvi. 94.

† Parker, *Trans. Clin Soc.*, vol. xxi. 58; and Terrier and Hartmann, *Rev. de Chir.*, 1895.

‡ Marc, *Virchow's Arch.*, bd. cxxv. 543.

CHAPTER II.

LIPOMATA.

A **lipoma** is a tumour composed of fat; the genus consists of a single species. With the exception of sarcomata it is the most generalised genus of tumours which occurs in man. It therefore will be convenient to consider lipomata according to the situations in which they arise, such as the subcutaneous and subserous tissues; beneath synovial or mucous membranes; between or even in muscles; or in connection with periosteum and the meninges of the brain and spinal cord.

1. **Subcutaneous Lipomata.**—Beneath the skin there exists a layer of fat, which varies in thickness in different parts, but is most abundant over the trunk and trunk ends of the limbs. This subcutaneous fat is a common situation in which to find lipomata. Usually they occur as irregularly lobulated encapsuled tumours, more or less adherent to the skin. Unless they have been irritated, lipomata are movable within their capsules. Generally one lipoma is present, but two, ten, twenty, or more may occur concurrently on the same individual. In size they vary widely; a lipoma weighing sixteen ounces is a tumour of fair size; exceptional specimens have been reported to weigh fifty, eighty, and even one hundred pounds. Although subcutaneous lipomata are for the most part confined to the trunk and trunk ends of limbs, they may arise on the distal parts of the limbs, such as the hands and feet. Many specimens have been observed in the palm of the hand (Fig. 10), a situation in which they are apt to give rise to difficulty in diagnosis, more especially as they simulate compound ganglia of the flexor tendons. The lobes of fat are apt to burrow beneath the palmar fascia, and it is probable that some lipomata of the palm originate beneath this fascia, in the lobules of fat lying between the lumbricales. A lipoma has been observed on the back of the hand of a boy eight years old, and a process of the

tumour passed between the third and fourth metacarpals into the palm (Pupovac *). Fatty tumours are occasionally found on the fingers: Steinheil † has collected a large number of examples. A lipoma in the sole is more comprehensible than one in the palm, yet, strange to relate, they are far more frequent in the hand than in the foot (Fig. 9); in both situations

Fig. 10.—Lipoma in the palm.

they are apt to be congenital, and nearly always cause doubt in diagnosis.‡

Subcutaneous lipomata are often symmetrical, and are apt to become pedunculated, especially when growing from the thigh. Pedunculated lipomata are never very large, and when the pedicle is thin it will become twisted by the rotatory move-

* *Wiener klin. Woch.*, January 19th, 1899.

† Bruns' *Beiträge*, bd. vii. 605.

‡ Gay, *Trans. Path. Soc.*, vol. xiv. 243. and Lockwood, *ibid.*, vol. xxxvii. 450.

ments of the tumour, the growth of which will in consequence be arrested, or at least checked.

Fatty tumours are rarely met with upon the head or face, but I have on three occasions removed a lipoma from beneath the skin covering the temporal fascia. There is a variety of fatty tumour sometimes called, on account of its vascularity, *nævo-lipoma:* this may be a nævus which has undergone fatty degeneration. Probably some of the vascular lipomata which occasionally occur on the face are of this nature.

Fatty tumours which have existed many years sometimes calcify, the earthy matter being deposited in the fibrous septa of the tumours. A partially calcified lipoma is preserved in the museum of St. Bartholomew's Hospital which came from the arm of an Arab sheikh, where it had existed fifty years. Calcification may be associated with saponification of the fat.

The subcutaneous fat in the neck, axilla, and groin sometimes forms irregularly lobulated masses called diffuse lipomata, but they are not strictly tumours (Fig. 11).

2. **Subserous Lipomata.**—The peritoneum, like the skin, rests upon a bed of fat, the thickness of which varies considerably. Lipomata occurring in subserous tissue are sessile, or pedunculated.

Surgeons have long been aware, in operating for inguinal or femoral hernia, that occasionally they come across a mass of fat, and find difficulty in determining whether it be omental or a local increase of the subserous fat surrounding the hernial sac. It is now clear that in the neighbourhood of the femoral and inguinal canals an overgrowth of the subserous fat may occur and be mistaken for a hernia, and individuals have been recommended to wear, and have actually worn, trusses for fatty masses of this character. It is also clear that as these local overgrowths of fat arise and protrude in the groin, they occasionally draw with them a pouch of peritoneum unassociated with a hernia. These pouches may afterwards lodge a piece of gut, and become true hernial sacs. Thus peritoneal pouches, produced mechanically by subserous lipomata, may subsequently become hernial sacs; on the other hand, lipomata may arise in relation with peritoneal pouches which were originally hernial sacs. In some cases a subserous

lipoma of this character will invaginate a peritoneal pouch and form a pedunculated tumour within the hernial sac. More rarely a fatty tumour will arise in connection with the spermatic cord. Gabryszewski * has collected the more important cases, and discussed the difficulty such tumours cause in diagnosis. Andrewes recorded a case which appeared to be a lipoma of the spermatic cord, but on microscopic examination it exhibited the structure of an adrenal. Fatty tumours arise in the scrotum or labium without being connected with hernial pouches.†

Fig. 11.—Diffuse lipoma of the neck. (*After Morrant Baker.*)

Lipomata arising in the subperitoneal tissue occasionally appear in the anterior abdominal wall, especially near the umbilicus; they are known as "fatty herniæ of the linea alba," and are frequently associated with peritoneal pouches.

Lipomata sometimes grow between the layers of the mesometrium, and in some instances are so large as to simulate ovarian tumours.‡

Masses of fat, in many respects resembling the so-called "diffuse lipoma" of the subcutaneous tissue, have been

* *Deutsche Zeitsch. f. Chir.*, bd. xlvii. 317.

† J. Hutchinson, jun., *Trans. Path. Soc.*, vol. xxxvii. 451, and vol. xxxix. 451.

‡ Parono, *Ann. di Ostet. Milano*, 1891, xiii. 103, pl. 1, and Treves, *Trans. Clin. Soc.*, vol. xxvi. 101.

removed from the abdomen weighing thirty and even fifty pounds.*

Hernial lipomata are interesting, for they explain the mode in which appendices epiploicæ arise: these are localised pedunculated overgrowths of subserous fat, and are particularly large and arborescent in the neighbourhood of an old syphilitic stricture of the rectum.

In well-nourished individuals the fat of the appendices epiploicæ is directly continuous with the fat in the layers of the mesentery; when wasting occurs the fat between the appendices and the mesentery is liable to atrophy and leave an adipose nodule at the bottom of a peritoneal pouch. The movements of the intestine and the traction of the nodule lead to the formation of a pedicle which often becomes twisted; sometimes the pedicle is so thin that it breaks, and the appendix is set free. Pieces of fat, not unfrequently calcified, detached in this way, have been found in hernial sacs.

A fatty tumour may arise in the fat behind the ensiform cartilage, and, extending through the gap in the diaphragm in this situation, occupy the lower end of the anterior mediastinum.

Rokitansky pointed out that the subpleural fat in the intercostal region sometimes formed a lobulated mass and prolapsed into the sac of the pleura. C. Gussenbauer † has described and figured a subpleural lipoma which made its way on each side of the ribs. The two lobes were joined by a narrow isthmus so as to form an intra- and an extra-thoracic portion; the latter bulged under the pectoralis major and simulated a sarcoma.

3. **Submucous Lipomata.**—Fat exists in submucous tissue in many situations, and like that in the subcutaneous tissue is not unfrequently the source of lipomata.

(*a*) *Subconjunctival Lipomata.*—These occur near the line where the conjunctiva is reflected from the lower lid to the eyeball; they are almost entirely confined to children. Fatty tumours sometimes arise from the orbital fat and cause the

* Pick, *Trans. Path. Soc.*, vol. xx. 337, and Cooper Forster, *Trans. Path. Soc.*, vol. xix. 246.

† *Arch. f. klin. Chir.*, 1892, bd. xliii., s. 322.

conjunctiva to protrude in the neighbourhood of the lacrimal gland and near the insertions of the ocular muscles.

(*b*) *The Lips.**—Lipomata in this situation are very rare and never large.

(*c*) *Laryngeal Lipomata.*—A few remarkable examples have been reported. Holt † met with a pedunculated lipoma 22.5 cm. in length, which grew from the side of the left aryteno-epiglottic fold and extended into the œsophagus. Sidney Jones ‡ removed a lipoma from the right aryteno-epiglottic fold of a man 40 years of age. The patient could protrude the tumour into his mouth.

(*d*) *Gastric Lipomata.*—Virchow § has figured a lipoma which grew beneath the mucous membrane near the pylorus; it was as big as a nut.

(*e*) *Intestinal Lipomata.*—A submucous fatty tumour of the small or the large intestine is very rare, and in both situations may be occasionally inimical to life. The danger of a lipoma of the ileum is well set out in a case recorded by Stabb ||; the tumour arose in the submucous tissue 75 cm. from the ileo-cæcal valve; in size and shape it resembled three acorns conjoined at the cups, and it caused intussusception of the bowel. The invagination was reduced and the tumour excised. Unfortunately the mucous membrane sloughed, and the patient, a man of 32 years, died. The specimen is preserved in the museum of St. Thomas's Hospital.

I successfully removed from a man 44 years of age a lipoma, weighing two ounces, which occupied the submucous tissue of the ascending colon, 5 cm. above the ileo-cæcal valve. The patient had passed through several acute attacks of intestinal obstruction.¶ During the operation in this case I saw that the serous coat over the tumour was dimpled. Stabb noticed the same condition in his case, so that it is quite possible that these lipomata, though projecting into the gut, really arose in the subserous stratum of fat.

* Edmunds, *Trans. Path. Soc.*, vol. xliv. 151.

† *Trans. Path. Soc.*, vol. v. 123.

‡ *Trans. Path. Soc.*, vol. xxxii. 243.

§ "Die Krankhaften Geschwülste," bd. i. 372.

|| *St. Thomas's Hosp. Rep.*, 1894, vol. xxiii. 115.

¶ *Lancet*, 1900, vol. i. 1437. Lawford Knaggs, *ibid.*, vol. ii. 1573.

Submucous fatty tumours have been observed on several occasions in the jejunum and colon. The great danger is, of course, their liability to obstruct the intestine.*

4. **Subsynovial Lipomata.**—Beneath the subserous tissue of large joints, such as the knee, there is a layer of fat of varying thickness. This fat may, as in the case of inguinal lipomata, increase in quantity and, projecting into the joint, form a fatty tumour. A common situation for this to occur is beside the patella, at the spot normally occupied by the alar ligaments. Many specimens are doubtless due to overgrowth of the fat in the alar fringes, but they may arise in other parts of the joint.

The best-known variety of subsynovial fatty tumour is that to which Müller applied the term "lipoma arborescens." This condition is often, but by no means always, associated with rheumatoid arthritis. A typical specimen (Fig. 12) consists of small finger-like processes of fat projecting into the cavity of the joint; each process is covered by synovial membrane. The lipoma arborescens bears precisely the same relation to the synovial membrane that the appendices epiploicæ bear to the peritoneal investment of the colon and sigmoid flexure.

5. **Intermuscular Lipomata.**—Fatty tumours now and then arise in the connective tissue between muscles; they have been found between the greater and lesser pectorals, between the muscles of the tongue, and the intermuscular strata of the anterior abdominal wall. In the last-mentioned situation they have been known to attain prodigious proportions.†

The most remarkable example of this variety of lipoma arises in connection with the sucking-cushion (Fig. 13). This curious ball of fat is situated between the masseter and buccinator muscles, and comes into close relation with the buccal mucous membrane. It is believed to play an important function in connection with sucking, by distributing atmospheric pressure

* Hillier, "Ueber Darmlipome," Bruns' *Beiträge*, bd. xxiv. 509; and Langemak, "Zur Kasuistik der Darmlipome," *ibid.*, bd. xxviii. 247.

† Sir Astley Cooper, *Medico-Chir. Trans.*, vol. xi. 440. Eve, *Trans. Path. Soc.*, vol. xxxix. 295. Abdel-Fattah Fehmy, *Brit. Med. Journal*, 1893, vol. i. 459.

and preventing the buccinators from being forced between the alveolar arches when a vacuum is created in the mouth. They are relatively much larger in infants than in adults. Ranke * also points out that in emaciated children the cushions are only slightly diminished in size even when there is scarcely any subcutaneous fat.

The sucking-cushions sometimes enlarge in adults, and

Fig. 12.—Lipoma arborescens of the shoulder-joint.

A. Acromion. G. Coracoid. F. Glenoid fossa.

simulate more serious species of tumours, and it is curious that in some of the recorded cases the enlargement of the cushion has been associated with the impaction of a salivary calculus in the duct of the parotid gland.† The association of an

* Virchow's *Arch.*, bd. xcvii. 527.

† Berger, *Gaz. des Hopitaux*, Nov. 15, 1883; and Owen, *Lancet*, 1890, vol. ii. 71.

impacted salivary calculus and an enlarged sucking-cushion is interesting in relation with an observation of Norman Moore, who found a large collection of fat around a ureter at the site of an impacted calculus. (Museum, Royal College of Surgeons, 196a.)

6. **Intramuscular Lipomata.**—Many examples of fatty tumours occurring in the midst of muscles have been reported, and are of interest from the trouble they cause in diagnosis. They have been found in the deltoid, biceps, humeri, complexus, and rectus abdominis; and in the middle of a submucous myoma of the uterus.* The condition described as fatty tumour of the heart is simply overgrowth of the fat occupying the auriculo-ventricular groove.

Fig. 13.—Emaciated child crying and displaying sucking-cushions. (*After Ranke.*)

7. **Parosteal Lipomata.**—This term has been applied to fatty tumours arising from the periosteum of bone. They are usually congenital, and nearly always contain tracts of striated muscle fibre. Some of these tumours are clinical puzzles. Dr. F. Taylor † reported a case in which a fatty tumour grew from the anterior surface of the bodies of the cervical vertebræ; it projected the posterior wall of the pharynx, and simulated a post-pharyngeal abscess. The patient was a girl four years old. I have removed parosteal lipomata from the dorsal surface of the infraspinous fossa of the scapula, the body of the pubes, and the frontal bone immediately above the right superciliary ridge.

The appended table contains references to descriptions and accessible examples of parosteal lipomata.

* T. Smith, *Trans. Path. Soc.*, vol. xii. 148. See also Lebert, "Traité d'Anatomie Pathologique," plate xvi., fig. 11, t. i. 128.

† *Trans. Path. Soc.*, vol. xxviii. 216.

PAROSTEAL LIPOMATA.

Seat.	Reporter.	Reference.
Femur . . .	D'Arcy Power .	*Trans. Path. Soc.*, xxxix. 270.
	F. Page . .	*Lancet*, 1895, vol. ii. 150.
Tibia and Fibula .	Butlin . . .	*Trans. Path. Soc.*, xxviii. 221.
Ischium . .	T. Smith . .	*Trans. Path. Soc.*, xvii. 286.
Spine of Ilium .	Walsham . .	*Trans. Path. Soc.*, xxxi. 310.
Clavicle . .	Gould . . .	Museum, Middlesex Hospital.
Scapula . .	T. W. Nunn . .	Museum, Middlesex Hospital.
Neck of Radius .	T. Smith . .	*Trans. Path. Soc.*, xix. 344.
Coccyx . . .	T. Smith . .	*Trans. Path. Soc.*, xxi. 334.
Frontal . . .	Sidney Jones .	*Trans. Path. Soc.*, xxxii. 243.

Fig. 14.—Infant 9 months old with a large lipoma growing among the hamstring muscles. It was successfully removed. (*After Vickery.*)

8. **Lipomata on Nerves.**—Occasionally a fatty tumour arises from the sheath of a peripheral nerve; such are sometimes called *neuro-lipomata*. There is a specimen in the museum of the Middlesex Hospital which grew from the sheath of the median nerve as it escaped from the anterior annular ligament into the palm. It was situated entirely beneath the palmar fascia. Vickery recorded a case in which he succeeded in removing a lipoma weighing 12½ ounces from the thigh of an infant nine months old (Fig. 14). The tumour was adherent

to the sheath of the great sciatic nerve. Before operation it simulated a sarcoma.

9. **Meningeal Lipomata.**—Fatty tumours occur within the spinal dura mater, as well as externally to this membrane. When growing within the sheath they surround the cord. Gowers,* Recklinghausen,† and Obré‡ have recorded examples. In the cases described by the first two observers the tumours contained striped muscle tissue. The occurrence of an intradural lipoma is not surprising, as the loose connective tissue between the cord and dura mater contains fat.

Fatty tumours are not uncommon in the middle line of the back, especially in the lumbo-sacral region, overlying the sac of a spina bifida (Fig. 16).

A lipoma has been observed encapsuled between the layers of the dura mater of the sella turcica; it extended into the middle fossa of the skull on the left side. The patient, who was a woman forty-four years of age, suffered from periodical pain in the head, and eventually from ptosis (two years). The tumour was of the dimensions of a hen's egg.

Fig. 15.—Meningeal lipoma simulating a spina bifida in a child eight months old. (*After Témoin.*§)

Clinical Features.—Although lipomata occur more frequently than any other genus of connective tissue tumours,

* *Trans. Path. Soc.*, vol. xxvii. 19. † Virchow's *Arch.*, bd. cv. 243.
‡ *Trans. Path. Soc.*, vol. iii. 248.
§ *Arch. Provinciales de Chirurgie*, 1892, 179.

and may, in most instances, be diagnosed with absolute certainty, yet under some conditions they are very puzzling, and give rise to much difference of opinion. The subcutaneous species is rarely the source of doubtful diagnosis, unless situated in the palm of the hand, sole of the foot, or on the scalp. The intimate relation between the tumour and the overlying skin, the absence of definite boundaries,

Fig. 16.—Meningeal lipoma overlying the sac of a spina bifida. (*Museum, Royal College of Surgeons.*)

and its dough-like consistence are usually sufficiently trustworthy guides. When a lipoma is connected with the periosteum of a long bone it will sometimes simulate a sarcoma; when embedded in a muscle the most divergent opinions are often expressed in regard to the nature of the tumour, and a lipoma in the posterior triangle of the neck has been mistaken for an aneurysm of the subclavian artery.

Reference has already been made to those large lipomata which arise in the subperitoneal tissue and the way they mimic

the signs of ovarian tumours. Lipomata in the neighbourhood of hernial openings have also been confounded with herniæ.

Especial attention must be drawn to supposed fatty tumours situated in the middle line of the back: in most cases these are abnormal masses of fat overlying the sacs of spinæ bifidæ. Incautious surgeons, in operating upon such tumours, have unexpectedly opened the dura mater.

Treatment.—Solitary subcutaneous lipomata should, as a general rule, be removed. When very many tumours are present (ten or twenty) it is not customary to interfere with them, for when multiple they rarely attain uncomfortable or dangerous proportions. It occasionally happens with multiple (and also with solitary) lipomata, that one or other becomes irritated by some part of the dress, such as petticoat bands, braces, etc., or in some particular employment followed by the individual. Such tumours should invariably be removed.

The removal of a subcutaneous lipoma is one of the simplest proceedings in surgery, but the extirpation of a large subperitoneal fatty tumour is often attended with difficulty and grave danger.

CHAPTER III.

CHONDROMATA (CARTILAGE TUMOURS).

A **chondroma** (or enchondroma) is a tumour composed of hyaline cartilage. Its tissue resembles histologically the bluish translucent cartilage of an epiphysis. This genus contains three species—(1) chondroma, (2) ecchondrosis, (3) loose cartilages in joints.

1. **Chondromata.**—This species in its most typical conditions occurs in long bones, and, as a rule, in relation with the epiphysial cartilages; hence this tumour is most frequently observed in children and young adults. A single tumour may be present, but frequently many grow concurrently, especially on the long bones of the hand and feet (Fig. 17).

Chondromata are always encapsuled, and often form deep hollows in the bones from which they arise. They are painless, grow slowly, and are firm to the touch. Frequently they undergo mucoid degeneration, then the softened area gives rise to fluctuation. This serves to distinguish them from osteomata, with which they are apt to be confounded clinically. A chondroma frequently calcifies, and sometimes ossifies.

The frequency of chondromata in those who suffered from rickets in early life may be due, as Virchow thought probable, to the existence of untransformed pieces of cartilage acting the part of tumour germs. Such remnants of unossified cartilage are not difficult of demonstration in rickety bones (Fig. 19).

A chondroma is a very benign tumour, and even when it grows into the skull may require a long time to destroy life, as a very remarkable specimen in the museum of St. George's Hospital proves. It is a cartilage tumour which arose in the mesethmoid of a young woman, and then filled the nasal fossæ and occupied both orbits, and dislocated the globes outwards; it filled the antra, expanded the nasal bones, invaded the spheno-

maxillary fossæ, and formed a large mound in the anterior fossa of the skull, and almost reached the roof of the cranium. Its disruptive effects upon the facial bones were very extraordinary. In spite of this, the patient's health was but little disturbed; she had no loss of intellect, and, it is believed, no

Fig. 17.—Multiple chondromata. The lad was stunted from rickets

paralysis. The course of the disease from its origin till the patient died was about six years.

Although a chondroma invading the skull may require (as in the example just described) years to kill a patient, there is a situation in which in certain circumstances it will cause great distress and death—namely, in the pelvis. The effects which such tumours produce on the pelvic viscera are in some cases

* Similar cases have been carefully described by Steudel in Bruns' *Beiträge*, bd. viii. 503, and by Kast and Recklinghausen, in Virchow's *Arch.*, bd. cxviii. 1.

very remarkable. The specimen represented in section in Fig. 18 was obtained from a woman 21 years of age who, with a large chondroma in her pelvis, became pregnant. Delivery by natural means being impossible, hysterectomy was performed; but the patient died. Apart from obstructing labour, the tumour had pressed on the ureters and produced dilatation of both ureters and sacculation of the kidneys. This unfortunate

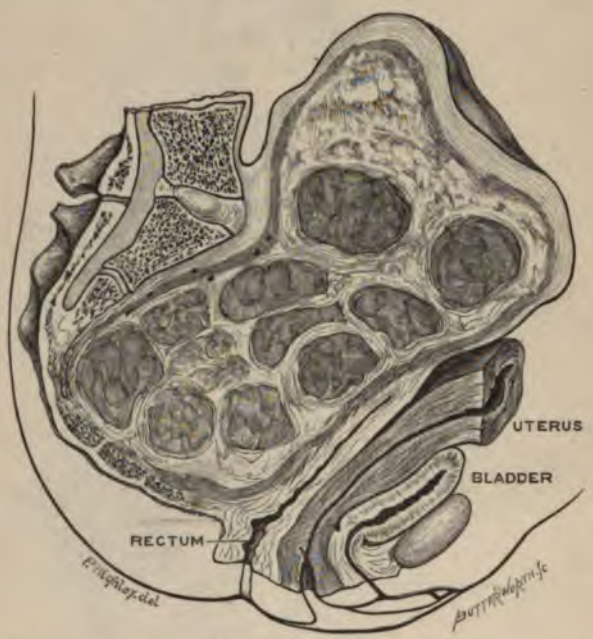

Fig. 18.—A pelvis occupied by a large partially ossified chondroma, shown in saggittal section: from a woman 21 years of age who died from hysterectomy performed for obstructed labour at term. (*Museum of University College, London.*)

woman was known to have a tumour in her pelvis seven years previously to her tragic death.

One of the greatest anomalies in connection with chondromata is their occurrence in the parotid, lacrimal, and submandibular glands. (See Chap. XII.)

2. **Ecchondroses.**—These may be defined as small local overgrowths of arttilage. They are best studied along the edges of articular cartilages, the laryngeal cartilages, and the triangular cartilage of the nose.

Ecchondroses are especially common in the knee-joint, and often in association with the condition termed rheumatoid arthritis. They are frequent in the joints of individuals who have passed the meridian of life, and they occur as small projecting prominences along the margins of the articular cartilage. Often the edge of the cartilage is produced into a raised prominent lip, the regularity of which is broken here and there by a sessile or pedunculated nodule.

When these nodules are examined many of them present on their outer surface a convex outline, but on the inner aspect —that looking towards the joint—they are concave, the concavity being produced by friction during the movements of the joint, or by pressure when the parts are at rest. Occasionally erosion of the ecchondrosis may extend so deeply that by some extra movement of the joint the pedicle is broken, and the detached nodule either falls as a loose body into the joint-cavity, or it may be retained in position by its attachments to the fibrous structures of the articulation.

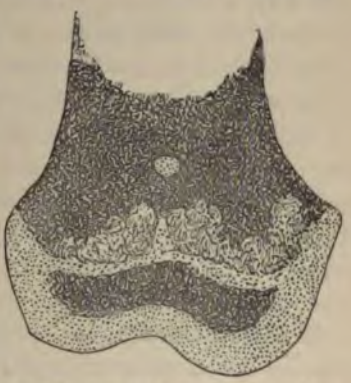

Fig. 19.—Condyles and epiphysial line of a rickety femur, with a cartilage island. (*Museum of the Middlesex Hospital.*)

Laryngeal ecchondroses are by no means common; they grow from the thyroid, cricoid, and occasionally the arytenoid cartilages, but very rarely from the semi-rings of the trachea. Paul Bruns * collected fourteen cases of laryngeal chondromata; of these, eight sprang from the cricoid, four from the thyroid, one from the arytenoid, and one from the epiglottis. Most of the ecchondroses of the cricoid cartilage sprang from the broad posterior plate. In many of the cases the inner and outer surfaces of the cricoid were involved, so that the tumour encroached upon the cavity of the larynx. Ecchondroses vary greatly in size; some are scarcely larger than a pea, others

* *Beiträge zu Klin.-Chir.*, bd. iii. 347

may be as big as walnuts. Morell Mackenzie * has described an example growing from the cricoid which attained the size of a bantam's egg; in this instance the tumour extended downwards in front of the trachea. Small ecchondroses growing from the inner surfaces of the laryngeal cartilages are more dangerous than the larger examples springing from their outer surfaces. Ecchondroses, when projecting into the larynx, are covered with its mucous membrane; they may be smooth or tuberculated, round or conical. In exceptional cases the overlying mucous membrane has been found ulcerated. Chondromata, when they project into the larynx, produce stridor, difficulty in breathing, and sometimes interfere with the movements of the vocal cords. When the tumours only involve the outer surfaces of the laryngeal cartilages, they do not as a rule produce any inconvenience, unless they are exceptionally large.

Small outgrowths from the triangular cartilage of the nose are by no means uncommon; they never attain a large size, and are always sessile. It is difficult to imagine that ecchondroses of the nasal cartilage could be a source of much inconvenience, but surgeons who study diseases of the nasal passages view them with disfavour.

3. **Loose Cartilages.**—Bodies of various kinds are found loose in the cavities of large joints, but those to be considered under the head of chondromata, in addition to detached ecchondroses, are pieces of hyaline cartilage found hanging in the joint by narrow pedicles, or occupying depressions in the bone from which they are occasionally dislodged. Structurally they are composed of hyaline cartilage, and assume various forms. Some appear as flat discs, others are ovoid; they may be perfectly smooth, or present an irregular worm-eaten appearance, and the majority are impregnated with calcareous particles. It is a remarkable fact that in many instances in which a loose cartilage has been found in one joint, a body identical in size and shape has been found in the corresponding joint of the opposite limb.† Loose cartilages may be single or

* *Trans. Path. Soc.*, vol. xxi. 58.

† Bowlby, *Trans. Path. Soc.*, vol. xxxix. 281; Clutton, *ibid.*, vol. xxxix. 284; *American Journal of Med. Sci.*, vol. i. 303; Weichselbaum, Virchow's *Arch.*, lvii. 127.

multiple: several hundred may exist in one joint, and vary in size from a rape-seed to an almond.

The origin of these cartilages is interesting. In large joints, such as the hip, knee, or shoulder, it is easy to demonstrate, in the recesses of the joint near the spot where the synovial membrane becomes continuous with the margin of the articular cartilage, villous-like processes of the synovial membrane projecting into the joint. Under certain conditions, especially that known as rheumatoid arthritis, these villi become greatly enlarged and increase in number until the whole synovial membrane may be so covered with them as to become quite velvety in appearance. Structurally, these synovial villi consist of a reduplication of the serous membrane, and contain tufts of capillaries. As they enlarge, some of them undergo chondrification, and this change may take place so extensively that a villous process is entirely converted into hyaline cartilage, which becomes the matrix for a deposit of lime salts. As these nodules of cartilage are merely sustained by narrow pedicles, the nodules may be detached either by their mere weight, by undue movement of the joint, or from axial rotation, and tumbling into the joint give rise to all the inconveniences characteristic of a loose body. Specimens occasionally come to hand in which cartilaginous bodies of this description may be found sessile among the fringes, or hanging on good pedicles, or with stalks so thin that they appear to be on the eve of detachment.

Occasionally these overgrown synovial villi, instead of chondrifying, are converted into oval bodies, which, on microscopic examination, present a central cavity surrounded by a laminated structureless substance. To the naked eye many of these oval bodies resemble cartilage, and it is only on microscopical examination that it is possible to distinguish between them; many are infiltrated with calcareous granules. These oval bodies are present, in some cases, in great number. On one occasion I counted 1,532 which were removed from the shoulder-joint. Bodies of this description occur not only in joints, but in compound ganglia and bursæ.

A good physiological type for the loose cartilaginous bodies which infest joints is furnished by the temporo-mandibular joint of the skate. A recess communicating with this articular

cavity usually contains a collection of smooth cartilage bodies, in contour and size like melon seeds.

Sometimes the synovial villi of a joint enlarge and attain the size of a gooseberry without calcifying or chondrifying. On one occasion I opened a knee-joint with the expectation of finding loose bodies; instead, the synovial membrane was beset with a number of pedunculated tumours of the size and shape shown in Fig. 20. Thirty-six of these bodies were suc-

Fig. 20.—Pedunculated bodies removed from the knee; the joint contained thirty-six such bodies.

cessfully removed. In structure they were similar to the synovial fringes normally found in the joint.

Villous synovial membranes are not infrequent in horses, and I have found the same condition in lions and in leopards, accompanied by loose calcified bodies. The articular ends of the bones displayed the changes known as osteo-arthritis.

Treatment.—The operative treatment of chondromata has been greatly simplified since surgeons have appreciated the fact that these tumours, when growing in relation with bones, are distinctly encapsuled. Now, when it is necessary to interfere with a chondroma, even in cases where several tumours are

present, it has become customary to incise the capsule and shell out the cartilage. In most instances this simple method is successful. Exceptionally, however, cases come under observation which demand more serious measures. When the cartilage tumours are very numerous on the bones of the hand, the fingers are so crippled and useless that amputation becomes necessary. Fortunately, such severe treatment is very rarely needed.

In the case of loose bodies in joints it is the usual practice, when the pieces of cartilage are in the habit of getting between the opposed surfaces of the joint, to open the synovial cavity, and remove the loose body or bodies. When this manœuvre is conducted with proper care it is highly successful. When the loose body is lodged in a sacculus, it is in a measure isolated from the general cavity of the joint, and does not call for interference. The smaller bodies, which, like mice, slip in and out of the recesses of a complex joint, are more likely to give trouble than those larger pieces of cartilage, sometimes as big as chestnuts, which the patients can grasp with their fingers and push in and out of the great cul-de-sac above the patella almost as readily as a marble may be manipulated under a tablecloth ·

CHAPTER IV.

OSTEOMATA (OSSEOUS TUMOURS).

An **osteoma** may be defined as an ossifying chondroma. The genus contains two species :—1, Compact osteoma ; 2, Cancellous osteoma.

1. **Compact Osteomata.**—These occur as sessile tumours on the parietal and frontal bones ; in the frontal sinus, roof of the

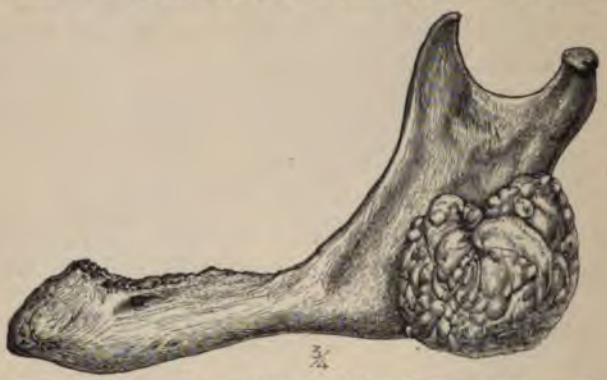

Fig. 21.—Osteoma of mandible. (*St. George's Hospital Museum.*)

orbit, walls of the external auditory meatus, mastoid process, and angle of the mandible (Fig. 21). They are composed of tissue as dense and as hard as ivory, and are frequently called "ivory exostoses." Those which arise in the frontal sinus and orbit are very remarkable tumours, and may attain large proportions (Figs. 22 and 23). Many large tumours removed from the maxilla and described as exostoses were large odontomes.

Osteomata of this species are occasionally found in the frontal sinuses of oxen as huge, irregular, lobulated masses, sometimes weighing as much as sixteen pounds.

Osteomata at the margins of the external auditory meatus have been especially studied because they are apt to obstruct the meatus and cause deafness ; when both meatuses are affected—and this is not rare—absolute deafness may result.

It is a curious fact that osteomata at the margins of the auditory meatus have been observed in many different races of men. Professor Sir William Turner* has drawn attention to observations of Seligmann, Welcker, Barnard Davis, and added some of his own, concerning the presence of such exostoses in certain deformed skulls described as Titicaca's, Huanaka's, and Aymara's. Also in skulls from the Marquesas Islands, Sandwich Islands, Chatham Island, and New Zealand.† It is not surprising that osteomata should arise from the walls of the external auditory meatus when we remember the number of centres by which the periotic cartilage is transformed into bone, and the various ossific elements that come into relation with each other at this meatus.

Fig. 22.—Osteoma of the left frontal sinus (anterior view).

Fig. 23.—Osteoma of the left frontal sinus (seen from below). (*Museum, Royal College of Surgeons.*)

2. **Cancellous Osteomata.**—These tumours in structure resemble the cancellous tissue of bone, and are soft in comparison with the preceding species. They usually possess a thick covering of hyaline cartilage, and

* *Journal of Anat. and Physiology*, vol. xiii. 200.

† Zoology of the "*Challenger* Expedition," pt. xxix. 117.

when growing at the distal end of the radius, or tibia, present a series of deep channels for the passage of tendons. Occasionally an osteoma is pedunculated; more frequently it has a broad base. Osteomata, whether sessile or stalked, usually grow slowly, but in the course of years they sometimes attain large proportions. They are innocent tumours, but occasionally imperil life by mechanically interfering with the function of vital organs. Reid * described a case in which an osteoma grew from the posterior surface of the odontoid process and projected into the neural canal to the extent of 8 mm. and compressed the spinal cord with fatal effect. Although in themselves painless, osteomata sometimes induce pain by pressing on nerve trunks in their vicinity.

Multiple cartilage-tipped osteomata are most frequent on the long bones of the arms and forearms, thighs and legs, and are often congenital, hereditary, and, so far as position is concerned, fairly symmetrical. Otto Weber † recorded a remarkable case of numerous symmetrical exostoses of the long bones of the upper and lower limbs, the ribs and scapula, in a man 25 years old. A chondro-sarcoma arose in the right hip bone and attained enormous proportions. It perforated the left external iliac vein, and pieces of the tumour, detached as emboli, lodged in the pulmonary artery.

Exostoses.—It has been customary to describe all kinds of tumours composed of bone, or bone-like tissue, under the name of exostoses. The term exostosis should be limited to irregular outgrowths of bone to which the term tumour is not in any sense applicable. The various bony outgrowths classed as exostoses fall into three groups:—

1. Ossification of tendons at their attachments.
2. The sub-ungual exostosis.
3. Calcification of inflammatory exudations.

1. *Exostoses formed by Ossification of Tendons at their Attachments.*—The long bones of a child at birth are smooth in outline and almost cylindrical in shape; the periosteum is relatively

* *Edin. Med. Journ.*, 1843, 194.

† Virchow's *Arch.*, bd. xxxv. 501. See also McGavin, *Trans. Path. Soc.* vol. liii. 356.

thick, and gives attachment to the muscles. On examining the long bones of an adult muscular man, their shafts are found to be irregular, and present many asperites, such as the linea aspera, gluteal ridge (sometimes called the third trochanter), oblique lines, and the like. These ridges and lines, in the majority of instances, are the ossified insertions of muscles, and occasionally they are so pronounced as to be appreciable through the soft structures, and are then described clinically as exostoses. The two most frequent examples of this form of exostosis are the adductor tubercle of the femur and the tubercle on the first rib at the insertion of the scalenus anticus. Probably the most common exostosis is that which occurs in the tendon of insertion of the adductor magnus (Fig. 24): it usually assumes the form of a broad ledge of bone; exceptionally it is stalked, and in rare cases surmounted by a bursa; the walls of such bursæ are now and then furnished with villi, and even loose bodies have been found in them (Orlow*). Care must be taken not to confound a supracondyloid process of the

Fig. 24.—Exostosis of the femur produced by ossification of the tendon of the adductor magnus. (*Museum, Royal College of Surgeons.*)

Fig. 25.—Symmetrical exostoses of the nasal processes of the maxillæ. (*After Hutchinson.*†)

* *Zeitschrift für Chir.*, bd. xxxi. 293.

† "Illustrations of Clin. Surgery," vol. i. 2.

humerus, and the occasional third trochanter of the femur, with exostoses.

Localised outgrowths are very common on the facial bones especially the nasal processes of the maxillæ, where they may be unilateral or bilateral (Fig. 25). The cause of these exostoses

Fig. 26.—So-called horned men of the Ivory Coast. (*Maclaud.*)

is obscure. Small irregular osseous prominences are fairly frequent along the alveolar borders of the maxillæ and mandible.

Exostoses of the maxillæ have been observed in natives of the West Coast of Africa, and in all probability have originated the myth of the existence of horned men in this region. Interesting particulars relating to this question are furnished by Macalister,* and by Lamprey,† of the Army Medical Staff. Strachan ‡ has observed them in the West Indian negro, and Dr. Maclaud,§ of the French navy, met with them frequently in the natives of certain villages on the Ivory Coast (Fig. 26).

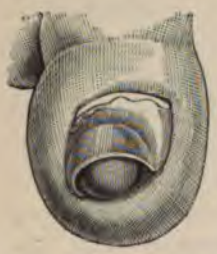

Fig. 27.—Big toe with a subungual exostosis.

2. *The Subungual Exostosis* is a troublesome outgrowth from the ungual phalanx of the big toe; it makes its way through the bed of the nail, and peers out between the nail and the skin at the tip of the toe, near the inner side (Fig. 27); its appearance is so characteristic

* *Proc. R. Irish Academy*, 2nd Series, vol. iii. 1883.
† *Brit. Med. Journal*, 1887, vol. ii. 1273.
‡ *Brit. Med. Journal*, 1894, vol. i. 189.
§ *Brit. Med. Journal*, 1895, vol. i. 1217.

that it only requires to be once seen to be appreciated readily. It is rarely bigger than a cherry-stone.

When the soft investing tissues are removed, the tumour appears as a low prominence of cancellous bone jutting from the dorsal surface of the terminal phalanx. These outgrowths are probably due to the pressure of ill-fitting boots, and should be ranked among inflammatory productions.

3. *Exostoses due to calcification of inflammatory exudations* scarcely require consideration in this work; there is reason to believe that some of the cases described as multiple exostoses

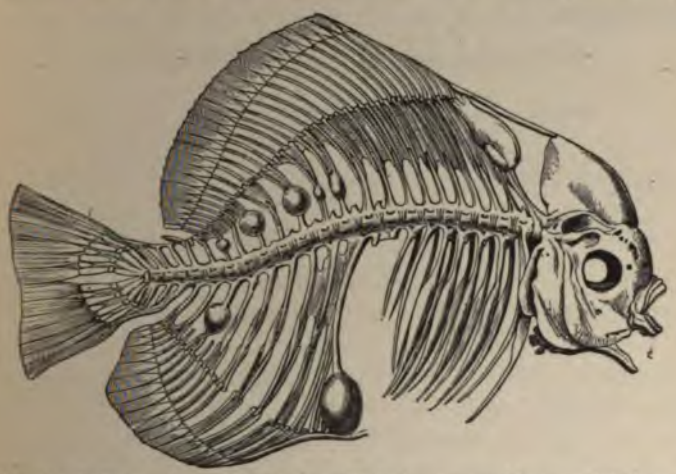

Fig. 28.—Bell's specimen of Chætodon with its tumours and large occipital crest.

were really examples of the strange and rare disease known as "myositis ossificans."

Bony tumours are of fairly frequent occurrence in all vertebrata. Paul Gervais * has published descriptions of many interesting specimens from fish. Perhaps the most striking example is furnished by the skeleton of the fish *Chætodon*, in which some of the bones are furnished with rounded bony tumours. The museum of the Royal College of Surgeons contains many loose bones with tumours, as well as the skeleton of the original fish sent by William Bell † to John Hunter (Fig. 28). Single bones of *Chætodon* are common in osteological

* *Journal de Zoologie*, 1875, vol. iv.
† *Phil. Trans.*, 1793.

collections; Cuvier explained this by stating that they are brought home by travellers who have eaten the fish. On section it will be found that the outline of the ray can be clearly defined running through the midst of the tumour. For fuller details relating to the *Chætodon*, consult the subjoined reference.*

Treatment.—When osseous tumours grow in situations where they do not involve important structures, the rule is not to interfere with them. When they press upon nerves and occupy accessible situations, and especially when pedunculated, they may be removed with chisel and mallet, or with stout forceps.

* *Trans. Path. Soc.*, vol. xxxix. 472.

CHAPTER V.

ODONTOMES, AND DENTAL CYSTS.

An **Odontome** is a tumour composed of dental tissues in varying proportions and different degrees of development, arising from teeth-germs, or teeth still in the process of growth.

The species of this genus are determined according to the part of the tooth-germ concerned in their formation.

1. Epithelial odontome: from the enamel-organ.
2. Follicular odontome
3. Fibrous odontome
4. Cementome
5. Compound follicular odontome

} From the tooth-follicle.

6. Radicular odontome: from the papilla.
7. Composite odontome: from the whole germ.

1. **Eipthelial Odontomes.**—These tumours occur, as a rule, in the mandible, but they have been observed in the maxilla. They have a fairly firm capsule, and in section display a congeries of cysts of various shapes and sizes; but the loculi rarely exceed 2 cm. in diameter. The cysts are separated by thin fibrous septa, sometimes ossified. The cavities contain mucoid fluid of a brownish colour. The growing portions of the tumour have a reddish tint not unlike a myeloid sarcoma (Fig. 29).

Histologically, an epithelial odontome consists of branching and anastomosing columns of epithelium, portions of which form alveoli (Fig. 30). The cells occupying the alveoli vary; the outer layer may be columnar, whilst the central cells degenerate and give rise to tissue resembling the stratum intermedium of an enamel-organ. Odontomes of this species are most frequent about the twentieth year.

The tumours have been investigated by Eve (who gave them the name of multilocular cystic epithelial tumours) and

by Falkson and Bryck. They probably arise from persistent portions of the epithelium of enamel-organs.

A careful re-examination of a few of the specimens described as multilocular cystic epithelial tumours of the jaws, and a study of the descriptions of others, especially those occurring

Fig. 29.—Epithelial odontome. (*Nat. size.*)

in individuals past middle life, has satisfied me that many of them were endotheliomata (see p. 166). Some of the most typical examples of endothelioma arise in the gums.

2. **Follicular Odontomes.**—This species comprises those swellings often called dentigerous cysts, a term which has

Fig. 30.—Microscopical characters of an epithelial odontome.

come to be used very loosely. Follicular odontomes arise commonly in connection with teeth of the permanent set, and especially with the molars. Sometimes these tumours attain large dimensions, and produce great deformity, especially when they arise in the upper jaws and happen to be bilateral.

The tumour consists of a wall of varying thickness, which represents an expanded tooth-follicle; in some cases it is thin and crepitant, in others it may be 1 cm. thick. The cavity of the cyst usually contains viscid fluid and the crown or the root of an imperfectly developed tooth; occasionally the tooth is loose in the follicle, sometimes inverted, and often its root is truncated (Fig. 31); exceptionally the tooth is absent, or represented by an ill-shaped denticle. The walls of the cyst always contain calcific or osseous matter; the amount varies considerably. Follicular odontomes rarely suppurate.

These tumours are not unknown in other mammals; I have seen them in sheep, pigs, and porcupines. In sheep they are common, and generally affect the incisors, and are thus

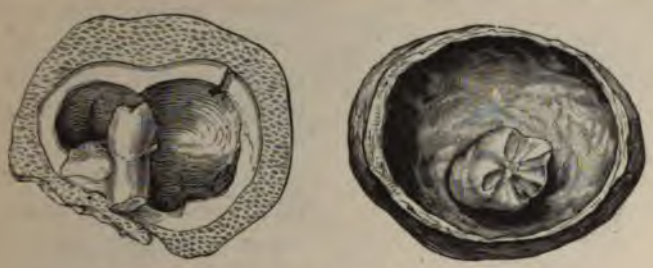

Fig. 31.—Follicular odontomes from the mandible.

limited to the mandible; as a rule they are bilateral. Tomes has suggested that this species of odontome is probably due to the excessive formation around a retained tooth, between it and the wall of the follicle, of a fluid which is normally present after the complete development of a tooth.

3. **Fibrous Odontomes.**—In a developing tooth, a portion of the connective tissue in which it is embedded is found to be denser and more vascular than the rest; it also presents a fibrillar arrangement. This condensed tissue is known as the tooth-sac, and when fully developed presents an outer firm wall and an inner looser layer of tissue. At the root of the tooth the follicle-wall blends with the dentine papilla, and is indistinguishable from it. Before the tooth cuts the gum it is completely enclosed within this capsule. Under certain conditions this capsule becomes greatly increased in thickness, and so thoroughly encysts the tooth that it is never erupted

(Fig. 32). Such thickened capsules are mistaken for fibrous tumours, especially if the tooth be small and ill-developed. Under the microscope they present a laminated appearance, with strata of calcareous matter. To these, the term fibrous odontomes may be applied. They are more common in ruminants than in other mammals, and are especially frequent in goats. As a rule they are multiple, four being by no means an unusual number. They occur in marsupials, bears, and lions, as well as in man.

There is good reason for the belief that rickets is responsible for some of these thickened capsules. Certainly, in some of the most typical examples which have been observed in human beings, the subjects were rickety children; the bilateral tumours, in some cases, being erroneously described as myeloid sarcomata.

Fig. 32.—Fibrous odontome from a goat. (*Nat. size.*)

4. **Cementomes.**—When the capsule of a tooth becomes enlarged, as in the specimens just considered, and these thick capsules ossify, the tooth will become embedded in a mass of cementum. To this form of odontome the name cementoma may be applied. Odontomes of this character occur most frequently in horses, and sometimes attain a large size. Broca * has described and figured specimens from horses. Tomes † has described one which weighed ten ounces, and I have given an account of another which weighed twenty-five ounces (Fig. 33). When divided, three teeth could be made out, embedded in cementum. The periphery of the tumour was cautiously decalcified in hydrochloric acid, and sections were prepared for the microscope. The structure of the decalcified mass was very instructive, for the periphery of the tumour exhibited the laminated disposition seen in fibrous odontomes.

* "Traité des Tumeurs," 1869, t. ii. 350.

† *Trans. Odont. Soc. Great Britain*, 1872, 103.

The largest cementome from a horse known to me is preserved in the museum of the Royal Veterinary College, London; it weighs seventy ounces, and though excessively dense, is nevertheless very vascular. Its chief structural peculiarity is the presence, in enormous numbers, of large, richly branched lacunæ.*

5. **Compound Follicular Odontomes.**—If the thickened capsule ossifies sporadically instead of uniformly a curious condition is brought about, for the tumour will then contain a number of small fragments of cementum, or dentine, or even ill-shaped teeth (denticles) composed of three dental elements — cementum, dentine, and enamel. The number of teeth or denticles in such tumours varies greatly, and may reach a total of four hundred.

Fig. 33.—Cementome from a horse. (*Half nat. size.*) (*Museum of the Royal College of Surgeons.*)

Tumours of this character have been described in the human subject by several observers. Amongst the most noteworthy are the following:—

Tellander, of Stockholm, met with a case in a woman aged twenty-seven years. The right upper first molar, bicuspids, and canine of the permanent set had not erupted, but the spot where these teeth should have been was occupied by a hard, painless enlargement, which the patient had noticed since the age of twelve years. Subsequently this swelling was found to contain minute teeth. There were nine single teeth, each one perfect in itself, having a conical root with a conical crown—tipped with enamel; also six masses built up of adherent single teeth. The denticles presented the usual characters of

* *Trans. Odont. Soc. Great Britain*, 1891, 215.

supernumerary teeth. (Fig. 34.) About a year afterwards a tooth was found making its appearance in the spot from which this host of teeth was removed.

A similar case has been recorded by Sir John Tomes, the details of which were communicated to him by Mr. Mathias,* on medical service in India. A Hindoo, aged twenty, had a large tumour in his mouth containing a number of ill-formed

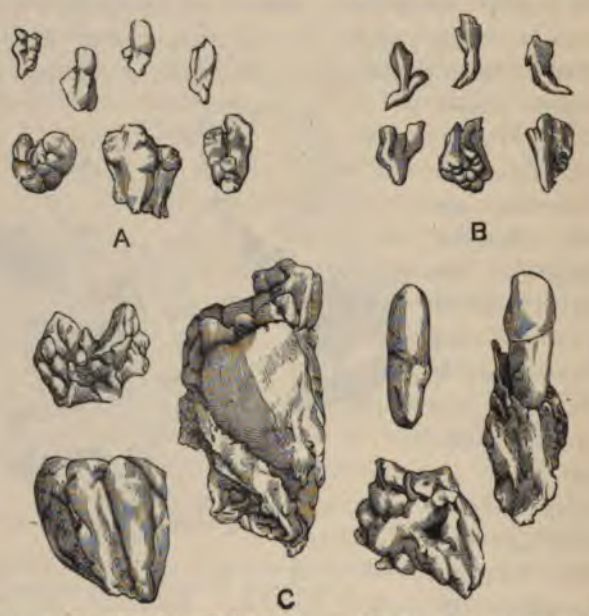

Fig. 34.—A, Denticles from Tellander's case. Total number, twenty-eight.
B, ,, from Windle's case. Total number, forty.
C, ,, from Mathias's case. Total number, fifteen.

teeth; fifteen masses of supernumerary teeth and bone were removed from it. The soft parts rapidly healed, the deformity disappeared, and subsequently the only peculiarity noticeable was the absence of the central and lateral incisors. The canines occupied their usual position.

A third example of this remarkable condition has been recorded by Professor Windle and Mr. Humphreys.† The tumour was found in the mouth of a boy aged ten years; neither the deciduous nor the permanent right lateral incisor or

* *Trans. Odont. Soc. Great Britain*, vol. iii. 365.

† *Journal of Anat. and Physiology*, vol. xxi. 667.

canine had erupted. The space thus unoccupied was filled by a tumour with dense unyielding walls. From this tumour forty small denticles of curious and irregular forms were removed.

Hildebrand * and De Roaldes † have observed similar cases. Logan ‡ reported an example from the maxilla of a horse containing four hundred denticles; and in a Himalayan goat the writer found one of these singular tumours in each upper jaw containing nearly three hundred denticles. This specimen is preserved in the museum of the Royal College of Surgeons.

6. **Radicular Odontomes.**—This term is applied to odontomes which arise after the crown of the tooth has been completed, and while the roots are in the process of formation. As the crown of the tooth, when once formed, is unalterable, it naturally follows that should the root develop an odontome, enamel cannot enter into its composition; the tumour would consist of dentine and cementum in varying proportions, these two tissues being the result of the activity of the papilla.

As a typical radicular odontome, we may choose the well-known specimen described by Salter, and represented in Fig. 35. In this specimen the tumour is clearly connected with the roots. The outer layer of the odontome is composed of cementum; within this is a layer of dentine, deficient in the lower part of the tumour, and inside this is a nucleus of calcified pulp.

Mr. Hare, of Limerick, removed from the upper jaw of a man aged forty-one the odontome sketched in Fig. 36. This specimen was originally described by Sir John Tomes, § but it was examined and redescribed by Mr. Charles Tomes. ‖ The mass is invested by cementum; inside this casing is a shell of dentine; the tubules radiate outwards and are disposed with some regularity: this dentine was deficient at the distal end of the tumour; its interior was filled with an ill-defined osseous material.

Radicular odontomes are rare in man, but frequent in

* *Zeitsch. für Chir.*, bd. xxxi. 282.
† *New York Med. Jour.*, 1894, 612.
‡ *Journal of Comp. Med. and Surg.*, New York, 1887.
§ *Trans. Odont. Soc. Great Britain*, 1863.
‖ *Trans. Odont. Soc. Great Britain*, 1872.

other mammals, and are often multiple. Rodents are especially liable to them, due in a large measure to the fact that their teeth grow from persistent pulps. A young marmot had four

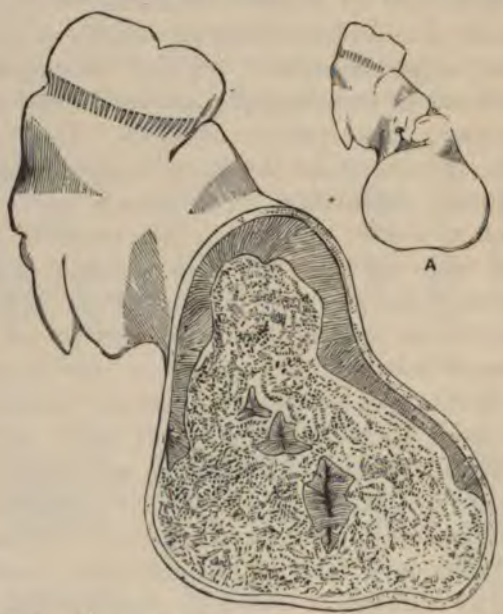

Fig. 35.—Radicular odontome from human subject. A, represents the natural size of the specimen. (*After Salter.*)

odontomes, one attached to each incisor in the upper and lower jaw. One of them is sketched *in situ* (Fig. 37) and of natural size. It consisted mainly of cementum. Similar tumours have come under my observation in the Canadian porcupine, the agouti, and the boar (Fig. 38).

Fig. 36.—Radicular odontome. (*Nat. size.*) (*After Sir John Tomes.*)

Radicular odontomes have been obtained from elephants, arising in connection with the roots of the tusks; indeed, the largest odontomes on record were obtained from elephants. The museum of the Royal College of Surgeons contains several excellent specimens Structurally they consist almost entirely of osteo-dentine.

It is very probable that many, perhaps most, of these thickened roots of tusks in boars and elephants and the incisors of rodents are due to inflammatory changes in the pulps.

7. **Composite Odontomes.**—This is a convenient term to apply to those hard tooth tumours which bear little or no resemblance in shape to teeth, but occur in the jaws, and consist of a disordered conglomeration of enamel, dentine, and cementum. Such odontomes may be considered as arising from an abnormal growth of all the elements of a tooth-germ—enamel-organ, papilla, and follicle.

Fig. 37.—Left lower jaw of a young marmot with a large radicular odontome connected with the incisor. (*Nat. size.*)

Not only is this class of odontomes composite in that the tumours comprised in it originate from all the elements of a tooth-germ, but they are composite in another sense. In the

Fig. 38.—Radicular odontome connected with the mandibular canine of a boar.

majority of cases the tumours are composed of two or more tooth-germs indiscriminately fused. But they differ from the cementomata containing two or more teeth in the fact that the various parts of the teeth composing the mass are indistinguishably mixed, whereas the individual teeth implicated in a cementoma can be clearly defined.

Forget's classical case belongs to this species. The patient was twenty years old, but the disease had been noticed since the age of five years. Behind the first bicuspid no teeth were seen, but the jaw as far back as the ramus was the seat of a smooth, unyielding tumour. The parts represented in the figure were removed during life (Fig. 39). On microscopical examination the tumour consisted mainly of dentine, the surface of which was in places covered with enamel dipping into the crevices, at the bottom of which cementum was found.

Fig. 39.—Composite odontome. (*Nat. size.*) (*After Forget.*)

It was long believed that composite odontomes occurred only in the mandible; now we know more about them it is clear not only that they arise as frequently in the maxillæ, but that they attain a far larger size in the upper than in the lower jaw. This is shown in the subjoined tables :—

TABLE I.—ODONTOMES FROM THE LOWER JAW.

No.	Recorder.	Age of Patient.	Weight of Tumour.	Reference.
1	Forget ..	20	See Fig. 39.	"Des Anomalies Dentaires," Paris, 1859.
2	Heath ..	18	315 grains.	*Trans. Clin. Soc.*, vol. xv. 10.
3	Parker ..	19	136 grains.	*Trans. Path. Soc.*, vol. xxxii. 240.
4	Annandale	17	300 grains.	*Ed. Med. and Surg. Jour.*, 1873, 599.
5	Windle ..	25	40 grains.	*Journal of Anatomy and Physiology*, vol. xxi. 665.
6	Barrett ..	23	102 grains.	*Trans. Odont. Society Gt. Britain*, vol. xxx. 21.
7	Cotterell ..	9	180 grains.	*Ibid.*, vol. xxxiii. 31.
8	Dolomore ..	22	375 grains.	*Journal Brit. Dental Ass.*, Sept., 1902.

TABLE II.—ODONTOMES FROM THE UPPER JAW.

No.	RECORDER.	AGE OF PATIENT.	WEIGHT OF TUMOUR.	REFERENCE.
1	Tomes ..	41	See Fig. 36.	*Trans. Odont. Soc. Gt. Britain*, vol. iii. 335.
2	Michon ..	19	1080 grains.	*Mem. de la Soc. de la Chir. Paris*, 1850.
3	Duka	26	1060 grains.	*Trans. Path. Soc.*, vol. xvii. 256.
4	Hilton ..	36	15 ounces.	*Guy's Hospital Rep.*, vol. i. 493.
5	Brock ..	19	See Fig. 41, A.	*See* page 61.
6	Jordan Lloyd	21	279 grains.	*Lancet*, 1888, vol. i. 64.
7	Andrews ..	17	500 grains.	*Trans. Odont. Soc. Gt. Brit.*, vol. xxvii. 42.

It is curious that many large tumours removed from the antrum and described as exostoses were as a matter of fact odontomes. Thus M. Michon * removed from the antrum of a Frenchman, aged nineteen years, at the Hôpital de la Pitié (without an anæsthetic), an odontome weighing 1,080 grains. The operation, which may be described as a "surgical struggle," lasted upwards of an hour and a quarter. The tumour is described as an exostosis, but fortunately Michon's account is accompanied by some excellent figures which show clearly enough that the tumour is an odontome. The cut surface exhibited a laminated disposition. Microscopically it was composed of tissue presenting many parallel tubules having the appearance of exaggerated dentinal tubes.

A tumour almost parallel with this has been described by Dr. T. Duka,† by whom it was removed from a Mahomedan woman, aged twenty-six years, at Monghyr, Bengal. The woman had for six years suffered from a muco-purulent discharge from the right nostril, and was now anxious for relief. The case was regarded as one of necrosis, but after a "surgical struggle" lasting nearly an hour (without chloroform), the tumour (Fig. 40) was withdrawn from the antrum. It had no connection with the surrounding tissues. The tumour, which was regarded as an exostosis, was submitted to a committee

* *Mem. de la Soc. de la Chir. Paris*, 1850.

† *Trans. Path. Soc.*, vol. xvii. 256.

of the Pathological Society. In its report this committee states that the bone tissue differs in character from that ordinarily seen in exostoses. An examination of the tumour, which is preserved in St. George's Hospital museum, and an inspection of the figures illustrating the report mentioned, show clearly enough that it is a composite odontome. Dr. Duka, in his account of the case, states that Dr. Allen Webb was of opinion that the nucleus was formed by a tooth-follicle escaping into the antrum of Highmore. This was a guess, but one not far short of the truth.

The largest odontome known to have grown in the human

Fig. 40.—Composite odontome from the upper jaw. (*Nat. size.*)

antrum, and which for many years has been regarded as an exostosis, is preserved in the museum of Guy's Hospital (Fig. 42). It has an extraordinary clinical history, which was recorded by Hilton.*

The patient, a man aged thirty-six years, had a large osseous tumour occupying the antrum. The pressure of this tumour had caused the front wall of the antrum, with the integument and soft tissues covering it, to slough. The trouble was first noticed thirteen years before; as the cheek enlarged the eyeball became displaced and finally burst. For a long time the surface of the tumour was exposed, the suppuration being copious, and occasionally pieces of bone irregular in shape came away;

* *Guy's Hospital Reports*, 1836, vol. i. 493.

at last, to the man's astonishment, the bony mass dropped out, leaving an enormous hole in his face. The general appearance

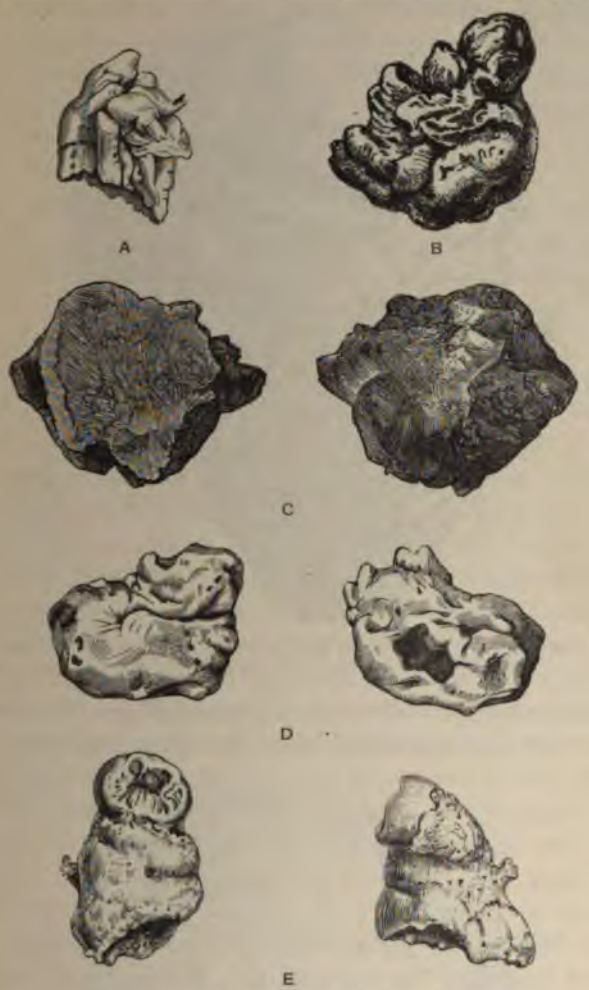

Fig. 41.—Group of odontomes.

A. Upper Jaw (No. 5, Table II., on p. 57). B. From the lower jaw (No. 3, Table I. on p. 56). C. From the upper jaw (No. 6, Table II.). D. Radicular odontome from lower jaw (No. 5, Table I.). E. Radicular odontome. All are of the natural size, except A, which is slightly enlarged.

of this tumour may be inferred from the accompanying sketch. It weighed nearly fifteen ounces, and measured 27.5 cm. (11″) in its greatest circumference. I have had an opportunity of

investigating this tumour; it is remarkably hard, presents on section an ivory-like surface, and, on close scrutiny, a number

Fig. 42.—Large odontome which was spontaneously shed from the antrum; weight, nearly fifteen ounces. (*Museum, Guy's Hospital.*)

of closely-arranged concentric laminæ (Fig. 43). Sections ground thin and examined under the microscope show large

Fig. 43.—Section of tumour, Fig. 42, showing concentric lamination.

numbers of lacunæ and canaliculi arranged in a very regular manner. I could not detect dentine, and it is impossible,

without mutilating the specimen, to be sure that no teeth are embedded in it.

As this tumour had no bony connections, occupied the antrum, and in the structure of its peripheral parts is so closely identical with odontomes which occur in horses, there need be no hesitation in believing that this particular tumour originated in one or more enlarged tooth-follicles, and is in fact an odontome.

The odontome shown in Fig. 41 A was removed by Mr. S. Brock from a lad aged nineteen years; it was situated in front of the right upper bicuspid, displacing the lateral incisor and canine so as to occupy their position in the dental arch. As will be seen in the figure, it appears to consist merely of a crown and neck, but the crown bristles with cusps; as many as nine distinct enamel-covered eminences can be detected. Odontomes resemble teeth in this way: for a time during their development they remain hidden below the mucous membrane, and give little or no evidence of their existence. To this succeeds an eruptive stage, which is usually between the twentieth and twenty-fifth years, and the suppuration, with the constitutional disturbance dependent thereon, draws attention to them. This remarkable odontome had not only cut the gum, but had taken a position in the dental series, and is further interesting in that it consists of a conglomeration of denticles, for I have urged that those remarkable cases in which denticles have from time to time been erupted from a tumour connected with the jaw should be classed as odontomes. It is easy to imagine that if the cusps of this odontome had remained distinct, and if each had been separately erupted, they would have been called supernumerary teeth. Indeed, many of the cusps could be easily detached from the main mass. Thus this strange specimen serves to bridge the gap between compound follicular and composite odontomes.

Treatment.—A study of the literature relating to odontomes is very instructive, for it serves to show that patients have in many instances been submitted to operations needlessly severe and dangerous. Odontomes are rarely diagnosed before operation. In some cases the trouble has been regarded as due to necrosed bone, or unerupted teeth; in a few the tumours

were regarded as exostoses, whilst several fibrous odontomes have been described as myeloid sarcomata.

In the case of a tumour of the jaw, the nature of which is doubtful, particularly in a young adult, it is incumbent on the surgeon to satisfy himself, before proceeding to excise a portion of the mandible or maxilla, that the tumour is not an odontome, for this kind of tumour only requires enucleation. In the case of a follicular odontome it is usually sufficient to excise a portion of its wall, scrape out the cavity, remove the tooth if one be present, stuff the sac, and allow it to close by the process of granulation. Occasionally the sac as well as the tooth will enucleate quite easily.

Fig. 44. — Dental cysts at the roots of a dead lower molar.

Dental Cysts. — It occasionally happens in extracting dead permanent teeth that a small fibrous bag is found at the apex of the root, often no larger than an apple pip, though sometimes it may be as big as a bantam's egg, filled with fluid, and often containing crystals of cholesterine (Fig. 44). These sacs, or dental cysts, occur in connection with the dead roots of mandibular and maxillary teeth; they sometimes attain a large size in the upper jaw when they invade the antrum, and some of these cysts are of sufficient size to simulate an abscess of that cavity.

The constant association of these cysts with the dead roots of permanent teeth has led many observers to regard them as pus sacs with thick fibrous walls. Mr. J. G. Turner has carefully investigated their structure, and demonstrated the existence of an epithelial lining in many of these cysts. He believes that these cysts arise in the "rests" detected by Malassez and known as paradental epithelial remnants. They are derived from a prolongation of the enamel organ which precedes and determines the formation and shape of the dentine and the root of the tooth.

The restriction of these cysts to the roots of the permanent teeth is explained by the fact that the roots of temporary teeth as well as their alveoli are absorbed.

The majority of dental cysts are met with accidentally in

extracting dead permanent teeth or their roots. Large specimens, however, resemble in their clinical signs tumours of the jaws or antrum (Fig. 45). When a painless smooth tumour of

Fig. 45.—Large cyst connected with the mandible: it is probably an unusually large dental cyst. (*Museum, St. George's Hospital.*)

the jaw is associated with a carious tooth, especially of long standing, a dental cyst should be borne in mind.

Treatment.—The roots must be extracted and the cyst wall very thoroughly scraped away with a sharp scoop, and the cavity stuffed with sterilised gauze and allowed to granulate.

CHAPTER VI.

MYELOMATA.

A **myeloma** is composed of tissue identical with the red marrow of young bone.

The genus contains a single species—myeloma. These

Fig. 46.—Microscopic characters of a myeloma from the acromial end of the clavicle.

tumours arise only in the cancellous tissue of bone. When fresh the cut surface of the tumour is deep red, and looks not unlike a piece of fresh liver, and is very vascular. Microscopically this tissue abounds in large multinuclear cells (giant cells, myeloplaques) embedded among round and spindle cells. The giant cells are so numerous as to constitute the greater proportion of the tumour (Fig. 46).

The distribution of myelomata is that of red marrow, but they exhibit a striking preference for certain bones. The tibia is the favourite bone in the lower, and the radius in the upper, limb; whilst so far as the bones of the head are concerned,

myelomata seem peculiar to the jaws; and they are apparently unknown in the vertebræ.

The **tibia** is the seat of a myeloma five times more frequently than any other long bone, and it is five times commoner in its upper than in its lower end (Figs. 47, 48).

In the **radius**, the lower end is the favourite site, but myelomata of the upper end are not unknown (Figs. 49, 50).

The same reversal applies to the fibula and the ulna, myelomata preferring the head of the fibula, but the lower end of the ulna; but in both situations they are very rare.

In the **clavicle** several examples have been recorded in the sternal end, and I have observed one at the acromial end, an excessively rare situation (Fig. 51).

In the **humerus** the upper end of the bone is the usual site, but in the **femur** it is the condyloid end. A myeloma is very rare in the **patella** (Fig. 52).

Fig. 47.—Coronal section of the upper end of the tibia showing a myeloma in the outer tuberosity. (From a woman of 25 years.)

In the **mandible** myelomata affect the body of the bone, but in the **maxilla** they prefer the alveolar border, and may sometimes remain in the early stage restricted to the premaxilla.

The clinical features are, as a rule, sufficiently characteristic to ensure accurate diagnosis. The patients are young, rarely above twenty-five years of age; the tumour grows slowly, expands the bone, and thins the osseous capsule while expanding

it until the bony shell is so thin that it crepitates when pressed by the finger. Here and there the myelomatous tissue perforates the capsule and markedly pulsates synchronously with the cardiac systole.

Myelomata do not infect lymph glands, nor disseminate. When the patient comes under observation before the tumour has perforated its capsule, it may be thoroughly extirpated

Fig. 48.—Coronal section of the lower ends of the tibia and fibula, with the astragalus; a myeloma occupies the lower end of the tibia. (From a woman aged 23 years.)

Fig. 49.—A myeloma of the upper end of the radius; from a man of 28 years. (*Museum, St. Thomas's Hospital.*)

without fear of recurrence. The manner of thorough extirpation varies with the situation of the tumour.

In the upper limb the lower extremities of the radius and ulna have been excised for myeloma, leaving an extremely useful hand. It is an important fact to remember that the lower third of the ulna may be excised alone, but when the radius is the affected bone it is an advantage to remove the corresponding section of the ulna. The upper third of the humerus, the inner half, and the outer half of the clavicle have been resected for myeloma with excellent results. In the case

of the jaws partial excision has been performed for myeloma with good consequences, but when the patient allows one of these tumours in the maxilla to fungate before seeking surgical aid, the marrow tissue will so invade the surrounding soft parts that complete extirpation is a chance event and recurrence is probable.

In the lower limb the best method of dealing with myeloma is not so certain. For those in the lower end of the femur, amputation is necessary. This method has also been employed for the patella by Robert Jones. Excision has been success-

Fig. 50.—Myeloma of the lower end of the radius. (*Museum, St. Thomas's Hospital.*)

fully employed for myelomata in the head of the tibia (Morton), and in this situation a milder method—enucleation, first suggested and practised by Paget—has given excellent results.*

A close study of myelomata indicates that they differ histologically, pathologically, and clinically from sarcomata, with which they have hitherto been grouped.

They are rare tumours, and a careful perusal of periodical literature and hospital reports makes me think that at each of the eleven large general hospitals in London one myeloma a year is above the average.

The subjoined table represents the good consequences which attend the surgical treatment of this genus of tumours.

It is fair to assume that the remarkable case in which Mott

* Butlin, and Colby, *St. Barth. Hosp. Rep.*, vol. xxxi. 35; Hinds, *Brit. Med. Journal*, 1898, vol. i. 555.

in 1827 excised the sternal two-thirds of the clavicle for what he called, in the terms of his day, "an osteo-sarcoma," in a

Fig. 51.—Myeloma of the acromial end of the clavicle; from a woman of 26 years. (*Museum, Royal College of Surgeons.*)

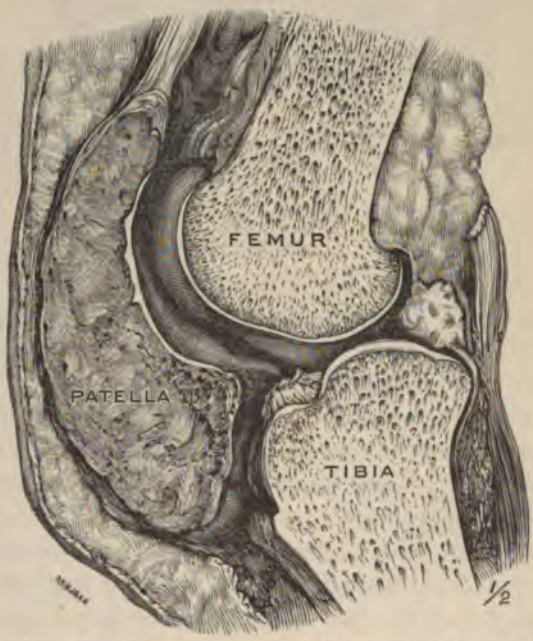

Fig. 52.—Myeloma of the patella; from a girl of 20 years. (*Museum, Royal College of Surgeons.*)

lad eighteen years of age, was in all probability a myeloma. The boy survived the operation fifty years.*

Reporter	Age of Patient and Bone Affected.	Nature of Operation.	Result.	Reference.
Morris	28. Lower end of radius.	Resection of lower ends of radius and ulna	Free from recurrence 16 years later	*Trans. Clin. Soc.*, vols. x. 138; xiii. 155; xxii. 367.
Lucas	29. Lower end of ulna	Resection of lower end of ulna	Free from recurrence 10 years later	*Trans. Clin. Soc.*, vols. x. 135; xxii. 366.
Bland-Sutton	26. Acromial end of clavicle	Resection of outer half of clavicle	No recurrence 10 years later	*Trans. Clin. Soc.*, vol. xxiv. 12. See Fig. 51.
Clutton	28. Upper end of radius	Resection of upper fourth of radius	Died of albuminuria 1½ years later No recurrence.	*Trans. Clin. Soc.*, vol. xxvii. 86. See Fig. 49.
Clutton	35. Head of tibia	Amputation	No recurrence 10 years later	Treves's "Surgery," vol. i. 915.
Bland-Sutton	Premaxilla	Excision of the premaxilla	No recurrence 3 years later	Unpublished.
Bland-Sutton	23. Lower end of tibia	Amputation through middle of the leg	No recurrence 4 years later	Unpublished. See Fig. 48.
Jones	20. Patella	Amputation	No recurrence 3 years later	*Trans. Path. Soc.*, vol. xlvi. 143 See Fig. 52.

* Porcher, *Amer. Jour. of Med. Science*, vol. lxxxv. 146.

CHAPTER VII.

SARCOMATA: THEIR HISTOLOGIC CHARACTERS.

THE term **sarcoma** is applied to any connective tissue tumour which exhibits malignant characters. As a matter of fact, almost any kind of connective tissue—fat, bone, cartilage, and even striated muscle tissue—occurs in sarcomata, but, as a rule, the greater part of the tumour consists of immature connective tissue in which cells preponderate over the intracellular tissue. The species are determined according to the prevailing type of cell: thus we have round-celled and spindle-celled sarcomata; some contain pigment, and are known as melano-sarcomata. A peculiar species arising in pigmented moles is known as alveolar sarcoma. Of each there are one or more varieties, which have received qualifying names, such a lympho-sarcomata, myo-sarcomata, chondro-sarcomata, and the like.

The sarcoma constitute a very heterogeneous genus, and will continue so until the cause of malignant connective tissue tumours is detected.

1. **Round-celled Sarcomata.**—This species is of very simple construction, and consists of round cells with very little intercellular substance. Each cell contains a large round vesicular nucleus, and a small proportion of protoplasm; the nuclei are always conspicuous objects in stained sections. Blood-vessels are abundant, often appearing as mere channels between the cells. Lymphatics are absent. Round-celled sarcomata grow very rapidly, infiltrate surrounding tissues, recur quickly after removal, and give rise to secondary deposits, especially in the lungs.

There is a variety, known as the large round-celled sarcoma, in which the cells are of unequal size; some of them contain two or more nuclei; a few are multinuclear, and resemble myeloid cells.

The round-celled sarcoma is the most generalised tumour that affects the human body; it may occur in any tissue,

osseous, muscular, nervous, thymic, ovarian, or testicular, and even in the delicate sustentacular framework of the retina. It attacks the body at all periods of life, from the fœtus *in utero* and the child just born, up to the extreme limits of age, and arises in vestigial organs, *e.g.* the pineal body, as well as in those which are in the full exercise of their functions, namely, the kidney or the parotid gland.

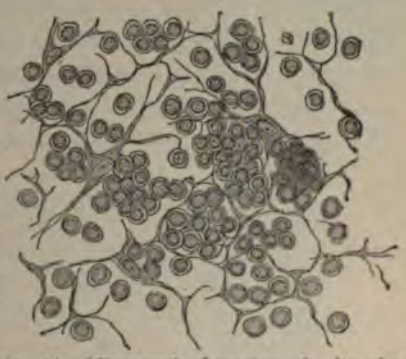

Fig. 53.—Microscopic characters of a lympho-sarcoma from the mediastinum.

2. **Lympho - sarcomata** consist of cells, identical with those of the round-celled species, but the cells are contained in delicate meshes: the tissue resembles that of lymph glands (Fig. 53), hence the origin of the term lympho-sarcoma. These tumours must not be confounded with simple (irritative) enlargement of lymph glands, nor with the general overgrowth of lymphadenoid tissue associated with leukæmia or lymphadenoma (Hodgkin's disease). The lympho-sarcomata exhibit a very characteristic structure, occur as a rule in very definite situations, and have somewhat special clinical features. These tumours occur in the superior mediastinum, in the subpleural and subperitoneal connective tissue, at the base of the tongue, in the larynx, in the tonsil, and in the testis. Fortunately, sarcomata of this species are rare, for they are excessively malignant.

Fig. 54.—Microscopic characters of a small spindle-celled sarcoma from a metacarpal bone.

3. **Spindle-celled Sarcomata.**—The cells in this species vary much in size, but they all agree in being oat-shaped or fusiform (Figs. 54, 55). The cells tend to run in bundles, which

take different directions, so that in sections of the tumour seen under the microscope some bundles will have the cells cut in the direction of their lengths, and others at right angles. This must be borne in mind, or an incorrect opinion will be formed as to the nature of the tumour.

In some sarcomata the cells are so slender and contain so little protoplasm that they appear to consist of merely a nucleus



Fig. 55.—Section of a spindle-celled sarcoma from the first phalanx of the thumb. (Highly magnified.)

and cell processes. In others the cells are large, fusiform, and rich in protoplasm, and resemble the cells of young unstriped muscle. Occasionally these spindle cells are transversely striped like young striated muscle fibre.

Another peculiarity of spindle-celled sarcomata is the frequent presence of tracts of immature hyaline cartilage; indeed, in many instances this tissue constitutes so large a proportion of the tumours that they are described as chondromata; the cartilage is sometimes calcified and even ossified. It may seem strange to associate tumours containing striped

cells and cartilage with sarcomata, but the correctness of the classification is demonstrated by the fact that such tumours are apt to recur after removal, and in some of the cases in which the primary and recurrent tumours have been carefully examined the primary tumour has contained cartilage, or muscle, whilst the recurrent mass has shown no evidence of these tissues, but has conformed to the structure of a pure spindle-celled or a round-celled sarcoma. In order, therefore, to indicate the nature of such composite sarcomata, they will be referred to as myo-sarcomata (rhabdomyomata) and chondro-sarcomata. Spindle-celled sarcomata often contain round and even multi-nuclear cells.

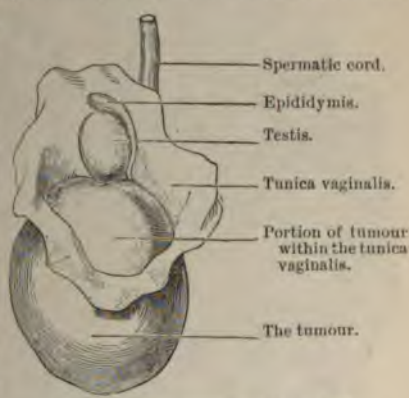

Fig. 56.—Myo-sarcoma of the testis. (*After Neumann.*)

Myo-sarcomata.—It is a remarkable fact, considering the large amount of striped muscle tissue existing in the body, that tumours composed of or containing this tissue do not arise in connection with the voluntary muscles, but make their appearance in such unexpected situations as the kidney, testis (Fig. 56), neck of the uterus, parotid gland, and in organs and tissues which, under normal conditions, do not contain muscle cells of the striped variety.

There has been much speculation as to the mode of origin of myo-sarcomata. When our knowledge of them was limited to those which occurred in the kidney, the notion that they arose in detached portions of the mesoblastic somites (Cohnheim) found favour with many; further observation, however, has shown this view to be untenable.

Tumours composed mainly of spindle cells with cross striation have been observed in connection with the testis;* in the majority of cases the patients were children.†

* Hulke and Adams, *Trans. Path. Soc.*, vol. xi. 162

† Neumann, Virchow's *Arch.*, bd. ciii. 497; and Ribbert, *ibid.*, bd. cxxx. 249.

Pernice * has recorded in detail a remarkable example connected with the neck of the uterus. The tumour contained a large number of transversely striated spindles (Figs. 57, 58). The tumour was removed, but quickly recurred; it was removed a second time, but reappeared and speedily caused death. A careful examination of the recurrent tumour showed it to consist of spindle cells, but no striation could be detected.

Fig. 57.—Racemose sarcoma of the neck of the uterus. (*After Pernice.*)

Prudden † has found cells with the transverse markings in a tumour from the angle of the mandible of a boy seven years of age; other examples connected with the periosteum have been reported by Zenker ‡ and Bayer, who found them in the orbit. Targett § found one on the scapula of a child six months old; and Marchand ‖ describes one which grew from the ischial tuberosity of a boy four years of age.

Sarcomata of the Subperitoneal Tissue.—Very large spindle-celled sarcomata are occasionally found in the belly and pelvis arising in the subperitoneal connective tissue. These tumours present some peculiar features. In the first

* Virchow's *Arch.*, bd. cxiii. 46.
† *Am. Jour. Med. Sci.*, 1883.
‡ Virchow's *Arch.*, bd. cxx.
§ *Trans. Path. Soc.*, vol. xliii. 157.
‖ Virchow's *Arch.*, bd. c. 42.

place, they are nearly always globular, and not unfrequently resemble a football in shape and in size. They have been observed in the neighbourhood of the kidney, and in some instances this organ occupies a recess in the tumour. Retro-peritoneal sarcomata of this kind often have the adjective peri-renal applied to them. There was a large tumour of this kind in the museum of St. Mary's Hospital. In the description of it by Jackson Clarke,* it was described as growing from the lesser omentum. The museum of McGill College contains a large globular tumour of this kind weighing eight pounds, which was removed by Shepherd † in 1897 from the mesentery of a man aged twenty-eight years: eight feet of small intestine were removed at the same time. The man was alive in 1900. I have twice removed sarcomata of this character from between the layers of the mesometrium ‡ (broad ligament), and many of the cases reported as "myomata of the broad ligament" are probably large, slowly growing spindle-celled tumours. They would appear to be the least malignant of all the varieties of sarcomata, and are extremely rare. Many of the reported cases weighed upwards of thirty pounds.

Fig. 58.—Microscopic characters of a uterine sarcoma containing muscle cells. (*Pernice.*)

* *Trans. Path. Soc.*, vol. xliii. 60; see also Pearce Gould, *Medico-Chir. Trans.*, vol. lxxxiii. 257.

† *Brit. Med. Journal*, 1897, vol. ii. 966.

‡ *Trans. Obstet. Soc.*, vol. xli. 298.

Deciduoma.—Until 1889 sarcoma of the uterus was regarded as a rare affection, but in that year Sänger and Pfeiffer independently described a variety of sarcoma which arose in the uterus, presenting microscopic characters so strongly resembling decidual tissue that it has become customary to speak of such a tumour as a *deciduoma.*

The descriptions of a very large number of cases have been reported, and it is clear that many examples of malignant disease, formerly classed as cancer of the uterus, are really tumours which contain a large number of cells similar in size and character to the big cells found in the placenta and known as "decidual cells."

The most important observation associated with these tumours is the fact that a deciduoma is apt to occur in the endometrium within a few weeks, or months, of abortion or delivery at term, and especially after the so-called "hydatid mole." The course of the disease is marked by oft-recurring profuse bleeding, rigors, and pyrexia, great emaciation, enlargement of the uterus, and secondary nodules in the viscera and occasionally in the bones. The disease is malignant, and runs a rapidly fatal course.

The uterus, when occupied by a deciduoma, enlarges so as to become appreciable in the hypogastrium. Its contour is usually tuberose, and on section the bosses are filled with a soft reddish mass resembling the pulp of a pomegranate.

In a few specimens observed in the early stage the disease was limited to the endometrium.

Several views are held in regard to the origin of deciduoma. Some regard the disease as arising in retained fragments of placenta or decidua; others as a sarcoma of the chorion. Indeed, there is as much diversity of opinion in regard to the origin of this disease as there is concerning the tissues in which the placenta arises.

It is well established that the histologic features of a sarcoma are largely modified by its environment, and, as very large connective cells (decidual cells) are abundant in the endometrium of a gravid uterus, it naturally follows that these cells would be conspicuous in a sarcoma arising in a uterus recently gravid.

The circumstance that this extraordinary species of tumour is in so large a proportion of cases associated with "hydatid moles" is worth careful consideration in relation to the tissue in which deciduoma arises. Some authors have pointed out that the myxomatous change in the chorionic villi is associated with very active growth of the epithelium of the villi, and the aggressiveness of the chorionic epithelium has been insisted upon by several observers. It has also been recorded that in cases of hydatid moles the chorionic epithelium invades the uterine wall, and occasionally penetrates it as far as the peritoneal investment. It is possible and perhaps probable that the term deciduoma covers two distinct varieties of tumour, one arising in decidual tissue and the other having its source in the investing cells (syncitium) of the chorionic villi. It is also necessary to remind the reader that a similar histologic and taxonomic problem is presented by the renal sarcomata of infants. (Chap. XIII.)

Whatever view may be held in regard to the actual tissue at fault, it is beyond question that, in regard to rapidity of growth, dissemination, and the short time they take to destroy life, these so-called decidual tumours are only equalled by the deadly sarcomata which arise in the periosteum of the femur and the humerus.

CHAPTER VIII.

SARCOMATA (*continued*).

MELANOSIS AND MELANO-SARCOMATA.

In the majority of mammals there are certain epithelial and fibrous tissues which normally contain pigment. Among pigmented tissues the skin and the epithelial layer of the retina hold the first place. In skin the pigment is chiefly contained in the deeper layers of the rete mucosum; and hair being derived from the cells of this layer is pigmented also. In many mammals other tissues contain pigment, such as the mucous membrane of the roof of the mouth of the dog, and the blue coloration of the vaginal mucous membrane of the vervet monkey.

In man the amount of pigment in the skin varies greatly, so that we may pass gradually from individuals whose skins are intensely black to others who have no trace of cutaneous pigment.

It is a noteworthy fact that animals with no pigment in the skin also lack pigment in the uveal tract of the eyeball. A familiar example of this is the white rabbit with pink eyes. Such a condition is termed *albinism*, and colourless animals, or *albinos*, occur among all classes of animals, vertebrate and invertebrate. Excessive development of black pigment in the skin is known as *melanism;* this is much rarer than albinism.

Abnormal distribution of pigment is common; in man it gives rise to the condition termed leucoderma when it affects the skin, and unequal distribution of pigment in the retina is known as retinitis pigmentosa. Irregular patches of black in the skins of horses cause them to be described as piebald, and when disseminated in small dots and irregular tracts they are said to be grey.

In the white races of men the pigment granules are almost entirely confined to the cells of the rete mucosum, but when the pigmentation is very marked it will be found distributed in the other tissues of the skin. The pigment, or melanin as it is called,

lies within the cells either in the form of black or brown granules, or they may be uniformly stained by it.

Melanosis is sometimes produced by parasites. This variety of melanism is rarely seen in man, but is fairly frequent in other animals. An example is depicted in Fig. 59.

Pigmentation in this form is not uncommon in the lungs of mammals, but it must not be confounded with the irregular black patches so common in the lungs of those who dwell in densely populated and smoky towns. Small nodules surrounded by a zone of intensely black pigment are not uncommon in the skins of dogs; the central nodules usually contain an encysted parasite.



Fig. 59.—Anterior portion of a dace; each black spot contains a central white dot representing an encysted parasite.

Pathological pigmentation in its most serious forms is found in connection with tumours arising in the skin or within the eyeball.

1. **Melano-sarcomata.**—It was formerly the custom to describe all varieties of melanotic tumours as cancers. Later, when the histological distinctions between sarcoma and cancer were more accurately defined, it was found that the majority of tumours containing black pigment were structurally sarcomata. Recent careful researches, of which some details will be given afterwards, establish beyond any doubt that some melanomata which arise in the eyeball are cancers.

In these tumours, whether sarcomata or cancers, the amount of pigment varies greatly; in some it is so little that the tumours on section present merely a brown coloration, whilst in others it may be so abundant that they are of the deepest black. The pigment particles are lodged not only in and among the characteristic cells of the tumour, but in and among those of its fibrous matrix, and even in the walls of its

vessels. It is also worth mention that the primary tumour may contain very slight traces of pigment, sometimes so slight as even to raise a doubt whether it should be called melanotic; yet the secondary growths and the lymph glands infected by it will be of an inky black. The intense blackness of the secondary deposits leads to their ready recognition, and doubtless accounts for the belief that this species becomes more widely disseminated than other malignant tumours; but an equally wide distribution of secondary nodules in unpigmented tumours will sometimes be found when the organs are submitted to a rigorous search.

Primary Melano-sarcomata of the Skin.—These occur under three conditions: the most frequent has its origin in pigmented moles; the rarer variety arises in, or near, the matrix of the nail of a finger or toe; and the third is found in the pigmented skin of the genitals and the anus.

Melano-sarcomata occurring in moles differ from other melanomata in that the cells are collected in alveoli. It is pointed out in the chapter on moles that the tissue forming the base of a mole, as a rule, presents an alveolar disposition; this structural peculiarity comes out very strongly when a mole is the seat of a melanoma. Tumours of this kind are sometimes ranked specifically as alveolar sarcomata.

A pigmented mole may remain quiescent throughout a very long life and never cause the least inconvenience; in other instances, fortunately rare, as life advances, the mole ulcerates, perhaps bleeds freely, and may even become partially healed; but coincident with the onset of ulceration the adjacent lymph glands enlarge, become charged with pigment and sarcomatous tissue, spaces filled with inky fluid form in them, and finally the overlying skin ulcerates. The infection may not proceed further than this: recurrent hæmorrhages from the fungating glands or a furious bleeding, should a large vein or artery become broached by ulceration, carries off the patient. In many cases the morbid material is disseminated into distant parts, secondary knots form in the liver, lung, kidney, or brain, and death arises from interference with the functions of these organs.

In other cases the mole, instead of ulcerating, is observed to become more prominent, and finally forms a tumour of

some size standing out prominently from the skin. In due course the lymph glands in anatomical relation with the part from which the tumour arose enlarge, and secondary deposits occur in the viscera, bones, or skin.

It does not necessarily follow that in all cases of melanomata occurring in moles secondary deposits are formed in the viscera. In some cases, which, however, are very rare, the tumour seems to become mainly a source of pigment, large quantities of which enter the circulation, to be discharged with the urine, in which it is recognised as melanin. Exceptionally the skin will assume a dusky tint, and in one instance in which a woman with a melanoma died immediately after a menstrual period, I found the corpus luteum and some distended follicles filled with an inky fluid.

Melanosis in connection with the **fingers** and **toes** assumes two forms: it may occur as a deep pigmentation of the skin, usually in the immediate neighbourhood of the nail, often involving the matrix, and even the nail itself; or a small pigmented nodule will arise in the nail matrix or in the adjacent skin. These nodules quickly ulcerate, and dissemination follows. In some of these nodules the pigment is very scanty—indeed, in some cases it is only discovered with the microscope; yet secondary nodules of an intense black colour will arise in the various organs and tissues.

The hallux is the digit most prone to be attacked by melanomata, and several examples have been carefully recorded, most of the patients being women. These cases are arranged in the following table:—

Fergusson .	M.	36	Hallux . .	*Lancet*, 1857, i. 290.
Hutchinson	F.	60	Hallux . .	*Trans. Path. Soc.*, vol. viii. 404.
Nunn . .	F.	50	Fifth Finger .	*Ibid.*, vol. xxxi. 299.
Lediard .	F.	40	Index Finger.	*Ibid.*, vol. xxxix. 307.
Bowlby. .	F.	55	Hallux . .	*Ibid.*, vol. xli. 314.
Barnard .	F.	60	Index Finger	*Brit. Med. Jn.*, 1902, vol. i. 457.

Apart from abnormal deposits of pigment such as moles and warts, melanomata are occasionally found in those parts of the body where the skin is more deeply pigmented than usual, namely, the external genitals in both sexes, and the skin around the anus.

The greater **labia** are liable to melano-sarcoma, and I have seen two examples: in each the disease ran the usual course. In one instance I have observed a spindle-celled melanoma of the **anus** in a woman of fifty years. Payr * has recorded an example of a melanoma of the penis.

Primary melanoma of **mucous membrane** is very rare, and it is odd that the recorded cases have been observed on the muco-periosteum of the hard palate. Treves, † in recording an example, reminds us of the fact that the mucous membrane in this situation is charged with pigment in certain mammals. This is the case with dogs.

Intra-ocular Melanomata.—The commonest situation of these tumours is the uveal tract, and the seat of origin accounts for the presence of pigment. Their distribution in this tract is curious, for a melanoma of the choroid is ten times more common than in the ciliary body, and a pigmented tumour of the iris is excessively rare.

Melanomata of the uveal tract are most frequent between the fortieth and sixtieth years, but they have been observed as early as the fifteenth and as late as the eighty-fourth year.

In structure they may be round-celled, spindle-celled, or mixed-celled, the size of the cells varying greatly in different tumours. The amount of pigment in intra-ocular melanomata varies greatly; in some specimens it is so abundant that the tumour is coal-black; in others it is only sufficient to impart a grey tint. Occasionally the pigment is so irregularly distributed that some parts of it are colourless.

The tumour remains for a time restricted to the interior of the globe, but it tends to escape therefrom in three directions: (*a*) along the course of the venæ vorticosæ, appearing outside the sclerotic in the situations where these veins emerge; (*b*) the presence of the tumour leads to an increase in the intra-ocular tension, and finally to sloughing of the cornea; (*c*) the growth may invade the optic nerve.

Melano-sarcomata, like all species of sarcomata, are very apt to recur after removal, and to become disseminated. The most frequent situation in which to find secondary deposits

* *Deutsche Zeit. für Chir.*, bd. liii. 221; see also Fischer, bd. xxv. 313.

† *Trans. Path. Soc.*, vol. xxxviii. 350

is the liver; but any organ may contain them, even the bones. It is surprising, considering that the eyeball is so near to and in such close relation with the brain, by so large a nerve-trunk as the optic nerve, that it should be so rarely implicated. It is a fact that when the brain is a seat of deposit it is excessively rarely the result of extension along the nerve. The amount of dissemination varies greatly; in some cases secondary knots occur in almost every organ; in others they will be limited to the liver. The lymph glands adjacent to the orbit are rarely infected. It is curious that in most cases death results more often from the secondary growths involving important organs than from the local effects of the primary tumour. An excessively rare complication of melanotic tumours is pigmentation of the skin.

The **duration of life** in patients with intra-ocular melanomata rarely extends beyond three years. A careful analysis of a large number of cases shows, however, that in many instances life may be indefinitely prolonged by early removal of the globe, and cases are known in which patients have been reported alive and well five, six, eight, nine, sixteen, and eighteen years after the operation. In the majority of cases that recur the recurrence takes place within three years of the operation. Collins and Lawford,* calculating cases in which recurrence does not take place within three years of operation as recovery, come to the conclusion, from an analysis of seventy-nine cases of which they were able to obtain complete records, that the rate of recovery is twenty-five per cent., but they point out that patients have died from recurrence or secondary deposits after a much longer interval than three years. J. Hutchinson, junr.,† has mentioned a case in which dissemination was deferred for eleven years after an eye had been excised for melanoma.

Melano-carcinomata.—Several writers who have devoted attention to intra-ocular tumours describe some of the pigmented tumours as carcinomata, using the term in the definite sense in which it is employed in this work. Much new light has been thrown on this question by the interesting investigations

* "Notes on One Hundred and Three Cases of Sarcoma of the Uveal Tract" (*Roy. Lond. Ophth. Hosp. Rep.*, Dec., 1891).

† *Brit. Med. Journal*, 1893, vol. i. 291.

of Treacher Collins.* This ophthalmologist has demonstrated the existence in the ciliary body, in the space extending from the root of the iris to the ora serrata, of a number of small tubular processes composed of epithelial cells with the free ends projecting towards the ciliary muscle. Collins succeeded in demonstrating the existence of these processes by bleaching the cells; he regards these processes as glands, which secrete the aqueous humour. The ciliary glands are interesting in connection with melano-carcinoma, for Collins discovered among the intra-ocular tumours preserved in the museum of the Moorfields Hospital two examples from the ciliary body which were epithelial in character.

Melano-sarcomata in horses are of fairly common occurrence; the regions most affected are the tail and the parts about the anus, where they form large mushroom-like excrescences, with little disposition to ulcerate. The tumours in some cases attain large proportions, and have been known to weigh forty, fifty, and even sixty pounds. When a large tumour grows from a horse's tail it becomes a great encumbrance, which the veterinarian removes by amputation. It occasionally happens that in the operation a portion of the tumour is left behind, and its cut surface heals like other tissues. These pigmented tumours are very prone to disseminate, and secondary nodules occur in almost all the viscera; yet in spite of this, melano-sarcoma does not appear to be such a malignant affection in horses as in men.

Although most common in grey, it also occurs in white, and occasionally in black horses, and it certainly occurs in cows. Next to the anus and tail, the udder is the most frequent seat of the primary tumour, and it may spring up in the subcutaneous connective tissue in any part of the trunk. Horses may be attacked at any age from four years upwards. In structure melano-sarcoma of the horse resembles a hard uterine fibroid rather than a sarcoma. In these animals melano-sarcoma of the uveal tract is very rare.

Of all the tumours which attack the human body, none are more mysterious than the melanomata, and especially those which arise in pigmented moles.

* *Trans. Ophth. Soc. London*, vol. xi.

CHAPTER IX.

SARCOMATA (*continued*).

THEIR GENERAL CHARACTERS.

SARCOMATA are distinguished from the preceding genera of tumours in rarely possessing capsules, and when they do it is generally a spurious encapsulation depending on environment, as when they occur in the kidney, the eyeball, or the centre of a bone. It is lack of a capsule which permits them to infiltrate surrounding tissues and favours dissemination. It will be convenient to devote this chapter to the consideration of the way in which sarcomata display their malignancy.

The Blood Supply of Sarcomata.—The vascularity of sarcomata varies greatly; in all, the circulation is mainly capillary. In the small round-celled species the vessels are so numerous as to cause distinct pulsation; in the slow-growing spindle-celled varieties—especially those undergoing chondrification—the vessels are not numerous, and the tumours on section are yellowish white. It has already been pointed out, in describing the minute structure of sarcomata, that the walls of the vessels are very thin, and are often so attenuated as to resemble channels between the cells. This explains the frequency of hæmorrhage within the soft and rapidly growing varieties. Repeated extravasations of blood will sometimes convert these tumours into cysts containing blood intermixed with sarcomatous cells. Tumours transformed in this way were formerly described as malignant blood-cysts.

Although the vessels in a sarcoma are, in the main, capillaries, nevertheless the arteries supplying the tumour may be very large and numerous. When a sarcoma grows from the distal end of the femur and attains a large size, arteries supplying it from neighbouring muscular, periosteal, and articular trunks become important branches, and in such circumstances an incision into the tumour will be attended with alarming

hæmorrhage. When attempts are made to dissect out such a tumour from the limb instead of adopting more radical measures, such as amputation, these enlarged vessels must not be forgotten, or they will intrude themselves upon the surgeon in a very unmistakable manner. Arteries which, under ordinary conditions are almost inappreciable, will, when nourishing a sarcoma, attain the dimensions of the radial or even larger trunks.

Fig. 60.—Section of lung, with nodules of sarcoma secondary to a chondrifying spindle-celled tumour of the testis. (*Museum, Royal College of Surgeons.*)

Dissemination.—Sarcomata are liable to reproduce themselves in distant organs, a phenomenon frequently referred to as metastasis. It is due to minute particles of the tumour growing into the venules. These, becoming detached, are transported by the current of blood to distant organs, where they become arrested by the capillaries, engraft themselves, and then grow into independent tumours. This dissemination takes place mainly through the veins, because, as has already been mentioned, sarcomata are devoid of lymphatics. The most common organ in which to find secondary sarcomata is the lung, unless the primary growth is situated in the territory of the portal circulation; then they will be found in the liver. In very malignant sarcomata, especially the small round-celled species, secondary deposits may form in any organ of the body:

they are always identical in structure with the primary tumour. Secondary deposits of sarcoma in the lungs may destroy life by mechanically obstructing the trachea and bronchi (see Fig. 7, p. 8). I have known a nodule to slough and find its way into the trachea, and when expelled by coughing it became impacted between the vocal cords and suffocated the patient, a girl of nineteen years. In this instance the primary tumour was a periosteal sarcoma of the femur, for which amputation had been performed several months before.

The Infiltrating Properties of Sarcomata.—The tendency to extensively infiltrate the planes of connective tissue adjacent to the tumour is not peculiar to sarcomata, for it is an obvious character of carcinoma. This property of sarcomata may be studied in a marked manner in the case of mediastinal lympho-sarcomata. These tumours grow rapidly, enveloping the trachea and bronchi, the aorta, and other large vessels, the œsophagus, and large nerve trunks. The tumour extends along the branches of the bronchi, and invades the interlobular connective tissue at the roots of the lungs. When the tumour starts in the superior mediastinum it descends along the big vessels and invests the pericardium. It may even creep along the sheaths of the vessels to the heart and infiltrate its substance, and nodules of the tumour may project into the cavity of the auricles. Processes of the tumour may find their way along the sheaths of the big vessels and appear in the posterior triangles of the neck.

The relation of a mediastinal lympho-sarcoma to the adjacent structures is interesting. For instance, the large arterial trunks, though embedded in the tumour, are not as a rule damaged by it. The aorta may be so compressed by the tumour as to produce a murmur; the thin-walled veins are early compressed, and interference with the venous circulation is a marked feature. In some of the cases infiltration of the walls of the veins takes place, and processes of the tumour project into their channels.

The bronchi are very liable to be damaged by a lympho-sarcoma, for the tumour moulds itself round these tubes, and by pressure causes them to be narrowed; apart from this effect, the tissues proper of the tubes become eroded and destroyed. These changes not only induce difficulty in re-

spiration by restricting the admission of air, but the compression of the vessels accompanying the bronchi leads to changes in the nutrition of the pulmonary tissue, which end in pneumonia, gangrene, and death.

The important nerves traversing the mediastinum, the vagus and phrenic nerves especially, are often involved in the tumour, but their sheaths are rarely invaded by the cells; in some instances the left recurrent laryngeal nerve is compressed sufficiently to produce severe laryngeal spasms and even paralysis of the muscles supplied by it.

Fig. 61.—Portion of a mediastinal lympho-sarcoma, to show the manner in which the tumour extends along the bronchi and pulmonary vessels.

The œsophagus becomes compressed by an intrathoracic lympho - sarcoma, but dysphagia is not so prominent a symptom as in many cases of interthoracic aneurysm. The œsophagus may be invaded and even perforated; when this happens, ulceration and sloughing may form a cavity in the tumour, and the ulceration may even broach the aorta (Hale White).

It is a somewhat remarkable feature of lympho-sarcomata that they extend to and enclose neighbouring lymph glands without affecting them: it is by no means unusual in a section of a large mediastinal sarcoma to find bronchial lymph glands fully charged with pigment embedded in the tumour (Fig. 61).

Some writers are of opinion that some lympho-sarcomata of the superior mediastinum arise in the thymus. This, of course, is possible, but it is very difficult of proof.

The infiltrating power of sarcomata may be studied when they invade the sheath of a muscle. For instance, when a retinal sarcoma protrudes through the sclerotic and invades the orbit, it sometimes makes its way into the sheaths of the recti, and converts them into masses resembling yellow wax. On microscopic examination the various fasciculi will be found isolated by the cells of the sarcoma.

Periosteal sarcomata often invade muscles, and this is easily comprehended when the intimate relations of muscles to periosteum are remembered. Thus, in Fig. 66 (p. 100) a sarcoma of the fibula involves the origin of the flexor longus hallucis and the peroneal muscles.

The Burrowing Tendencies of Sarcomata.—All tumours in their growth tend to follow the lines of least resistance, and thus enter into nooks and crannies in the most unexpected manner. Every surgeon knows how a sarcoma of the maxilla will send processes into the spheno-maxillary fossa and creep through the foramen rotundum, to appear in the cranial cavity. Sarcomata springing from the heads of the ribs or processes of the vertebræ have been known to extend through intervertebral foramina and compress the cord, giving rise to fatal paraplegia (Fig. 72, p. 109).

It is also remarkable what slender barriers will serve as checks to sarcomata. For example, it is no uncommon condition for one of these tumours springing from the periosteum near a joint to extend in all directions and envelop the synovial membrane, yet be prevented by it from invading the joint.

The Relation of Sarcomata to Veins.—It has long been recognised that when sarcomata become disseminated the secondary tumours occur in situations which indicate that the distribution has been effected by means of the veins. Attention has already been drawn to the tendency which seems inherent in most species of sarcomata to burrow; this tendency comes out in a striking way when studied in connection with veins.

Perhaps the simplest form occurs in the eyeball. When a melanoma arises in the uveal tract, especially when the tumour

is in close relation with the choroid, it remains for a period restricted to the interior of the globe, until it produces such changes in the intra-ocular tension that the cornea sloughs and the growth protrudes externally. In many of these specimens, if the sclerotic be carefully examined in the situations where

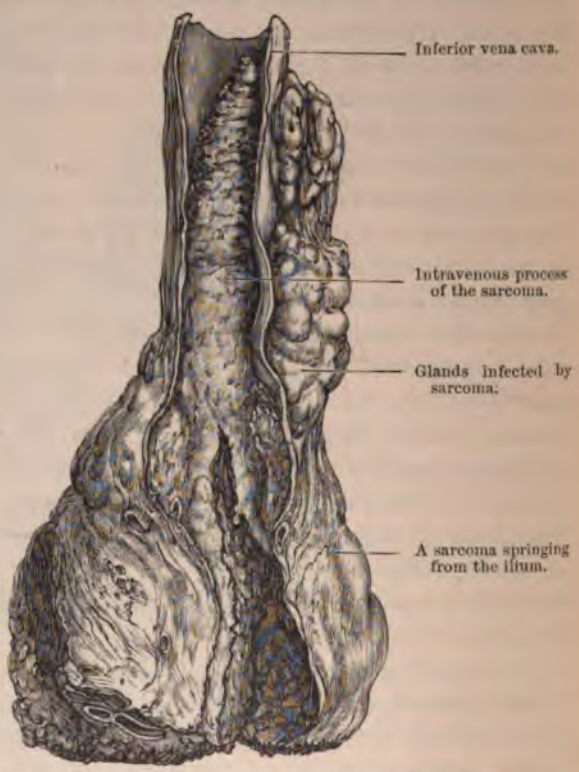

Fig. 62.—Periosteal sarcoma of the ilium invading the inferior vena cava. (*Museum, St. Bartholomew's Hospital.*

the venæ vorticosæ pierce it, small nodules of the tumour will be detected projecting through these openings, having made their way out by burrowing in the sheaths, and in some cases actually travelling along the lumina of the veins.

The relations of sarcomata to veins come out strongly when these tumours affect bones. In some examples of periosteal sarcomata the medulla is invaded by processes of the tumour making their way along the veins traversing the Haversian

canals. The converse of this is also true, for a central sarcoma will sometimes implicate the periosteum by way of the Haversian canals.

It is well established that most examples of central sarcomata occur near the joint ends of bones, and yet it is exceptional to find the joints invaded. When joint invasion happens, it occurs late in the course of the disease, and then, in most cases, the tumour creeps in through the synovial membrane. This comparative immunity of joints is usually attributed to the articular cartilage acting as neutral tissue; but it appears rather to be due to the fact that the cartilage, unlike the compact tissue of bone, is not traversed by a multitude of narrow venous channels. Extraordinary examples of the invasion of veins by sarcomata occur in the abdomen. In cases of renal sarcomata processes of tumour will find their way into the renal vein, and thus gain the inferior vena cava. Periosteal sarcomata of the pelvic surface of the ilium are very liable to infiltrate the iliac veins and extend into the vena cava. The specimen represented in Fig. 62 illustrates very well the general relation of an intravenous outrunner from a sarcoma; the process lies freely in the lumen of the vein, its apex is smooth and rounded, and there are no lateral adhesions save in the situations where the main mass of the tumour infiltrates the wall of the vein: the portion within the vein is, as would be expected, structurally identical with the main mass, and has its own blood-vessels, which are continuous with those of the extravenous portion of the tumour. When processes from a sarcoma project into a vein, the circulating blood is apt to detach large fragments, and these become dangerous emboli.

The mere presence of a sarcomatous outrunner in a vein does not necessarily imply dissemination of the sarcoma, for very large intravenous processes may exist, and the lungs be free from any gross lesion of a sarcomatous nature. On the other hand, a very small invasion may lead to extensive infection of the lungs, especially if the protruding surface of the tumour be eroded by the blood current.

Dr. Pitt * has described a case in which a man with sarcoma of the thyroid gland died suddenly. At the *post-mortem*

* *Trans. Path. Soc.*, vol. xxxviii. 398.

examination the cavities on the right side of the heart contained fragments of growth embedded in clot; on dissection it was ascertained that the sarcoma had ulcerated into the internal jugular vein.

When a vein is invaded by a sarcoma, and discharges of emboli frequently occur, they easily traverse, when small, the right auricle and ventricle, but are too large to pass through the pulmonary capillaries; hence the small vessels in the lungs act as filters, and these arrested particles become secondary foci, and may attain the size of cob-nuts.

It is possible that sarcomata may originate in the walls of a vein and extend along its lumen. Griffiths * has recorded a case of this kind in connection with the internal jugular vein.

Secondary Changes.—Sarcomata are very prone to degenerative changes; for instance, hæmorrhage is very apt to take place in those which grow quickly, producing spurious cysts. The tissues of the tumour are apt to liquefy, and myxomatous changes are very common. Calcification occurs in those which grow slowly, especially if connected with bone. When sarcomata grow rapidly and involve the skin, ulceration is very prone to occur, and leads to profuse and oft-repeated hæmorrhages, which not only exhaust the patient, but in many cases induce death.

Occasionally considerable portions of a sarcoma will necrose; this is more apt to occur in very large tumours. In such cases a large spurious cyst forms in the sarcoma, and on cutting into it the fluid escapes, with large irregular pieces of the tumour, which are generally of a greyish-white colour. When necrosis occurs extensively in a large sarcoma it will sometimes check its course in a very marked manner.

Distribution.—As connective tissue occurs in every organ of the body, so sarcomata are ubiquitous, but they occur in some situations more commonly than in others. They frequently grow from subcutaneous tissue and fascia, periosteum, the testis and ovary. They are so rare as primary tumours of the liver, spleen, and bowel that it is not possible to write a general account of such tumours from lack of material. As primary tumours of voluntary muscles sarcomata are rare.

* *Trans. Path. Soc.*, vol. xxxix. 311.

They may be of the round-celled or spindle-celled species. For a time, at least, the tumour is limited by the sheath of the affected muscle. At first the tumour appears localised to a particular spot in the muscle, but it gradually extends until the whole belly of the muscle is involved and becomes transformed into an indurated mass. On section the muscle appears to be replaced by hard, tough, pale grey material. When sections are examined under the microscope the appearance is very striking, for each fasciculus is isolated from its neighbour by collections of cells characteristic of the sarcoma.

As in sarcoma of other organs, hæmorrhage is very liable to occur in the substance of the tumour, leading to the formation of cavities with ragged walls.

Primary sarcomata have been recorded in the following muscles: rectus abdominis, peroneus longus, gracilis, tensor vaginæ femoris, adductor brevis, sartorius, tibialis anticus, and the triceps. Three cases under my own notice occurred in the pectoralis major, the extensor carpi radialis, and the adductor longus.

The age distribution of sarcoma of muscle is a wide one; in the instances enumerated above the youngest patient was eighteen, and the oldest sixty years. The disease shows a marked preference for the muscles of the lower limb.

Extreme care is necessary to avoid mistaking a syphilitic gumma in a muscle for a sarcoma.

It is a curious fact that sarcomata of **nerves**, or "malignant neuromata," as they are sometimes called, should show the same preference for the lower limbs as in the case of muscles. In the majority of instances it is the great sciatic, or its branches, the popliteal, posterior tibial, peroneal, or the plantar nerves. In more than half the cases it is the trunk of the great sciatic which is attacked. The nerve next in frequency is the optic nerve; sarcoma of this nerve is described in Chap. XVI.

Sarcomata are as rare in unstriped muscle tissue as in the skeletal muscles; and in the **heart**, which is the biggest collection of involuntary muscle tissue in the body, a primary sarcoma is unknown. Muscular organs containing mucous membrane are occasionally the seats of such tumours. For instance, in the alimentary canal, which, from the œsophagus to

the anus, is a tube of involuntary muscle tissue lined with mucous membrane, these tumours have been observed at rare intervals in every section of it—œsophagus, stomach, small intestine, colon, and rectum.

Sarcomata of the uterus offer such peculiar characters, due to the exceptional features of the endometrium, that they are specially considered in Chap. VII.

The **vagina** is an uncommon situation for sarcomata, and here they exhibit unusual characters connected with age-distribution—for in children they have a great tendency to become polypoid, or they form flattened masses in the sub-mucous layer. Occasionally the tumours may be multiple. Often the sarcoma interferes with the functions of the rectum and bladder.

As sarcomata differ materially among themselves according to the organs in which they arise, it will be necessary to devote several chapters to the consideration of this subject.

CHAPTER X.

SARCOMATA OF BONES.

THESE tumours arise in connection with bones in two situations, either in the interior of a bone, or in the deeper (osteogenetic) layer of its periosteum: hence they are spoken of as Central and Periosteal Sarcomata.

1. **Central Sarcomata** may arise in the middle of the shaft, but more frequently they originate in the cancellous tissue near the ends of the long bones. Sarcomata arising in the diaphysis belong, as a rule, to the round-celled species. Those which grow at the extremities are generally spindle-celled, and contain a variable quantity of myeloid cells; cartilage is sometimes present. They occur at any age, but are most frequent between ten and forty, and are more common in the long bones of the lower than in those of the upper limb.

When a tumour occupies the centre of the diaphysis, its growth causes expansion of the osseous boundaries, and produces a rounded or spindle-shaped swelling, and the bone may become so thin that, upon some slight exertion, it breaks. In cases where the tumour affects the extremity of the bone it will, in young subjects, infiltrate the epiphysis, but it rarely transgresses the articular cartilage.

Central sarcomata rarely affect the adjacent lymph glands. In exceptional cases, especially with small round-celled sarcomata, the cells will make their way along the Haversian canals and form a tumour beneath the periosteum. Central sarcomata lead to enlargement of the surrounding bone; hence when the soft tissues are removed by maceration a large bulb-like osseous mass is left. These specimens are common in pathological museums. In some cases this osseous capsule is so thin that the tissue of the tumour makes its way through, and as it is very vascular a strong rhythmical pulsation (accompanied by a bruit) is perceptible over the protruding portion.

2. **Periosteal Sarcomata.**—These may be round-celled or spindle-celled, and are liable to the various metamorphoses and degenerations affecting sarcomata generally, but are more liable to calcification and ossification than central tumours. They occur earlier in life than those of the preceding class, and are frequently associated with antecedent injury. They do not, as a rule, invade joints.

When growing from the periosteum near the middle of the shaft, a sarcoma may be restricted to a portion of its circumference, or entirely surround it, producing a fusiform swelling. In such specimens the shaft of the bone traverses the tumour, and may, beyond a slight amount of erosion, be unaffected by it. In such a case, however, the medulla may be infected by the cells making their way along the Haversian canals. Periosteal, like central, sarcomata have a greater predilection for the joint-ends of the bone than for the central portion of its shaft.

In size periosteal sarcomata vary greatly; in exceptional cases they have been known to exceed a metre (40″) in circumference. Many become more or less ossified, the osseous matter taking the form of delicate spicules arranged at right angles to the shaft of the bone; sometimes it forms an irregular bony mesh, the spaces being filled with sarcomatous tissue. In some specimens the bone is greatly thickened in the parts related to the tumour. The extensive ossification associated with sarcoma of the periosteum is not a matter for surprise when we remember the bone-forming function of this tissue. The crystal-like spicules (Fig. 63) so frequently found probably represent ossification of the fibrous trabeculæ which connect the periosteum with the compact tissue of the shaft; as the periosteum is raised from the bone by the growing tumour, these trabeculæ elongate and subsequently ossify.

The Femur.—This bone is very liable to sarcomata, especially the periosteal variety; they are most frequently associated with its lower third, and invariably run a rapidly fatal course. The duration of life rarely exceeds eighteen months; often it is very much less (see page 7). Usually they occur between the fifteenth and fortieth years. A sarcoma situated at the lower end of the femur often simulates disease

of the knee joint very closely, and gives great trouble in diagnosis.

The Tibia.—Sarcomata are fairly common in this bone; they prefer the upper to the lower end, and they do not run

Fig. 63.—Skeleton of an ossifying periosteal sarcoma of the femur.

such a rapid course as in the femur. For instance, I have had the opportunity of following nine cases of sarcoma of the femur throughout their whole clinical course. All the patients died within a year of operation from dissemination of the tumour or from local recurrence. In the case of the tibia I have known

several patients, who have survived amputation of the leg for periosteal sarcoma, to be alive and in good health five years later (Fig. 64).

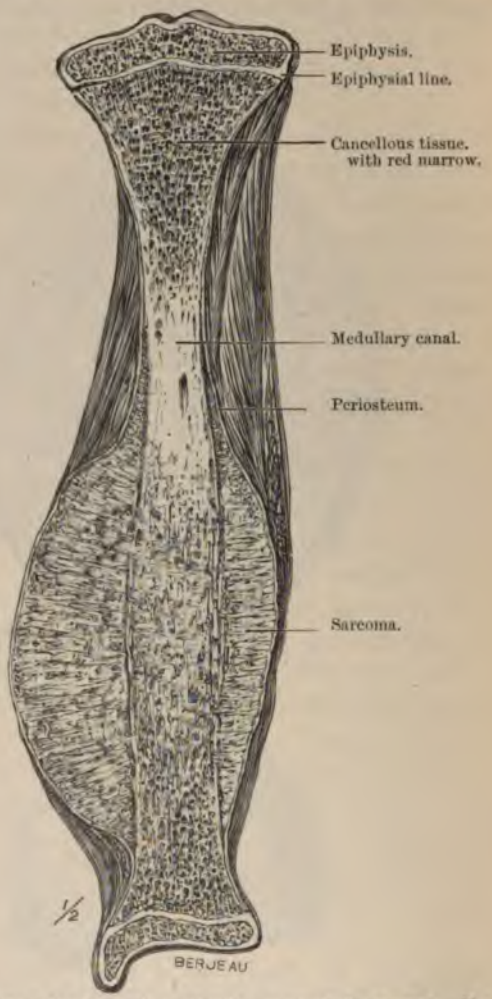

Fig. 64.—Coronal section of the tibia of a girl with a periosteal sarcoma. She was alive and well five years after the amputation.

A very large proportion of central tumours of the tibia, formerly classed as sarcomata, now rank with myelomata, and I am inclined to think that spindle-celled and round-celled central sarcomata of the tibia are rare tumours. The extra-

ordinary manner in which a central sarcoma of the tibia will expand the bone is well shown in Fig. 65. The details of this

Fig. 65.—Tibia and fibula. The tibia is greatly expanded throughout its length by a central sarcoma. From a man 24 years of age. (*Museum, Royal College of Surgeons.*)

remarkable case have been reported by Eve.*

* *Trans. Path. Soc.*, vol. xxxix. 273.

The Fibula.—This bone is not often attacked; the upper end is the favourite situation, but periosteal sarcomata may spring from any part of its shaft (Figs. 66, 67, 68).

Sarcomata of this bone are interesting because its upper two-thirds is vestigial and its persistence is probably mainly

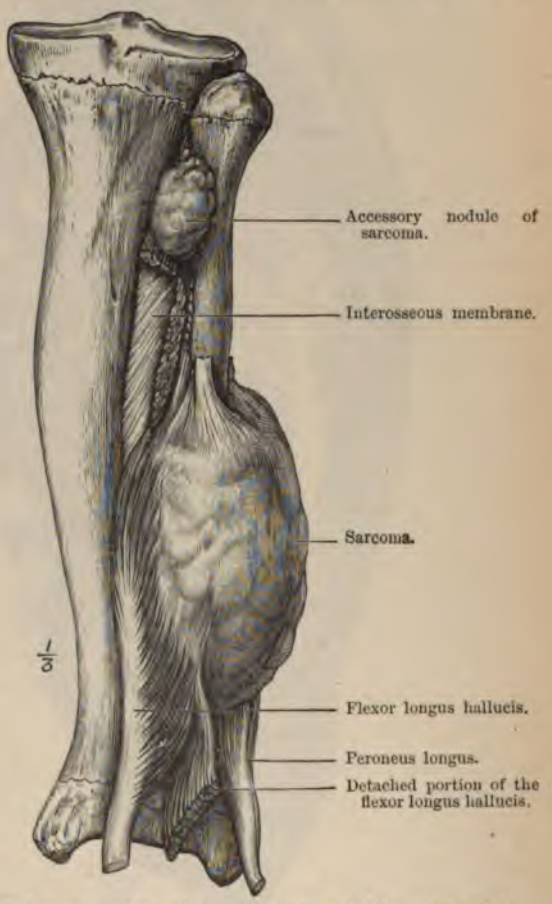

Fig. 66.—Spindle-celled sarcoma of the fibula. (*Museum, Middlesex Hospital.*)

due to the fact that it affords attachment to the muscles of the leg. The lower one-third has undergone excessive development to meet the demands of the ankle joint for greater security necessitated by the upright position in man. These facts induced me some years ago to depart from the usual rule in

treating periosteal sarcoma of the fibula. We know that when sarcomata attack the bones of the leg they do not run a very rapid course, so in a favourable case which came under my care in 1895 I resected the upper half of the fibula.* The patient recovered with a very useful limb, and was able to walk about. Recurrence took place in the scar eighteen months later; this was removed. Six months afterwards a more extensive recurrence rendered amputation a necessity. The patient died two years and six months after the original operation with signs indicating dissemination in the lungs.

A careful examination of the literature relating to sarcoma of bone makes me think that these tumours are rare in the fibula, and certainly they do not run a very rapid course.

Fig. 67.—Periosteal sarcoma of the upper portion of the fibula. The side figure shows the bone in section.

The Humerus.—Periosteal sarcomata of this bone are very dangerous to life; they occur at all ages, and generally involve the whole shaft of the bone, and form large, soft, rapidly growing, spindle-shaped masses.

Sarcomata situated at the upper end of the humerus have been very freely operated upon since 1887 by the inter-

* *Brit. Med. Journal*, 1896, vol. i. 1086.

scapulo-thoracic method of amputation. The immediate results are good, but the remote consequences are discouraging.

The Radius and Ulna.—Sarcomata of these bones, whether central or periosteal, are so rare that it is impossible to collect a sufficient number of cases to make deductions of any value. The few available records are sufficient to show that amputation has been followed by good consequences immediate and remote. Some of these, however, may have been myelomata.

Fig. 68.—Fibula showing the change induced by a central sarcoma growing in its upper end.

Clavicle.—Periosteal sarcomata of this bone are rare, and in nearly all the recorded cases have originated near the middle of the bone. A fair number of cases have been reported in which the bone and tumour have been successfully excised.

Examples reported to be central sarcomata arose mainly in the sternal end, but these were in all probability myelomata.

Attempts to treat sarcomata by complete excision of the bone have been attended by a high mortality. The remote results are bad, speedy recurrence being the invariable rule. It is a well substantiated fact that complete removal of the clavicle does not impair the movements of the upper limb.

Scapula.—It is easy to collect a score or more records relating to sarcomata of the scapula. They arise mainly from the periosteum of the dorsal and ventral surface of this bone, and often assume formidable proportions. It is rare for sarco-

mata to arise in connection with the processes of the scapula, but a central sarcoma of the coracoid process has been observed.

Scapular sarcomata are usually of the spindle-celled species, and many of them chondrify and ossify, often very extensively (Fig. 69).

Fig. 69.—Skeleton of a periosteal sarcoma of the scapula. (*Museum, St. Thomas's Hospital.*)

Since 1887, when Berger introduced the operation known as interscapulo-thoracic amputation, many surgeons have removed the scapula and upper limb in cases of scapular sarcoma. The immediate results of this formidable operation are very gratifying, and though in a large proportion of the patients there is a quick recurrence, nevertheless, life is more often prolonged than in amputation for sarcomata of many of the long bones.*

Innominate Bone.—Sarcomata occasionally arise in connection with this bone; they may be periosteal or central, and may occur in any part of it. On the whole, the ilium is the

* Berger, *Revue de Chir.*, 1898, vol. xviii. 861.

segment most commonly affected, and the tumours attain a great size. They are quite beyond the reach of surgery.

Sternum.—This bone is sometimes the seat of primary sarcoma, and a few surgeons have excised portions of the bone with the hope of eradicating the disease. The results, immediate and remote, are not calculated to bring the operation into favour. Keen * has reported a very successful example and collected the best known cases.

Ribs.—Sarcomata attack the ribs, and when they grow from the heads or necks of these bones are apt to send processes through the intervertebral foramina which, extending into the spinal canal, compress the cord (Fig. 72).

A number of instances have been described in which surgeons have removed costal sarcomata, in some cases without opening the pleura, but the results are not encouraging, and in the cases where the pleura was opened in the course of the operation the effects upon respiration and circulation were very grave.† Webber,‡ in removing a spindle-celled sarcoma of the sixth rib from a man forty-six years of age, opened the left pleura and the pericardium. The patient recovered.

Bones of the Hand and Foot.—Sarcomata of the metacarpal and metatarsal bones or the phalanges are very exceptional. Large rapidly growing sarcomata arise from the tarsus, but it is unusual to find a central tumour in these cubical bones, though they have been reported in the calcaneum.§

Sufficient facts are not available to enable anything like a satisfactory account to be furnished of the clinical course of sarcomata of the hands and feet; this is due to their rarity.

Patella.—A sarcoma of this bone is a great rarity, but a careful report of a case has been published by Parker.||

* *Medical and Surgical Reporter*, March 27, 1897.

† Quéne et Longuet, "Tumeurs du Squelette Thoracique" (*Revue de Chir.*, 1898, vol. xviii. 365).

‡ *Lancet*, 1900, vol. ii. 1347.

§ Barthauer, *Zeitsch. für Chir.*, bd. xxxviii. 462.

|| *Trans. Clin. Soc.*, vol. xxix. 22.

CHAPTER XI.

SARCOMATA OF THE BONES OF THE SKULL, JAWS, AND THE VERTEBRAL COLUMN.

The Skull.—The large bones of the cranial vault—parietal, squamo-occipital, and the tabular portion of the frontal—are liable to be attacked by periosteal sarcomata ; they grow rapidly, and form large tumours which cannot often be submitted to surgery. Pathological museums of any pretensions usually contain one or more crania exhibiting the peculiar formation of spiculated new bone characteristic of a periosteal sarcoma.

The mesethmoid is an unusual situation for a sarcoma, but Moore * has described in detail an example which is interesting from the very extraordinary effects it produced ; for as the tumour increased in size it compressed the walls of the antrum and flattened out the body of each maxilla until these bones formed a thin expanded shell to the tumour, but the bones were not eroded or invaded by it. The sarcoma also greatly widened the space between the orbits and caused great deformity of the face, but did not invade the skull (Fig. 70). There was no pain. Moore attempted the formidable task of removing this tumour, but the patient died during its progress. The parts are preserved in the museum of the Middlesex Hospital.

Sarcomata arising in the muco-periosteum of the roof of the pharynx constitute an important clinical group under the name of *Naso-pharyngeal* tumours.

They are commonly met with in patients between the ages of fifteen and twenty, and in many cases arise from the muco-periosteum of the under-surface of the body of the sphenoid, and in some instances from that lining the sphenoidal sinuses. Such tumours sometimes extend into and plug one or both nasal fossæ, processes of the tumour appearing at the nostril ; or they may extend downwards into the pharynx and impede

* *Trans. Path. Soc.*, vol. xix. 332.

deglutition. Sometimes the base of the skull is perforated by the tumour, and the patient dies of meningitis. Naso-pharyngeal sarcomata give rise to agonising pain and intense frontal headache. Whilst the pain wears out the patient, strength is further exhausted by frequently recurring and often profuse epistaxis. Exceptionally, a piece of the tumour will slough and become impacted in the larynx; suffocation has followed this accident.

Sarcomata of the Jaws.—Although it is customary to speak of sarcomata connected with the maxilla and mandible clinically as tumours of the jaws, it would be erroneous to describe them indiscriminately as tumours of bone. In each jaw there are, in addition to the bone and periosteum, two structures to consider—mucous membrane and teeth. In the case of the maxilla, the antrum requires to be considered with its gland-containing muco-periosteum.

Fig. 70.—Deformity produced by a sarcoma of the nasal septum. (*Moore's case.*)

Periosteal sarcomata of the jaws are rare before the fifteenth year, but they may occur at any age, even in infants a few months old. They belong to the round- and spindle-celled species, and grow very rapidly (Fig. 71). These tumours are less frequent on the mandible than the maxilla; they grow from any part of it. Those which spring from the outer surface of the ramus are apt to be mistaken for parotid tumours.

Periosteal sarcomata originate in any part of the maxilla, but they rarely arise from its facial surface, and, though fairly frequent on the gums, are very rare in connection with the mucous membrane of the palatine process. The muco-peri-

osteum of the antrum is a common situation for these tumours, and as they grow they cause thinning and expansion of the walls of this chamber. This enlargement of the body of the maxilla causes it to encroach on the nasal fossa and obstruct respiration; often the tumour pushes up the orbital plate and displaces the eyeball (proptosis), and in a certain proportion of cases the alveolar border is depressed. The nasal duct is frequently implicated, and when completely obstructed epiphora

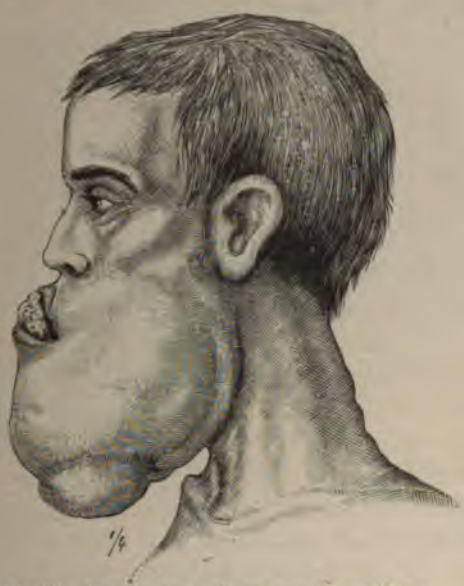

Fig. 71.—Large recurrent sarcoma of mandible.

is the consequence. Clinically, a sarcoma originating within the antrum expands its walls, and by degrees processes of the tumour make their way through and implicate the skin of the cheek, or, projecting into the nasal fossa, ulcerate, and give rise to frequently recurring hæmorrhage. When the tumour perforates the posterior wall of the antrum, it will enter the zygomatic and spheno-maxillary fossæ, and creep thence into the temporal fossa, or make its way through the spheno-maxillary fissure and ramify in the orbit, or steal through the sphenoidal fissure or foramen rotundum into the middle fossa of the cranium.

Sarcomata arising in the **follicles of teeth** are composed

of small, round, and spindle cells, with a few multinuclear cells interspersed. In their early stages these tumours are distinctly encapsuled, but as they increase in size and involve the gums the exposed surfaces ulcerate and give rise to hæmorrhage. When ulceration occurs, the neighbouring lymph glands are apt to become infected.

Sarcoma of a tooth follicle only occurs in children, and is particularly apt to involve the germ of the first permanent molar.

Sarcomata of the Palate.—The mucous membrane of the hard and soft palate is liable to malignant tumours belonging to the sarcomata and squamous-celled carcinomata. They are also liable to a peculiar tumour which is somewhat rare, named "adenoma of the palate." These tumours are usually ovoid in shape, and vary in size from a cob-nut to a hen's egg; they occur more frequently in the soft than in the hard palate, and are invariably encapsuled. These "palatine adenomata" are complex in structure. Some possess glandular tissue with ill-formed ducts and acini which in their structure mimic cancer, whilst the stroma in which they are embedded imitates sarcomatous tissue. They occur most commonly between the thirtieth and fiftieth years, but they have been met with at puberty. They are innocent tumours. They have been carefully studied by Stephen Paget * and J. Hutchinson, junr.†

In addition to these, the palate is occasionally occupied by globular or ovoid tumours, which are extremely malignant and display all the worst features of sarcomata such as arise in the mucous membrane of the antrum. These tumours have been carefully studied in Germany (especially by Nasse ‡ and Volkmann §), and ranked in a separate group as endotheliomata. They are interesting because of the similarity of their histologic features and clinical conduct to the mixed tumours of the parotid gland. My own observations lead me to the view that tumours of this kind occasionally arise not only in the mucous membrane of the palate, but also in that lining the nasal fossæ and the gums. Of the two most typical

* *Trans. Path. Soc.*, vol. xxxviii. 348.
† *Trans. Path. Soc.*, vol. xxxvii. 490.
‡ Langenbeck's *Arch.*, xliv. 233.
§ *Dent. Zeitsch. für Chir.*, xli. 1.

examples that have come under my own notice, the one grew from the mucous membrane covering the alveolar process of the mandible in a woman of fifty years, and the other arose on the mucous membrane of the nostril of a man fifty-four years of age. The tumour was freely excised in each case, and three years later there was no recurrence.

Fig. 72.—Chondrifying sarcoma of the vertebræ and ribs. A portion of the tumour crept into the spinal canal and produced fatal paraplegia. (*Museum, St. Bartholomew's Hospital.*)

Probably the rarest genus of malignant tumour of the palate is the melanotic sarcoma (see p. 82).

Vertebræ.—Primary sarcomata of the vertebral column are rare tumours. They tend to invade the spinal canal and compress the cord (Fig. 72). It is very unusual for one to be amenable to surgical treatment, but Davies-Colley * succeeded in removing one, and the patient, who was paraplegic, recovered motion and sensation.

Secondary deposits of sarcomata and cancer occur with tolerable frequency in the spine; and it is not an uncommon event for an individual to come under observation complaining

* *Trans. Clin. Soc.*, vol. xxv. 163.

of severe pain in the vertebral column, which may or may not be accompanied by a local swelling proved by careful investigation to be due to a secondary deposit of malignant disease. In some of these cases the primary source of the disease was not known to exist until the "pain in the back" led to the examination. In one instructive case mentioned by Horsley he actually operated on a spine for severe paraplegia, and discovered tumour-tissue in the arches and spine of the vertebra. Examination determined it to be thyroid gland tissue, and the patient had a goître (Chap. XXIX.). There is one aspect of secondary malignant disease of the spine which needs consideration. When a deposit of sarcoma occupies bone, it softens the texture of the bone; when this happens in the body of a vertebra, especially of the lumbar set, the superincumbent weight will gradually compress and slowly efface the affected centrum. In some cases this is so complete that the two intervertebral discs, formerly separated by the diseased vertebra, will come into apposition (Fig. 73).

Fig. 73.—A portion of the lumbar spine infiltrated with malignant disease and slowly absorbed till two intervertebral discs came into apposition.

The pain which is set up by this slow "settling" of the column is very great, and may often be described as agonising. I have noted its occurrence in the cervical as well as in the lumbar segments of the vertebral column.

It is difficult to offer any explanation of the manner in which secondary deposits of sarcoma or carcinoma in bone are determined. Certainly secondary cancer of bone is very much more common than secondary deposits of sarcoma.

CHAPTER XII.

SARCOMATA OF THE PAROTID, SUBMAXILLARY, AND LACRYMAL GLANDS, AND OF THE TESTICLE, PROSTATE, AND OVARY.

In describing spindle-celled sarcomata it was mentioned that it is no uncommon condition to find tracts of hyaline cartilage, usually of an immature type, in the substance of the tumour. When the cartilage is fairly abundant, the tumour is usually described as a chondrifying sarcoma. In addition to bone, tumours of this character occur in the parotid, submaxillary, and lacrimal glands; in the testis and in the mamma.

Sarcomata of the salivary glands, especially those arising in the parotid, have already received particular attention at the hands of pathological histologists, on account of the variety of connective and epithelial tissues which compose them. In recent years German investigators have attempted to show that many of these tumours arise from the endothelium of the lymphatics, such tumours being called endotheliomata (see pp. 114, 166). More research is required in this direction, but it is certain that the innocent and malignant tumours of the parotid gland differ not only in their histology, but also in their clinical characters, from what may be regarded as the usual course of sarcomata in other secreting glands.

1. **Sarcomata of the Parotid Gland.**—These appear as oval, smooth, and elastic swellings in the parotid immediately in front of or behind the angle of the mandible; increasing in size, they become tuberous and may implicate the tragus. Left to themselves, they burrow deeply among the tissues of the neck, dip beneath the sterno-mastoid, and acquire attachments to the carotid sheath; sometimes they creep upwards and adhere to the under surface of the petrosal, and, pushing towards the middle line, so bulge the pharyngeal wall inwards as to impede deglutition. Rapidly growing tumours tend to involve the skin and ulcerate; in very large tumours semi-

fluctuating spaces form in consequence of degenerate (mucoid) changes.

The facial nerve is usually involved in large parotid tumours; the small specimens which burrow behind the ramus of the mandible often implicate the nerve as it issues from the stylo-mastoid foramen.

Structurally, these tumours exhibit extraordinary variety. Some consist entirely of hyaline cartilage arranged in lobules bound together by loose connective tissue. The cells of the cartilage rarely possess capsules, and are often stellate, as in immature cartilage. Such grow with extreme slowness, and rarely exceed a bantam's egg in size, and may require ten or even twelve years to attain such proportions.

The large, rapidly growing tumours consist of spindle cells in which tracts and islets of hyaline cartilage are interspersed. When chondral tissue is abundant, it is very prone to mucoid changes, and soft, fluctuating spaces are formed. The connective tissue is very liable to undergo myxomatous change, and, as if to render these tumours more complex, portions of the secreting tissue of the gland are imprisoned in them.

It is not unusual in sections from a parotid sarcoma to meet with spindle cells, cartilage, myxomatous tissue, glandular acini, and fibrous tissue in an area of 2 cm. square. Exceptionally, transversely striped spindle cells are seen. Parotid tumours of such complex structure grow rapidly, and attain a large size, and often infiltrate the surrounding tissue and skin. Some of them infect the adjacent lymph glands and give rise to secondary deposits in the lungs.

Chondrifying sarcomata of the parotid are most frequently met with between the fifteenth and thirty-fifth years, but they have been observed as late as the seventy-fourth year. They present very characteristic features (Fig. 74). In their early stages they are easily removed, but many of the rapidly growing forms so quickly infiltrate the tissues that their complete extirpation is not always possible.

When left to themselves they cause death in a variety of ways. Thus they may press upon the pharynx and lead to fatal dysphagia, or ulceration may open some large vessel in the neck and produce fatal hæmorrhage; secondary nodules

sometimes form in the lungs, and induce fatal broncho-pneumonia, but dissemination is not a common feature of sarcomata of the salivary glands.

2. **Chondrifying Sarcomata of the Submaxillary Gland.**

Fig. 74.—Parotid tumour which had been slowly growing 17 years. When the woman was 57 it grew rapidly and infected the lymph glands, and destroyed the patient in six months.

—These tumours are far less frequent in the submaxillary than in the parotid gland. They are encapsuled and, as a rule, shell out easily. They grow slowly, and occur in the young as well as in adults. Glandular tissue is often associated with the cartilage.

3. **Chondrifying Sarcomata of the Lacrymal Gland.**—Tumours containing cartilage are very rare in this gland. Butlin* has described an example removed by Vernon from the orbit of a man twenty-eight years of age. The tumour had been growing nine years; it was easily shelled out of a tough capsule, and measured 6 by 4 cm. Seven years later the man was free from recurrence.

The most remarkable features of sarcomata of the salivary glands, and of the parotid in particular, are these:—

An individual may have a tumour in one of these glands which will grow to a certain size and be stationary for ten, fifteen, and even forty years; then without any warning it begins to enlarge and infiltrate the gland, cause pain, and disseminate, and destroys life in a few months. In another class of case the tumour will make its appearance, grow quickly, ulcerate, and destroy the patient in six or nine months; the microscopic structure of the tumours in both cases being similar.

Sarcomata of the Testicle.—This gland is somewhat prone to sarcomata; the two varieties, round-celled and spindle-celled, occur in about equal proportion. Lympho-sarcomata occur occasionally. They are most frequent at two periods of life: the first period begins at birth and ends with the tenth year; the second period is from the thirtieth to the fortieth years.

It is not rare to find both testes affected in cases of round-celled sarcomata, and in this respect there is an analogy between this species of sarcoma in the testis, ovary, and retina.

Spindle-celled sarcoma of the testis only attacks one testicle; in about one-half the cases the tumours contain hyaline cartilage, and in some the amount of cartilage is so large that they have been described as "enchondromata" of the testis.

Occasionally the cartilage assumes the form of tubes or cylinders disposed like the tubules of the testis. One of the best examples is the classical case described by Sir James Paget.† The secondary deposits associated with chondrifying testicular sarcomata contain cartilage, and in a few instances this tissue

* *Trans. Path. Soc.*, vol. xxvi. 184.

† *Med. Chir. Trans.*, vol. xxxviii. 247.

is more abundant in the secondary nodules than in the primary tumour. Spindle cells with transverse striation occur, especially in children, and occasionally in adults (see Chapter VII.).

Spindle-celled tumours of the testis in their structure and life history are parallel with parotid sarcomata, and, like them, are occasionally composed almost entirely of cartilage.

Lympho-sarcomata of the testis are often included in the round-celled species; this is unfortunate, as the lympho-sarcomata are even more malignant than the round-celled tumours, and disseminate much more rapidly. It is also well established that they not unfrequently attack both testes either simultaneously or after a brief interval. Hutchinson * has recorded an instructive example of this which occurred in a patient seventy years of age.

The clinical recognition of sarcoma of the testis is not by any means a simple matter; it is often impossible to distinguish between a hæmatocele and a solid tumour. The points on which it is best to rely are the weight of the tumour and absence of inflammation, syphilis, and translucency. Some sarcomata are intensely hard, others are soft and almost fluctuate; most of them are painless, but a few are the seat of continual pain.

It is necessary to point out that in some examples of sarcoma of the testis cystic spaces are apt to form which to the naked eye give the tumour a certain resemblance to the interesting condition called "cystic disease of the testicle."

A study of the effects of operation for the cure of sarcoma of the testis is very instructive, as it exhibits malignant disease in some of its worst aspects. Castration, save in very exceptional cases, is one of the safest operations in surgery. In the early stages of sarcoma the diseased testis can be completely removed. Recurrence in the wound or stump is an unusual event; but dissemination, due to infection of the aortic lymph glands, destroys more than half the patients within a year of the operation. In some of the cases the infected lymph glands parallel with the aorta form very large masses. The infection of lymph glands by sarcoma of the testis is contrary to the usual order of things in this genus of malignant tumours, but it is

* *Trans. Path. Soc.*, vol. xl. 193.

well known that the testicle is very rich in lymph vessels as well as in veins. The lymphatics from the testis run with the spermatic cord through the inguinal canal and join the lumbar lymph glands near the lower pole of the kidney. These glands are in close relation with the inferior vena cava on the right, and with the abdominal aorta on the left side; it is this intimate association with big blood-vessels which bars the way to the surgical removal of these infected lymph glands.

Dissemination of testicular sarcoma is sometimes brought about by the veins, for it occasionally happens that secondary nodules are found in the skin, lungs, and other viscera. Nevertheless, the prevailing mode of infection is by the lymphatics, and this may involve the lymph glands which extend from the fifth lumbar vertebra to the root of the neck. A very careful study of the lymphatics of the testis has been published by Most.*

Sarcomata of the Prostate.—It is a curious fact that the prostate, like the kidney, ovary, and testis, is more prone to sarcoma in the early years of life than in the adult; to judge from the records, sarcoma is five times more frequent during the first ten years of life than in all the remaining period. It may occur as late as the sixtieth year. The disease begins insidiously, and there is rarely any suspicion of trouble until the urethra becomes obstructed. In the specimen (Fig. 75), though the tumour is relatively large, the real cause of obstruction of urine, which led to the discovery of the tumour, was a bud-like process of the sarcoma which played the part of a valve at the vesical orifice of the urethra.

Very little accurate knowledge exists as to the relative frequency of sarcoma and carcinoma of the prostate, because in clinical work the two conditions are classed under the common heading, "Malignant Disease."

Ovarian Sarcomata.—In clinical work tumours of the ovaries are roughly classed as cystic or solid. From a careful analysis of a large number of lists of ovariotomy, as well as from my own observations, I have come to the conclusion that solid ovarian tumours constitute about five per cent. of the cases. Nevertheless, in spite of this small proportion, they are important, in consequence of the way they endanger life.

* Virchow's *Arch.*, bd. cliv. 138.

The ovary, like other paired organs, is very prone to become the seat of sarcoma in early life; to this succeeds a period of comparative immunity, followed by a second period of renewed but diminished liability.

Ovarian Sarcomata of Infants.—These tumours differ in several points from those found in connection with adult ovaries,

Fig. 75.—Sarcoma of the prostate in sagittal section. From a boy aged 9 years.

and their histological peculiarities are such that I proposed the term **oöphoromata** for them.

Ovarian sarcomata (oöphoromata) of infancy attack both ovaries in about half the cases; the tumours grow very rapidly, attain formidable proportions, and quickly destroy life. Their removal is attended with an excessively high rate of mortality, and in the cases which recover quick recurrence is the rule.

In structure they consist of round or spindle cells, in which

collections of cells are often conspicuous, resembling the alveolar disposition of cancer. The supposed cancerous alveoli are ovarian follicles entangled in the sarcomatous tissue, in the same way that epithelial acini become mixed up in sarcomata of secreting glands; muscle fasciculi in sarcoma of muscle; uriniferous tubules and glomeruli in renal sarcoma, etc.

Sarcoma may attack an ovary in an unborn child. Of this rare condition Doran * has described an admirable example. The subject was a fœtus born at the seventh month, and its belly contained much free fluid. (Fig. 76.)

Fig. 76.—Histologic characters of the tumour of the ovary of a seven-months' fœtus. (*After Doran.*)

c, Wall of the cavity. *f*, Ovarian follicle with ovum.

Ovarian sarcomata are more common in children than in adults. I collected from current literature one hundred cases of ovariotomy in girls under fifteen years. Of this series forty-one were simple cysts or adenomata, and thirty-eight were typical dermoids; the remaining twenty-one being sarcomata. This, however, is far short of the real proportion of sarcomata, because there are many records in which no operation was undertaken, the description being based on *post-mortem* examination.

Another important feature was the heavy mortality among the patients with sarcomata submitted to operation. Seven out of the twenty-one cases died, and of the fourteen which recovered I was able to ascertain that four died from recurrence within a year of the operation.†

The youngest child on record who has been operated on for sarcoma of the ovary was thirty-three months. Unfortunately, death occurred a few hours after the operation.‡

* *Trans. Path. Soc.*, vol. xl. 200.

† The tables and references are given in my work, "Surgical Diseases of the Ovaries" (2nd ed., 1896).

‡ Hoffman, *Am. Jour. of Obstet.*, 1897.

Ovarian Sarcomata in Adults.—Sarcomata are rare in the ovaries between the sixteenth and twentieth years; after this age they are encountered occasionally, and, as a rule, are unilateral. The two common periods for sarcoma to arise in the adult ovary are from the twentieth to the thirtieth years, and after the menopause. The hard encapsuled tumours of the ovary formerly classed among the sarcomata are now described as ovarian fibroids in Chap. XXII., since Doran, Briggs, and Fairbairn have clearly shown that they are free from the odium of malignancy.

Many ovarian sarcomata arise quickly, attain very large proportions often in a few months, and are accompanied by hydroperitoneum and marked leucocytosis. Such tumours are very soft and succulent, and occupied by spurious cysts due to degenerative changes. Microscopically they consist of round or oat-shaped cells, and, as a rule, the more these cells predominate the more ominous is the outlook for the patient. Often the cellular elements burst the limiting tissues of the tumour, and, implicating adjacent organs—such as uterus, bowels, bladder, veins, and arteries—render removal during life impossible. Dissemination also occurs, and life is often destroyed within a few months of the onset of symptoms.

There are few tumours which illustrate malignancy in such a marked manner as some of these oat-shaped soft sarcomata of the ovary. For instance, in favourable cases the ovary is completely removed by operation, its pedicle is slender, and the whole thing seems isolated. The pelvis is free from deposit, and there are no enlarged glands. Convalescence is tardy. In two or three months the patient may come back with the pelvis occupied with a mass of recurrent growth, and death from exhaustion occurs a few weeks later.

Sarcomata of the Mammary Gland.—The mamma is occasionally the seat of a sarcoma, and when we take into consideration the large amount of connective tissue which it often contains, it is somewhat surprising that these tumours are not more frequent: of one hundred consecutive examples of malignant tumours of the breast, two were sarcomata. As is the case with sarcomata growing in the parotid gland, these tumours, originating in the connective tissue of

the breast, usually entangle the ducts and acini in their immediate neighbourhood: such incorporated glandular structures occasionally give rise to cystic spaces, which, when viewed in section under the microscope, exhibit a regular lining of epithelium. Such tumours are often called "adeno-sarcomata." This is a misuse of the term sarcoma, and it has unfortunately been extended so as to include many adenomata of the breast.

This gland is liable to round- and spindle-celled sarcomata. The round-celled species rapidly infiltrate the organ and invade adjacent structures, giving rise to brawny indurated tumours. They recur very quickly after removal, and grow with fearful rapidity in young women and in those who are suckling.

Spindle-celled sarcomata grow slowly, and in the few reported cases the tumour had attained the proportions of an orange before removal. In the breast, as in the case of the salivary glands and testis, such tumours occasionally contain tracts of hyaline cartilage and bone.*

* Bowlby, *Trans. Path. Soc.*, vol. xxxiii. 306; and Battle, *ibid.*, vol. xxxi. 473.

CHAPTER XIII.

SARCOMATA OF THE KIDNEY AND ADRENAL.

A CRITICAL analysis of a very large number of records demonstrates that sarcomata of the kidney exhibit a peculiar age distribution. Thus, during the first five years of life they are common; then follows a period of comparative immunity.

The second period of liability is from thirty to fifty. Of course, sporadic cases occur between childhood and thirty, but they are relatively infrequent. It is also very remarkable that the tumours in the infant and adult periods of life not only differ remarkably in structure, but arise in different regions of the kidney; for the renal sarcomata of infant life are lodged in the pelvis of the kidney, and those of adult life originate mainly in connection with its capsule.

Sarcomata of Infants.—During the first five years of life the kidneys are exceptionally liable to sarcomata possessing peculiar characters: they originate in the connective tissue of the renal sinus, and gradually distend the cortex until the tumour is surrounded by a thin capsule formed of expanded secreting tissue of the kidney. On this account these tumours are described as being encapsuled, but it is a spurious encapsulation formed partly by renal tissue and in part by the true capsule of the kidney (Fig. 77). On section, such sarcomata are yellowish-white, and the cut surface is often dotted with groups of small cavities, due to secondary changes, especially when the tumour is very large.

The base of such sarcomata is connective tissue containing cells of various shape and size: some are round or oat-shaped, and others are spindles. In a fair proportion of specimens many of the spindle cells present the cross striation so characteristic of the fibres of voluntary muscle, and they lack a sarcolemma. When these cells are present the tumour is sometimes termed myosarcoma.

In other examples the ground substance contains groups of tubules lined with regularly arranged cubical epithelium (Fig. 78), and in section resembling a number of renal tubules cut transversely.

A careful microscopic study of these tumours, as well as a critical analysis of the descriptions published by others, indicates that when the striped cells are very abundant the tubules are, as a rule, absent. In examples containing many tubules, as well as those in which striped spindles are numerous, the round, oat-shaped, and spindle sarcoma cells are equally abundant. It has been suggested by Paul that, as the most typical myo-

Fig. 77.—Renal sarcoma in section; removed from a child aged 20 months.

sarcomata are more sharply delimited from the other varieties, the tubular elements may be derived from the kidney. I did not at first acquiesce in this view, but a more extended inquiry leads me to accept it. This is a matter worth consideration, because a study of the fœtal kidney demonstrates very clearly that the renal sarcomata of infancy arise in the connective tissue of the renal sinus. The epithelial cylinders are due to the entanglement of uriniferous tubules, in consequence of the sarcoma invading the cortex, whilst the striated spindles are derived from the muscle-tissue of the renal pelvis, which is an expansion of the hollow muscle known as the ureter.

Thus the doctrine of tissue prototypes is abundantly ex-

emplified and satisfied by the normal tissues, without any need of invoking assistance from misplaced segments of adjacent mesoblastic somites, a theoretical mode of origin which never commended itself to my mind. These studies demon-

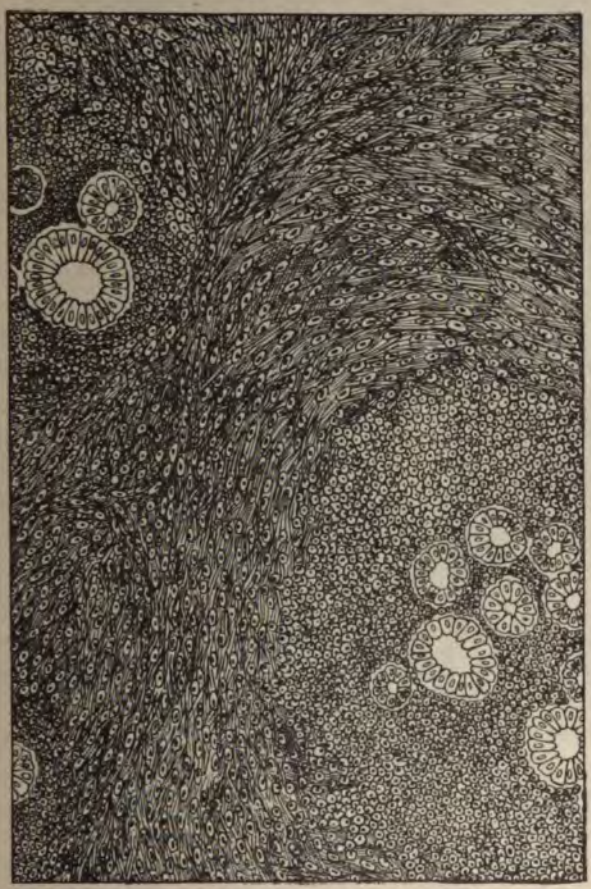

Fig. 78.—Microscopic characters of a renal sarcoma. (From an infant of 20 months.)

strate in no uncertain way that the so-called renal sarcomata of infants are extrinsic in origin, and strictly non-renal. This view is now held by all who have carefully looked into the matter; and it is worth mention that in 1857 Van der Byl exhibited at the Pathological Society, London, a large renal tumour, from a boy aged eight years, which measured 82·5 cm.

(33 inches) and weighed 31 lb.; and in the description of the specimen in the catalogue of the Middlesex Hospital Museum, it is definitely stated that the growth appears to have sprung from the concavity of the kidney, and a narrow band of renal tissue can be traced round a great part of the circumference of the kidney. The general appearance of this boy in such dreadful circumstances is shown in Fig. 79. It is characteristic of these sarcomata that the ureter is rarely obstructed. This extraordinary freedom of the ureter from invasion explains the rarity of hæmaturia in these cases, and, perhaps, what is otherwise remarkable, the painlessness of these tumours in children, for there is no pressure from accumulated urine. Certainly a child with a very large renal sarcoma has been absolutely free from pain, and amusing himself with his playmates in the garden three days before he died. Indeed, many mothers, when the gravity of a renal tumour of this kind is explained to them, will express their astonishment that a child, apparently in excellent health and spirits, could be in such serious straits as the surgeon would have them believe.

Fig. 79.—A boy aged eight years with a renal sarcoma which weighed 31 pounds.

Though the ureter so constantly escapes invasion, yet the veins are always implicated; and this constitutes one of the most peculiar as well as most dangerous features of renal sarcomata in children. The tumour tissue extends into the renal vein, and often projects and even runs for a long distance into the inferior vena cava; portions are detached and carried to the pulmonary circulation, and are arrested in the capillaries of the lung, and originate secondary deposits. The intravenous apex of such an outrunner is usually cone-shaped and smooth. Occasionally a large fragment is detached, and this has been known to block the right auriculo-ventricular orifice (Osler). Such a gross embolus is uncommon. Plugging of the vena cava by an outrunner is by no means rare, and gives rise to œdema of the lower limbs. In a case under my own care the inferior vena cava was completely obstructed from its origin to its termination by a sarcomatous extension of this kind.

It is a singular and well-established fact that when certain paired viscera, such as the kidneys, ovaries, eyeballs, and crura cerebri, are in early life attacked by sarcomata, in a very large proportion of cases, perhaps half the number, the disease is bilateral. In relation to this matter, Abbe recorded a very important observation. He successfully extirpated a kidney for sarcoma in a child of one year and two months. Four and a half years later the little patient again came under his care with a sarcoma in the remaining kidney. In 1893 I collected and tabulated in the first edition of this book twenty-one complete records of renal sarcoma in infancy which had been submitted to nephrectomy. In the list of twenty-one cases, twelve patients died as a result of the operation; of those which recovered all died of recurrence within a year. Since the publication of that table a large amount of interest has been aroused in the question of the results of nephrectomy for sarcoma, and it is now an easy matter to collect a hundred records. The analysis of a large number of these reports shows that nephrectomy for renal sarcomata in children under six years of age has a mortality of over 50 per cent. Of the fifty that recover, forty-five die from recurrence at periods varying from two months to a year. In the remaining five, life may be prolonged, as shown in the adjoining table :—

RENAL SARCOMATA IN INFANTS.

Table of Cases in which life was prolonged beyond one year by nephrectomy.

Reporter.	Age.	Result.
Hicquet	6 months	Died 1½ year after operation. (*Acad. Roy. de Méd. de Belgique*, Jan. 28, 1882.)
Schmidt	6 months	Alive and well three years later. (Dr. Emily Lewi. *Arch. of Pedriatics*, vol. xiii., p. 97.)
Abbe	2 years	Alive and well five years later. (*Annals of Surgery*, 1894.)
Abbe	1 yr. 2 mths.	Patient died 4½ years later from sarcoma in remaining kidney. (*Annals of Surgery*, 1894 and 1897.)
Malcolm	1⅔ years	Alive and well 10 years later. (*Trans. Clin. Soc.* vol. xxvii., p. 94, and private letter.)

It is very certain that a child with a renal sarcoma runs an enormous risk of losing its life when submitted to nephrectomy, and at the same time the chances of prolonging life are more slender than in any other surgical operation. It must, however, be borne in mind that the disease is surely fatal within a very limited period when allowed to run its own course.

Sarcomata of Adults.—These differ in many important particulars from the sarcomata of infancy. In the first place, a sarcoma in the adult arises in the cortex, usually in connection with the capsule, and then gradually invades the true tissue of the kidney. The relation of renal sarcomata to the capsule is of some importance, because similar tumours arise in the connective tissue in which the kidney is embedded; these are perirenal sarcomata, and, as far as my observations go, this is a more frequent position for them than those which we term renal sarcomata. A careful comparison of these tumours leads me to believe that, in the adult, sarcomata of the type represented in Fig. 80 have their origin in the renal capsule, whereas the sarcoma of childhood arises, as already pointed out, in the connective tissue of the renal sinus. This is a subject of some interest, because a critical comparison of the mode of origin of sarcomata in viscera similar to the kidney, *e.g.* the spleen, thyroid gland, and prostate, shows that such tumours are not only uncommon, but are often closely connected with the connective tissue investments of such organs.

Rare as a sarcoma of the adult kidney is, and especially if we exclude the clearly perirenal forms, we find that they occur much more frequently than in the liver, the spleen, or the prostate, even when we take into consideration the fact that the kidney has a double liability from the circumstance that it is a paired organ.

The whole question has assumed a new aspect since Grawitz showed that many renal sarcomata occurring in adults exhibit,

Fig. 80.—A kidney in section with a sarcoma invading its cortex. From a man 51 years of age. (*Museum, Middlesex Hospital.*)

on microscopic examination, the structure of the zona fasciculata of the adrenal. This view has excited wide interest, and, whether true or not, it has led to a keen investigation of the microscopic structure of the malignant tumours of the adult kidney.

It has long been known that accessory adrenals are found beneath the capsule of the kidney (Fig. 81), as well as on the under surface of the liver; they are also found in the retroperitoneal tissue in the course of the spermatic artery, in the spermatic cord simulating fatty tumours (Andrewes), and, strangest of all, on the anterior layer of the mesometrium near the ovary. In the last-mentioned situation these adrenal

"rests" have only been met with in the fœtus near, or at, full time. Eastwood* has recently described a large tumour removed from the uterus of a woman 48 years of age which he believed to arise in an adrenal "rest."

In addition to the topographical and histological features of these tumours, stress is laid by some observers on the presence of glycogen in the cells, inasmuch as it supports the view that they arise in embryonic tissues.

Fig. 81.—An accessory adrenal beneath the capsule of the kidney. (*Museum, Royal College of Surgeons.*)

It has long been known that the adrenal may be transformed into a large tumour in the same way that a thyroid gland becomes a goitre, and the analogy is so striking that Virchow years ago proposed for these adrenal tumours the term "struma supra-renalis." In recent years this analogy has been further justified by the fact that some of these adrenal tumours, as well as those which arise beneath the renal capsule of the kidney, and exhibit the adrenal structure, disseminate and mimic the extraordinary phenomenon known as "general thyroidal malignancy," in which tumours, exhibiting all the microscopic features of thyroid gland, appear in the bones, especially the skull, vertebræ, and femur, as well as in the viscera, in association with what appears to be a simple adenoma of the thyroid gland.

It is a point worth consideration, in relation to the theory that many renal sarcomata arise in adrenal "rests," that they only occur late in life. This is quite contrary to what occurs with other tumours which probably originate in "rests"—

* *Trans. Path. Soc.*, vol. liii. 153.

for example, sequestration dermoids, for these are essentially tumours of early life.

Whatever view may be taken of the tissue in which these tumours arise, it is quite certain that they exhibit peculiarities of structure which distinguish them from the ordinary round- and spindle-celled species of sarcomata (Fig. 83). That they are malignant is equally beyond question, for they not only recur after removal, but give rise to secondary nodules, especially in the lungs, these nodules exhibiting the characteristic features of adrenal tumours. The frequency with which the lungs are implicated is due to the tumour invading the renal vein or its branches. Though these tumours are very vascular, and their central parts are often destroyed by extravasations of blood, they do not give rise to hæmaturia, because the tumour does not invade the renal pelvis. This is the most striking fact in their clinical history.

Fig. 82.—Sarcoma of the kidney supposed to arise from an adrenal "rest." Removed from a woman aged 42 years, during pregnancy. She was in good health two years later, in spite of having borne a child.

Treatment.—As in the case of visceral sarcomata generally, the only available treatment for sarcoma of the kidney is early excision, but this is rarely of much service. The mortality of the operation is nearly as great as in renal sarcomata of infancy, for about half the patients submitted to nephrectomy for malignant tumour of the kidney die. Of those who recover, in nearly all recurrence takes place within a year, and in most of them within a few months.

It is an interesting fact, and one to which I have devoted

great attention, that in the very few recorded cases in which adult individuals have survived nephrectomy for sarcoma more than a year, the tumour belonged to the variety which imitates the structure of the adrenal. Thus the patient whose kidney is

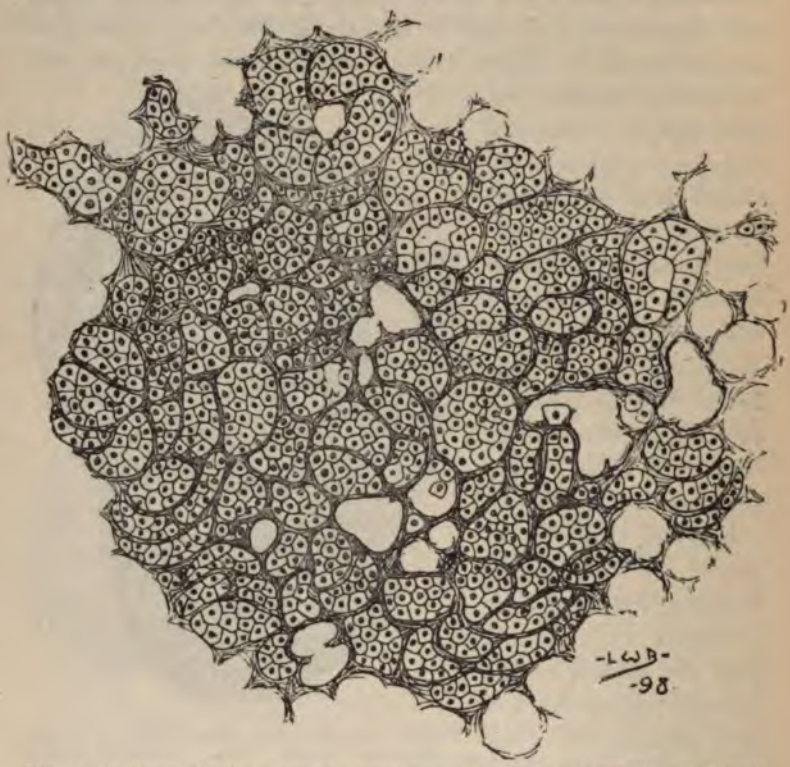

Fig. 83.—Microscopic characters of a renal tumour supposed to arise in an adrenal "rest." The tumour was removed from a woman 58 years of age. She survived the operation three years, and died of bronchitis. There was no evidence of dissemination.

represented in Fig. 83 died three years after the operation from an acute attack of bronchitis. There were no signs of recurrence or of dissemination. Ris * reported a case in which Kronlein performed nephrectomy on a woman fifty-six years of age for a tumour described by Klebs as an adeno-sarcoma. She was alive and well five years after the operation.

* Bruns' *Beiträge*, bd. vii. 146.

Maidlow * has had a success of this kind. He performed nephrectomy on a woman twenty-five years of age for a renal sarcoma weighing seven pounds. She was alive and well three years later.

SARCOMATA OF THE ADRENALS.

The adrenals, like the kidneys, are liable to sarcomata, and in recent years some attention has been devoted to them because they are under certain conditions liable to surgical aggression.

The somewhat scanty records at present available indicate that the adrenals, as is so common with other paired organs, are liable to sarcomata at two periods—namely, in childhood and in adult life. Adrenal sarcomata of children are prone to attack both organs, whereas in the adult they are usually limited to one adrenal.

Adrenal Sarcomata in Children.—Knowledge concerning these is entirely derived from observation in the *post-mortem* room. Some interesting records have been furnished by Greenhow,† Hale White,‡ Dalton,§ and others, from which we learn that sarcomata of the adrenals are very rare, that they may occur in the earliest years of life, and may attack one or both organs, and form a tumour which may attain the size of a cocoanut. Another very remarkable feature occasionally associated with sarcoma of the adrenal is an overgrowth of hair over the surface of the body, and this is occasionally associated with coloration of the skin. This change in the colour is described as a "coppery hue," unlike the bronzing of Addison's disease (Ogle ||); and Colcott Fox, in referring to a case observed by Dickinson, writes, in reference to an adrenal sarcoma in a child of three years, that she had an extraordinary development of hair and a "gipsy colour" without bronzing. This overgrowth of hair has also been observed in adults in association with a tumour of the adrenal.

Adrenal Sarcomata in Adults.—The accounts of tumours

* *Brit. Med. Journal*, 1898, vol. l. 426.
† *Trans. Path. Soc.*, vol. xviii. 260.
‡ *Trans. Path. Soc.*, vol. xxxvi. 464.
§ *Trans. Path Soc.*, vol. xxxvi. 247.
|| *Trans. Path. Soc.*, vol. xvi. 250.

believed to be primary sarcomata of the adrenals betray a large amount of confusion in the minds of surgeons. Since the publication of Grawitz's observations, that certain renal sarcomata probably arise in accessory adrenals, there has been a tendency to assume that some of these tumours arise in the adrenal and gradually become incorporated with the adjacent parts of the kidney.

There are at present no facts to support such an assumption, and those who have advanced this view have failed to take

Fig. 84.—Adrenal tumour, with kidney *in situ*. (*Museum, Royal College of Surgeons.*)

steps to determine the presence or absence of the adrenal in such cases, and their efforts have only served to increase a literary rubbish-heap of false facts already far too big.

It is worth remembering that the source of the well-known lymphatic cysts in the necks of children (cystic hygroma) was supposed to be the intercarotid gland, till Julius Arnold had an opportunity of dissecting a case in which he demonstrated the presence of the normal intercarotid gland and a so-called cystic hygroma.

A careful inquiry of this kind is much needed to determine the presence or absence of an adrenal in an individual with a supposed primary adrenal sarcoma invading the kidney.

It should also be remembered that the kidney is occasionally embedded in a large sarcoma arising in the subperitoneal tissue, and on one occasion I removed a tumour of this character, with the kidney, from a woman 73 years of age. The operation was undertaken because the tumour resembled an ovarian adenoma. The patient recovered, but six months after she reported herself with an extensive recurrence.

It is, however, a fact that sarcomata arise in the adrenals of adults and sometimes attack both organs; and they also display the usual features of malignancy, inasmuch as they grow rapidly, disseminate, and quickly destroy life.*

In describing cases of sarcomata of the adrenal in infancy, mention was made of the occasional occurrence of abnormal general hairiness, and a remarkable case of this kind has been recorded by Knowsley Thornton.† He removed from a lady thirty-six years of age a large sarcoma of the left adrenal. The patient was covered "with long, silky hair, and had to shave her face just like a hairy man." Dr. Keith had performed oöphorectomy upon her six or seven years previously. The adrenal sarcoma was removed in April, 1889, and in November of the same year she wrote that she was like her old self, and had "all the external appearance of other women."

* West, *Trans. Path. Soc.*, vol. xxx. 419; and Turner, *ibid.*, vol. xxxvi.
† *Trans. Clin. Soc.*, vol. xxiii. 150.

CHAPTER XIV.

NEUROMATA AND ALLIED CONDITIONS OF THE NERVOUS SYSTEM.

Neuroma.—This may be defined as a tumour growing from, and in structure resembling, the sheath of a nerve.

The term neuromata is often used, especially in clinical work, as signifying tumours on nerves, but as they are sometimes composed of fibrous, fatty, or even sarcomatous tissue, it would be better to speak of them as lipomata of nerves, sarcomata of nerves, and so on.

The tumours which most strictly correspond to my definition are those known as neuro-fibromata, and it will be convenient to include the curious nodule known as the "painful subcutaneous tubercle" described by Wood in 1812.

A neuro-fibroma is usually fusiform, and grows from the side of a nerve; when large, it may spread out the fasciculi of the nerve; exceptionally the nerve-fibres will traverse the tumour. The long axis of the neuroma coincides with that of the nerve from which it grows.

In size neuro-fibromata vary greatly: some are no larger than lentils, others may be as big as eggs; larger specimens are very exceptional. They occur on the cranial as well as on the spinal nerves, and form on their roots, trunks, branches, or the terminal twigs. Neuro-fibromata form smooth swellings, which are mobile, and when situated in the subcutaneous tissue glide easily under the skin; they are encapsuled, and may be easily enucleated; are extremely liable to become myxomatous, and in large specimens this change leads to the formation of cavities in the tumours. These changes account for the various names applied to them, such as myxoma, myxo-fibroma, myxo-sarcoma, and the like.

Painful Subcutaneous Tubercle.—This term was applied by Wood in 1812 to a small discrete nodule which forms in the

subcutaneous tissue. It is usually of the "size and form of a flattened garden pea," but it very rarely exceeds the size of a coffee bean. When examined by the finger it feels like a small shotty body slipping about immediately beneath the skin. Structurally the "tubercle" consists of fibrous tissue very like that which constitutes the bulk of the nodules in molluscum fibrosum; it is rare that a nerve-fibril can be traced to it.

The interest of these bodies is due to the "very severe and excruciating pain" associated with them. The pain is paroxysmal, and usually increases in severity and in frequency according to the length of time the disease has existed. If the "tubercle"—for it is usually solitary—is struck, or even touched, acute pain is produced.

They occur much more frequently in women than in men, and are commonly met with in early adult life; and though a "tubercle" may form on any part of the body, it shows marked preference for the lower limb. Excision of the little body at once, and permanently, arrests the pain.

Ganglionic Neuroma.—This is a tumour composed of nerve-cells, nerve-fibres, and neuroglia. They are extremely rare tumours. Klebs described a tumour of this kind which grew from the floor of the fourth ventricle near the calamus scriptorius. The tumour was nearly as large as a walnut. It has been thought that some tumours described as gliomata may have been ganglionic neuromata; on the other hand, however carefully the histologic features of these tumours have been described, there has always been a doubt lest normal brain tissue became included in the tumour. However, this cloud has been dispelled by the observation that tumours containing ganglionic tissues occur in connection with the great cords of the sympathetic system as well as in the subcutaneous tissue.

In one of the most remarkable cases, recorded by Knauss, a girl eight years old had sixty-three tumours in the subcutaneous tissue of the trunk and thighs (Fig. 85): they varied in size from a pea to an orange, were firm and elastic, and not painful. Microscopically these tumours were found to be composed of ganglionic nerve-cells, medullated and non-medullated nerve-fibres. Knauss believed that these tumours were derived from the minute ganglia on the finest terminal

fibres of the sympathetic system which accompany the blood- and lymph-vessels. Knauss's description of the microscopic

Fig. 85.—Girl 8 years of age, with sixty-three ganglionic neuromata in the subcutaneous tissue of the trunk and thigh. (*Knauss, in Virchow's "Archiv,"* bd. cl., s. 111.)

characters of the tumours, which clinically resembled lipomata, is accompanied by careful drawings.

Neuro-fibromatosis.—Under this heading it is now necessary to describe several affections which were formerly regarded as being quite distinct. These are multiple neuromata, molluscum fibrosum, plexiform neuromata, sarcomata of nerves, and glioma. It will be useful to state a few facts concerning

Fig. 86.—Multiple molluscum fibrosum combined with tumours on the brachial plexus of a man 37 years of age. (*After Payne.*)

each of these conditions before describing their intimate relationship.

It has long been known that neuromata sometimes occur on nerves in extraordinary numbers. The remarkable case of Michael Lawlor, described in Smith's classical monograph,* was, in all probability, an example of this combination. It was estimated that this man had at least 2,000 tumours. There

* "Neuroma," Dublin, 1849.

were 450 tumours counted on the nerves of the right lower limb, and 300 on the left. There were 200 tumours on the right and 100 on the left upper limb. The pneumogastric

Fig. 87.—A native of Sierra Leone, aged 50 years, with molluscum fibrosum. (*Lamprey.*) The tumours, which were congenital, varied in size from a peppercorn to a billiard ball.

nerves and their branches possessed 60 tumours, some of large size. The remainder were on the trunk.

Several cases of this kind have been carefully described, but probably in no individual has a greater number of nodules been detected.

In 1882 Professor von Recklinghausen * published an important monograph, in which he demonstrated not only that multiple neuromata were sometimes associated with molluscum fibrosum, but that the two conditions were closely related, and he urged that the molluscum bodies of the skin are formed on the cutaneous nerves, and are as truly neuromata as the tumours on the epineurium of the larger nerves.

Fig. 88.—Native of Bengal with molluscum fibrosum of the arm: there were also discrete nodules on other parts of the body. The man belonged to the cowkeeper caste.

Dr. Payne,† who was among the first in this country to study the disease in the new light afforded by von Recklinghausen's valuable work, does not accept his view entirely, and thinks that some of the molluscum bodies appear to be formed around other structures of the skin, such as glands and hair follicles.

In typical cases of molluscum fibrosum the skin of the trunk and limbs presents numerous small tumours, consisting

* "Die multiplen Fibrome der Haut," Berlin, 1882.

† *Trans. Path. Soc.*, vol. xxxviii. 69.

mainly of fibrous tissue springing from the subcutaneous connective tissue. These tumours are of various sizes, some being no larger than a pin's head, whilst many are as big as a filbert, and a few even larger. The majority are about the size of a

Fig. 89.—Multiple molluscum nodules on the scalp, nose, and fingers. The nodules on the fingers were in the course of the digital nerves.

small pea. Many are sessile, and others are distinctly pedunculated, but all are covered with skin. These tumours are mobile, soft to the touch, and of the consistence of firm fat. Sometimes the disease affects a broad area of skin on the head, trunk, or limbs, causing it to hang in pendulous folds. Exceptionally the pendulous and nodular lesions occur in the same patient. This is well shown in Lamprey's patient (Fig. 87), and in the man depicted in Fig. 88: for this observation

I am indebted to Dr. Maddox, civil surgeon in Bengal. In these cases the disease is apt to be mistaken for elephantiasis, but the fact that the lesions are congenital and the absence of filaria in the blood are sufficient for diagnostic purposes.

In its mildest form molluscum fibrosum appears as a single pedunculated tumour, a frequent situation being the labium majus (Fig. 90).

The structure of these soiltary tumours is the same as the nodules in the multiple forms and the pendulous skin folds. An unusual situation is the mammary areola (Fig. 91) or the nipple. When these nodules grow from the nose they are apt to be confounded with the condition commonly but erroneously called "lipoma nasi."

Fig. 90.—Pedunculated molluscum fibrosum from the labium majus of a woman fifty years of age: it had existed many years.

Concerning the cause of molluscum fibrosum nothing is known. The disease is not confined to any climate or race, for it has been observed in North America, the British Isles, India, Germany, and the West Coast of Africa.

Under the term pachydermatocele, Mott * described and figured several good examples of the pendulous form of molluscum fibrosum which were successfully submitted to operation, and the early volumes of the Transactions of the Pathological Society, London, contain descriptions and figures of this disease under a variety of names. The frontispiece to Virchow's "Die Krankhaften Geschwülste" is a representation of a woman with pendulous folds and a multitude of cutaneous nodules, under the title "fibrosum molluscum multiplex." The disease appears to be equally common in men and women.

* *Medico-Chir. Trans.*, vol xxxvii 155

An important feature connected with the typical generalised neuro-fibromatosis is the liability of the patients to sarcoma; this may develop primarily, or arise as a malignant change in a molluscum nodule which has existed very many years. Sarcomata of this kind do not, as a rule, disseminate.

Fig. 91.—Pedunculated molluscum fibrosum from the nipple of a woman.
(*Museum, Middlesex Hospital.*)

In the generalised neuro-fibromatosis death often results from gradual exhaustion, due to ulceration, septic changes, or sloughing of the pendulous portions of the skin. In many cases some intercurrent malady supervenes, such as pneumonia; in the patients with multiple nodules on the roots of the spinal nerves, one of them may so enlarge as to press on the cord and produce fatal paraplegia.

In regard to sarcoma supervening in the so-called molluscum nodules, it is necessary to remember that spindle-celled sarcomata arise primarily in nerve-trunks, especially in the great sciatic and its branches, quite apart from the existence of neuro-fibromatosis, localised or general. A sarcoma of a nerve recurs after removal or amputation of the limb, but dissemination is not frequent, and is probably deferred to quite the late stages.

CHAPTER XV.

NEUROMATA AND ALLIED CONDITIONS (*continued*).

The Plexiform Neuroma.—The peculiar condition to which this term has been applied is essentially a fibromatosis confined to a particular nerve or plexus of nerves. Although it is a rare condition, a sufficient number of cases have been carefully observed and recorded to enable a fairly complete account of the disease to be written. A plexiform neuroma, instead of forming a distinct tumour, as in the case of the solitary neurofibroma, appears as if the branches of a nerve distributed to a particular area of the skin became enlarged and elongated. The overlying skin becomes stretched, thinned, and raised over the thickened nerves, and is often pigmented, the usual colour being brown, like that characteristic of the hairy mole. Occasionally the skin is coarse and thick, as in the case of a molluscum nodule.

The tumour feels like a bag containing a number of tortuous irregular vermiform bodies, soft to the touch and mobile. These bodies vary in thickness from a crowquill to that of the thumb; manipulation does not produce pain, though the lumps themselves are sensitive. When the skin covering the tumour is reflected these elongated bodies will be found to lie in the direction of the nerve distributed to the part. Thus on the back they will run in a transverse direction (Fig. 92), whereas on the scalp they will trend to the vertex, and so on.

When these thickened nerves are divided the enlargement will be seen to be due to the presence of a gelatinous tissue, and the appearance of the cut surface reminds one of the umbilical cord. Microscopic examination shows that this thickening is due to overgrowth of the connective tissue of the nerve-sheath, and especially that part of it known as the endoneurium—that is, the delicate connective tissue between the individual fibres of a nerve bundle. The enlargement is by no means uniform,

so that the so-called multiple neuromata are really due to local irregularities in a diffuse overgrowth of the connective tissue of the nerve-sheath. This is shown in Fig. 93, which represents in transverse sections portions of the great occipital nerve of a girl twenty-one years of age affected with a plexiform

Fig. 92.—Plexiform neuroma from the back of a youth aged 19 years. The skin was the seat of a brown hairy mole. (*Bruns.*)

neuroma. The scalp covering the affected nerve was transformed into a brown hairy mole. Widely different opinions are held by equally competent observers in regard to the effects of these changes in the sheath upon the axis-cylinders of the nerves. Some maintain that degeneration occurs, and others that they are not affected. This question requires careful investigation.

The diffuse character of the enlargement in plexiform neuromata is well shown in a remarkable specimen preserved in the Middlesex Hospital Museum (Fig. 94). A man forty-five years of age was admitted into the hospital with well-marked para-

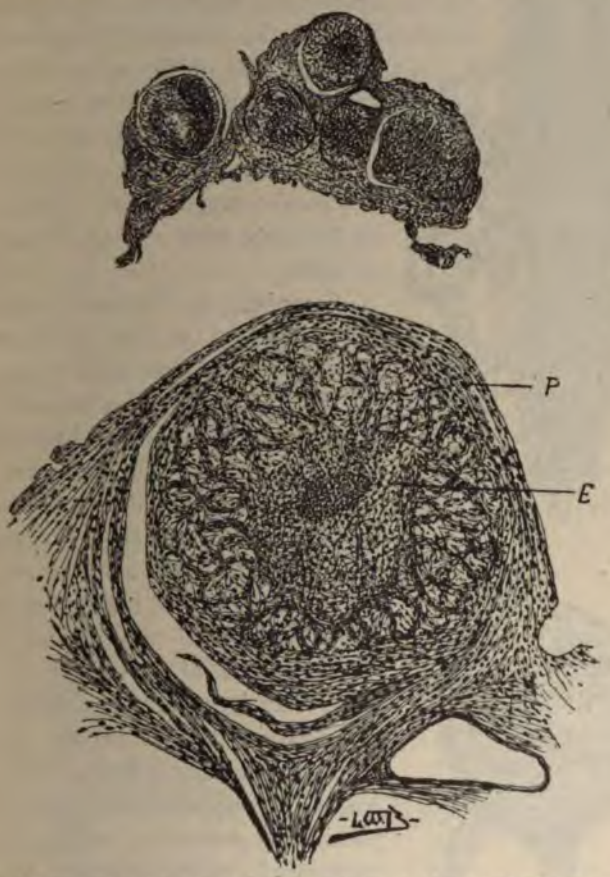

Fig. 93.—Microscopic characters of a nerve from a case of plexiform neuroma affecting the great occipital. The upper figure represents the natural size of the affected nerve. The lower one shows a single nerve strand highly magnified, E. Endoneurium. P. Perineurium.

plegia. At the *post-mortem* examination a large number of small tumours were found on the roots of the nerves. Many of the roots were so beset with these tumours as to resemble strings of beads. In the cervical region there was a tumour as large as a nut, which had compressed the cord and produced

Fig. 94.—Plexiform neuroma affecting the roots of the chorda equina and anterior crural nerve.

paraplegia. There was a large neuroma on the anterior crural nerve, there were smaller examples on the branches of the lumbar plexus. When these nerve roots are carefully examined they present the annulated appearance so characteristic of the root of the ipecacuanha plant, and it is clearly seen that the nerve-roots are thickened throughout, and that the nodosities are local exaggerations. The details of this case were recorded by Sibley* in 1866.

Campbell de Morgan † published the details of a case in which the musculo-spiral nerve and its branches in the forearm were attacked. The patient, a girl of fifteen, had the forearm amputated. The dissected specimen is preserved in the museum of the Middlesex Hospital (Figs. 96 and 97). The musculo-spiral nerve is as thick as the thumb; it looked gelatinous, like an umbilical cord. The cutaneous branches of the nerve are very thick and irregularly nodulated. The microscopic changes in the musculo-spiral nerve are identical with those found in the thickened nerves of a plexiform neuroma underlying the pigmented mother-marks. An interesting feature of this specimen is the large smooth ovoid tumour which occupies the bend of the arm, and is attached to one of the branches of the musculo-spiral nerve, and will bear comparison with the large mass on

* *Med.-Chir. Trans.*, vol. xlix. 39.

† *Trans. Path. Soc.*, vol. xxvi.

the anterior crural nerve in Sibley's case. Any nerve, cranial or spinal, is liable to this form of fibromatosis. In the cranial set the disease shows marked preference for the vagus and the trigeminal.

Fig. 95.—The cervical segment of the cord represented in the preceding figure. A nodule on one of the cervical roots compressed the cord and led to fatal paraplegia.

Shattock * and Abbott have described a case in which the nerves involved included the facial, hypoglossal, the motor part of the fifth and its lingual branch. The enlargement of the lingual and the hypoglossal nerves produced macroglossia. The patient was a child of four years, and it became necessary to excise part of the tongue. It is probable that tumours of the optic nerve are of this nature (see Chap. XVI.).

Alexis Thomson † has shown that the branches of nerves within the muscles also display nodosities, and we know that the sympathetic plays an important part, for the nerves composing the great lateral cords, as well as those belonging to viscera such as the lungs and liver, are thickened and nodose when attacked by this disease.

I have seen a plexiform neuroma of the great occipital

Fig. 96.—Arm in which the musculo-spiral nerve and its branches were transformed into a plexiform neuroma. (*After Campbell de Morgan.*)

underlie a brown hairy mole of the scalp; also one affecting the branches of the anterior tibial nerve distributed to the dorsum of the foot; the overlying skin was brown but hairless.

* *Brit. Med. Journ.*, 1902, vol. ii. 1343.

† "Neuroma and Neuro-fibromatosis," Edinburgh, 1900.

Battle * published the details of a case in which he removed a large molluscum fibrosum from the thigh of a girl aged eighteen. The base of the tumour was occupied by thickened nerves;

Fig. 97.—The arm represented in the preceding figure dissected: the musculo-spiral nerve and its branches are transformed into a plexiform neuroma.

and Frendenwald † has described a plexiform neuroma limited to the upper eyelid of a girl aged sixteen years.

* *Lancet*, 1896, vol. ii. 175.
† *Johns Hopkins Hospital Reports*, 1900, vol. viii.

CHAPTER XVI.

NEUROMATA AND ALLIED CONDITIONS (*continued*).

GLIOMA OF THE BRAIN; OF THE RETINA AND OPTIC NERVE; AND OF THE SPINAL CORD.

Glioma of the Brain.—Ever since I became practically acquainted with the changes in the nerves constituting a plexiform neuroma, it seemed to me that they were akin to the localised neuroglia overgrowth in the brain known as glioma, and I was sufficiently convinced of this to draw attention to the likeness in the first edition of this monograph (1894).

A glioma of the brain occurs as a translucent swelling imperfectly demarcated from the surrounding tissue; the gliomatous tissue may have the consistence of the vitreous, or be as firm as the tissue of the pons. Microscopically it has the characters of an overgrowth of neuroglia.

Virchow pointed out that when a glioma is situated near the surface of the cerebral cortex it appears like a colossal convolution. Should it grow in the tissue of an optic thalamus, this structure will bulge into the third ventricle as though overgrown, and a glioma of the occipital lobe will project into the descending cornu like an additional thalamus. The best illustrations of this indefiniteness, so characteristic of gliomata, come out very strikingly when the pons and the cerebral crura are occupied by this form of tumour.

Gliomata occasionally occur in the pons, and form tumours of considerable size. Sometimes they are confined to one side, and extend into the adjacent cerebellar crura. In a case described by Cayley,* which occurred in a child two years of age, a glioma as large as a walnut occupied the right half of the pons and extended along the superior cerebellar peduncle of that side, reaching as far forward as the corpora quadrigemina. The gliomatous mass formed a prominence on the corresponding

* *Trans. Path. Soc.*, vol. xvi. 23.

half of the floor of the fourth ventricle, and obstructed the Sylvian aqueduct.

In some cases both sides of the pons are involved, and the overgrowth of neuroglia extends forward into the cerebral crura and the cerebellar peduncles, and involves the corpora quadrigemina. In a few it extends downwards into the medulla,

Fig. 98.—Bilateral gliomatous enlargement of the pons and crura cerebri. (*Angel Money.*)

and may even involve the cervical portion of the cord, as in a specimen described by Whipham.*

Sometimes the gliomatous tissue is so abundant as to produce an enlargement of the pons and cerebral peduncles, as represented in Fig. 98.

The appearance of such brains is very peculiar: the basilar artery and its branches appear as though sunk in deep furrows, which cause the parts to resemble "a soft package tightly corded" (Dickinson). Such cases are rare, and in nearly all

* *Trans. Path. Soc.*, vol. xxxii. 8.

instances the patients have been under twelve years of age. Thus the case recorded by Percy Kidd,* occurred in a girl six and a half years old. Gee's † patient was a boy of nine years. In two cases described by Angel Money,‡ one was a boy of eleven years and the other a girl of six and a half years. Goodhart § has described a specimen from a boy aged nine years; Schulz ‖ has observed one in a man of thirty-two years. The relations of a glioma to the surrounding tissues are best seen in recent specimens. On examination soon after death the diseased parts are abnormally large, and on section exhibit a characteristic pale blue colour; in thin sections the tissue has a delicate translucent appearance. The tumour itself is very soft, and imparts to the fingers a sensation like fluctuation. When the parts are immersed in alcohol the tissue becomes firm, opaque, and white; under these conditions it is particularly difficult to determine the limits of the tumour.

Sarcomata of the Optic Nerve.—Tumours of the optic nerve are very rare. A careful analysis of recorded cases does not afford much clear information on the pathologic aspect of these tumours, and they are described under titles such as glioma, myxoma, myxosarcoma, fibroma, and sarcoma.

The recorded clinical facts are sufficient to prove that tumours of connective tissue with malignant characters do arise from and in the optic nerve. They are unilateral, and more frequent in the young than in adults. The greater proportion are met with before the age of twenty, and of these by far the larger proportion occur before the tenth year of life.

The optic nerve is a complex structure, and in the embryo it is preceded by an outgrowth from the brain known as the optic stalk; this is hollow, and consists of epithelial cells. This stalk is ultimately replaced by a fibrous nerve, the nerve elements of which are in part derived from the retina and in part, perhaps, from the brain (Robinson). Thus the early

* *St. Barth. Hosp. Rep.*, vol. xiii. 272.

† *St. Barth. Hosp. Rep.*, vol. xvii. 285.

‡ *Med.-Chir. Trans.*, vol. lxvi. 283.

§ *Trans. Path. Soc.*, vol. xxxvii. 14.

‖ "Neurologisches Centralblatt," 1883, S. 5. This paper contains several references.

tissue of the optic stalk is identical in structure and continuous with the sustentacular tissue of the embryonic retina.

These facts are of importance because in some cases, especially in adults, sarcomata arise from the sheath of the nerve, and do not primarily involve the nerve fibres. Pockley * has excised a tumour from the optic nerve, and saved the nerve and the globe. The patient was a boy of 19 years. The tumour is described as an encapsuled round-celled sarcoma. Some recently recorded cases which have been very carefully investigated point to the conclusion that many of the tumours arising within the sheath of the nerve, especially in children, are particularly connected with the pial sheath, and in construction are closely allied, if not identical, with the retinal (glioma) sarcoma of infancy. The malignancy of optic nerve sarcomata, though pronounced, is not excessive.

Tumours of the optic nerve are usually ovoid in shape, with their long axes coincident with that of the nerve. Their surfaces are usually smooth, and in size they vary greatly, but rarely exceed a pigeon's egg. They do not tend to invade the globe, but they are apt to creep through the optic foramen and involve the intracranial portion of the nerve. As the fibres of the nerve are early implicated, vision is soon interfered with; there is proptosis, but the movements of the eye are free, and there is no pain, even on manipulation.†

Much of the confusion relating to the nomenclature and structure of tumours of the optic nerve is due to their rarity, and those interested in this question will do well to study the careful work of Treacher Collins and Devereux Marshall.‡

Glioma of the Retina.—In structure these tumours mimic the granular layer of the retina, and Treacher Collins § has drawn attention to the great similarity which exists between the cells composing the retina of the fœtus at the third month, when its layers are undifferentiated, and the tissue of a retinal glioma.

This tumour occurs exclusively in children; exceptionally it has been detected at birth, more commonly it makes its

* *Australian Med. Gaz.*, October, 1901.

† Devereux Marshall, *Trans. Ophth. Soc.*, vol. xix.

‡ *Trans. Ophth. Soc.*, vol. xx.

§ "Anatomy and Physiology of the Eye," 1896.

appearance during the first four years of life; it is very rare after the seventh year, and is almost unknown after the age of twelve. In a certain proportion of cases* (20 per cent.) both retinæ are affected, either simultaneously or after a brief interval. This is always an indication that the tumour is highly malignant. In the early stages there is, as a rule, no pain or symptom denoting the presence of a tumour; gradually the pupil dilates, and a peculiar reflex is noticed at the fundus (this is often termed cat's-eye), and, on testing, the eye will be found quite blind. As soon as the existence of a glioma is discovered by the surgeon, the eye is, as a rule, promptly excised. In cases where treatment of this kind is refused or deferred, the following changes occur. The tumour, continuing to increase, pushes forward the intra-ocular structures and induces great pain as the result of the increased intra-ocular pressure it produces, until the cornea yields and the tumour bursts forth, and, growing very rapidly, soon makes its way between the eyelids, which become swollen and everted, and then, in consequence of exposure, assumes a dusky red fleshy appearance, whilst from its surface a sanious fluid exudes which may form crusts on the surface of the tumour. Should the parts become excoriated or handled, they bleed freely. A fungating tumour of this kind will sometimes attain a very large size before it destroys the child's life.

After excision of an eye for retinal sarcoma the disease is very prone to recur, and the recurrent tumour may attain very large proportions before it destroys life. When the operation has been long delayed, the growth may have burst through the sclerotic and invaded the orbital tissues, in a larger proportion of cases it has infiltrated the optic nerve, and it is in this structure that the disease reappears. The frequency with which sarcoma returns in the stump of the optic nerve is, in all probability, due to the intimate lymphatic relations of this nerve with the intra-ocular lymph spaces.

In regard to the question whether "glioma" may "run" in a family, there is little evidence to guide us. Fuchs has recorded a case where two children were affected in one family, and two very extraordinary reports have recently come from

* Lawford and Collins, *Roy. Lond. Ophth. Hosp. Rep.*, vol. xiii. 1.

Australia. Earle Newton * states that in a family of sixteen children ten died from retinal glioma; three of the cases were unilateral and seven bilateral. All the affected children, with one exception, died about the third year. Maher † tells of a family of four children of whom three died of glioma, and in two it was bilateral.

Dissemination of retinal sarcomata is exceptional. The common situations for secondary deposits are the brain, the lymph glands about the jaws, and the periosteum of the skull bones.

The treatment for retinal sarcomata is removal of the eye, and the importance of promptness in this matter is indicated in the careful inquiry conducted by Lawford and Collins. They prove very clearly the following points:—

The quicker an eye is removed after the discovery of the disease, the better the prospect of cure. In the majority of cases the disease returns in the orbit, and in a very small proporportion of cases secondary deposits occur in other parts. When recurrence takes place it is rarely delayed beyond nine months; but one undoubted case has been reported in which the disease returned three years after the primary operation. If three years elapse and there is no recurrence, the recovery may be regarded as permanent. Out of fifty-four cases in Lawford and Collins's list, eight patients were alive and free from recurrence three years after the removal of the eye for retinal glioma: this, in comparison with the inquiries of others, would seem to indicate the proportion of successes. It is significant to note that in seven of these cases the disease affected one eye only. This shows the almost hopeless condition of the patient when both eyes are affected.

Other statistical inquiries have been conducted with the view of obtaining the percentage of cures in this disease, and they work out at about the same proportion as in the paper mentioned above.

Gliomata of the Spinal Cord.—A glioma in the spinal cord is a very rare tumour, and, judging from the scanty records, it would appear that a glioma in the brain is twenty times more

* *Australian Med. Gaz.*, May 20, 1902.

† *Ibid.*, August 20, 1902.

frequent than in the cord. The tumour is imperfectly demarcated from the nervous tissue, and often causes a general enlargement of the cord, producing an effect upon it like gliomatous disease of the pons, crura, and medulla. It was pointed out in connection with this disease of the medulla that it sometimes involves the adjacent segment of the spinal cord.

Reisinger * collected and epitomised the records of nineteen cases of glioma of the spinal cord, and adds a full description of a case which he observed; the report is accompanied by an account of the morbid anatomy of the parts by Prof. Marchand.

The disease may attack any part of the cord, but is most frequent in the cervical enlargement. In a few instances the tumour was seated in the lumbar region. It appears most frequently between the seventeenth and thirtieth years, but it has been observed as late as fifty. Sharkey † has published an interesting account of a spinal glioma which occurred in a man fifty years old, and he uses it to demonstrate the clinical fact that when a tumour arises within the cord, as gliomata always do, it disturbs its functions from the commencement; but, as the nerve substance appears to be elastic, and to allow a good deal of gradual stretching without serious interference with its functions, a tumour may continue to grow for a long time before it produces striking pathologic phenomena. When a tumour grows in the spinal canal outside the cord it may produce but few symptoms until it presses the cord against the resisting walls of the canal; after this has taken place the course of the disease is naturally very rapid, as the cord is quickly flattened by the constantly increasing demands for growing-space which are made by the tumour.

The peculiar relation of the gliomatous tissue to the nerve tissue of the cord precludes any surgical interference.

* Virchow's *Arch.*, xcviii. 369.

† Gulstonian Lectures, 1886.

CHAPTER XVII.

ANGEIOMA, LYMPHANGEIOMA, AND ENDOTHELIOMA.

ANGEIOMATA.

An **angeioma** is a tumour composed of an abnormal formation of blood-vessels.

This genus contains three species: 1, Simple nævus; 2, cavernous nævus; 3, plexiform angeioma.

1. **Simple Nævus.**—This is the most common species of nævus, and in its typical form affects the skin and subcutaneous tissue. A nævus may appear as a superficial discoloration of the skin, and is either a lively pink or a deep blue: these are known as "port-wine stains." Such nævi may involve an area of skin 2 cm. square, or extend over a large portion of the face, or half the trunk, or be restricted to a limb.

A very common variety of nævus is that often referred to as *teleangeiectasis;* it consists of an abnormal collection of arterioles situated in the skin and subcutaneous tissue; it may be present at birth, but much more frequently appears in the course of the first few weeks of life. Sometimes a nævus appears as a red spot no larger than a split pea; then suddenly it grows actively, and in two or three months will involve an area of skin 4 cm. square. When the nævus consists of arterioles it will be of a bright pink colour; when composed mainly of venules it will be of a bluish tint. Lymphatics are often present. Structurally, nævi are composed of minute blood-vessels embedded in fat; usually two or more large vessels establish a communication between the nævus and an adjacent artery or vein. The vessels of the nævus are often sacculated. When gently compressed, the blood is driven from the nævus, which at once loses its colour; but the colour returns as soon as the pressure is relieved.

Simple nævi are common enough in the skin of the face, scalp, neck, and back. They are less frequent on the limbs. They also occur on the labia, the lips, tongue, and conjunctivæ.

Nævi of small size frequently disappear spontaneously; more often they gradually increase in size, and may become converted into cavernous nævi.

2. **Cavernous Nævus.**—This is the species to which the term erectile tumour is most applicable. In structure it is comparable to the spongy tissue characteristic of the cavernous tissue of the penis. Cavernous, like simple nævi are most frequently seen in connection with the skin, where they form distinct tumours of a red or blue colour, rising above the general surface; sometimes they display the peculiar tint so characteristic of fluid contained in thin-walled cysts, for which a cavernous nævus is often mistaken, especially when situated near the outer angle of the orbit. In most cases the blood can by firm and steady pressure be squeezed out of a nævus, but the swelling quickly reappears after the compression is removed. The surface of a nævus may be over-warm, and sometimes the tumour pulsates, the movement being appreciable to the finger, and occasionally perceptible to the eye.

Structurally, cavernous nævi are made up of variously shaped spaces and sinuses, the walls of which are merely fibrous septa, lined with endothelium. Some of these nævi consist in part of vessels and in part of cavernous spaces. When an angeioma consists entirely of irregular blood-containing spaces, a dissection around its periphery will reveal the existence of vessels, sometimes of considerable size, conveying blood to it from adjacent arteries. Cavernous, like simple nævi are, as a rule, congenital, but a nævus which during infancy is small and inconspicuous may later in life become converted into a cavernous nævus of large size, and one that will, under certain conditions, jeopardise life. Very large cavernous nævi have been observed in the breast in the male * as well as the female.†

Cavernous nævi occasionally occur in the **tongue**; as a rule, they are situated near the surface, and form slightly elevated patches of a deep blue or livid colour. Such nævi rarely give rise to any difficulty in diagnosis: their colour, general appearance, and the fact that firm pressure suffices to drive the blood out of the tumour are sufficient to indicate

* Bland-Sutton, *Trans. Clin. Soc.*, vol. xxii. 187.

† Image, *Med.-Chir. Trans.*, vol. xxx. 105.

their nævoid character. Many lingual nævi are congenital, but a fair proportion originate late in life. It must also be borne in mind that a small and inconspicuous nævus may, as years run on, develop almost silently into a dangerous erectile tumour.

In some instances lingual nævi cause very little inconvenience unless they bleed, and this accident may arise at any time, either by abrasion from hard food or from accidental bites, or in consequence of rubbing against jagged teeth. Under such conditions the hæmorrhage is sometimes very alarming, and so oft-repeated that it is in some instances imperative to excise the implicated half of the tongue. Except in the tongue and rectum,* cavernous nævi are very rare in mucous membranes.

Cavernous angeiomata are sometimes found in **voluntary muscles.** Several interesting examples were collected and described by Campbell de Morgan † in 1864.

Examples have been observed and carefully recorded in the following muscles: the semimembranosus, semitendinosus, and the deltoid. The Museum of the Royal College of Surgeons contains an example removed by Stonham from the gracilis.

Rau ‡ has described a cavernous angeioma which occupied the wall of the right auricle; the patient was fifty-six years of age, and the tumours equalled in size a small cherry and occupied the deep layers of the endocardium.

Cavernous angeiomata are of very rare occurrence in the **larynx**; nevertheless they have been observed in this situation, and the careful descriptions of some of the cases place the nature of the tumour beyond doubt. They have been observed springing from the vocal cords,§ the ventricular bands, and from the ventricle. The most striking examples arise in the sinus pyriformis. Usually such tumours are sessile, but are occasionally pedunculated; they may be bright red or purple.

Laryngeal angeiomata may be smooth or nodulated like a mulberry; they are rarely larger than a haricot bean. The colour of these tumours is the most striking clinical feature.

* Barker, *Med.-Chir. Trans.*, vol. lxvi., 229.

† *Brit. and For. Med.-Chir. Review*, 1864, p. 187.

‡ Virchow's *Arch.*, bd. cliii. 22.

§ Percy Kidd, *Trans. Clin. Soc., Lond*, vol. xxv. p. 307.

An extremely rare situation for a cavernous nævus is the **subperitoneal** tissue.*

The **liver** is not an uncommon situation for cavernous nævi of small size. Nævi are not uncommon in the livers of cats and feline mammals in general, but they appear to be harmless tumours.

3. Plexiform Angeiomata.—The species of angeiomata which will be included under this denomination are those usually designated as "aneurisms by anastomosis" or "cirsoid" aneurisms." The former term appears to have been introduced by John Bell, but the expression "aneurism by anastomosis" has come to be used so vaguely that its suppression is a matter of necessity.

A plexiform angeioma consists of a number of abnormal blood-vessels of moderate size arranged parallel to each other, as in the rete mirabile of the fore-limb of the sloth, or the tail of a spider monkey. Such angeiomata may consist of arteries only (arterial retia) or of veins (venous retia) or of arteries and veins in equal proportions (duplex retia). In some the vessels are very tortuous, a disposition more common with arteries than veins. Tortuous vessels are not infrequent in retia for example, the arterial retia in the intercostal spaces beneath the pleura of cetaceans, and the rete in the pituitary fossa of oxen and sheep; and the renal [illegible]

Plexiform angeiomata are very rare [illegible] come under my notice [illegible] teen years of age; the [illegible] a number of arteries as large as [illegible] facial and veins as big as [illegible] resembled that of a [illegible]

Müller* has [illegible] and an account of the [illegible] example of plexiform [illegible] years stated that [illegible] half of the [illegible] increased in size [illegible] [illegible] tumour [illegible]

grew rapidly, but began to "buzz." At the age of twenty the tumour exhibited all the characters of a plexiform angeioma, the pulsation being attended by a whirring sound.

P. Bruns ligatured the right external carotid and the left common and external carotid. The patient became hemiplegic on the second, and died on the third day after the operation. Death was due to embolism and thrombosis of the

Fig. 99.—Dissection of a plexiform angeioma of the forehead. (*After H. Müller.*)

left middle cerebral artery. The parts were injected and dissected; the angular arteries were large and very tortuous (Fig. 99).

Treatment.—This varies with the character of the angeioma; for instance, the diffuse species known as "port-wine staining," when extensive, does not admit of treatment, but a stain of this character the size of a crown-piece may be successfully destroyed by electrolysis when it occurs in a conspicuous situation. The common species of nævus comes under observation almost daily; in such cases it is usual to watch

the child in order to ascertain whether the nævus is growing or not; many nævi disappear, but when they become active and grow, they need prompt treatment. No method is so safe and effectual as excision, whenever it can be carried out, remembering always **to cut the nævus out, not cut into it.** I have excised nævi, simple and cavernous, from the skin over an unclosed fontanelle, the eyelids, the tongue, labium, and other parts of the body in more than one hundred children, and never had the least untoward symptom. It is infinitely preferable to treatment by electrolysis, nitric acid, ethylate of sodium, and the ligature. The chief reason for excising nævi when they evince signs of activity is to prevent them from assuming such proportions as to pass beyond the limits of justifiable surgery. Many examples have been recorded in which a nævoid fleck in an infant has become a formidable tumour in the adult.

It is impossible to advise in regard to the treatment of plexiform angeiomata. Each case exhibits special features which will modify the operation, and the particular method employed will depend on the enterprise, experience, and skill of the surgeon in charge of the case. Several cases of plexiform angeioma of the limbs have been recorded in which it has been necessary to resort to amputation. When the leg is involved this operation is attended with unusual risk to life.

LYMPHANGEIOMATA.

A **lymphangeioma** has the same relation to lymphatics that an angeioma bears to hæmic capillaries.

There are three species of lymphangeiomata:—

(1) Lymphatic nævus; (2) cavernous lymphangeioma; (3) lymphatic cyst.

1. **Lymphatic Nævus.**—This species of lymphangeioma is, as a rule, colourless, but when it contains a fair number of hæmic capillaries, then the nævus appears as a pale pink patch slightly raised above the level of the surrounding skin. When composed entirely of lymphatics it is yellowish-white; when pricked, lymph (sometimes mixed with blood) issues from it. Occasionally several nævi occur in the same individual; they

vary greatly in size—some are as small as shot, others may have a diameter of 2 cm. or more. In many instances they are noticed a few months after birth; occasionally they seem to be acquired. This is probably explained on the ground that during infant life they are small, and their want of colour saves them from detection until their increase in size later in life makes them conspicuous.

Lymphatic nævi may occur in the skin on any part of the trunk or limbs, and have been especially studied in the mucous membrane of the tongue and lips.

In connection with the tongue the affection may be localised to a definite area and give rise to a **lingual lymphangeioma**; this takes the form of a pale pink papilla, or clusters of smooth papillæ, projecting from the mucous membrane. Sometimes one half of the dorsum of the tongue will be beset with small rounded projections. These projections consist of clusters of dilated lymphatic vessels.

There is a very rare disease of the tongue to which the name **macroglossia** is applied. Clinically the condition manifests itself as a congenital enlargement of the tongue implicating mainly its anterior two-thirds. As the child grows the tongue increases so disproportionately that the mouth accommodates it with difficulty, and at last the tip of the organ protrudes from the mouth and, in severe examples, becomes so big as to extend far beyond the margins of the lips. In the case represented in Fig. 100 the large tongue produced great deformity by everting the anterior portion of the mandible and increasing the distance between the teeth lodged in the everted portion.

The increase in the size of the tongue is not due to an overgrowth of its muscular substance, but is caused, as Virchow pointed out, by the formation of a lymphangeioma in connection with the lingual mucous membrane.

Recent observations have shown that there is another cause of macroglossia, namely, plexiform neuroma affecting the lingual and hypoglossal nerves (see p. 147).

2. **Cavernous Lymphangeioma.**—This species in its naked-eye characters resembles a lymphatic nævus, but on microscopical examination it will be found to be identical in

structure with the cavernous nævus, with the difference that its cavities are filled with lymph instead of blood.

Treatment.—This is conducted on the same lines as for angeiomata. In the case of macroglossia, excision of the enlarged and protruding parts of the organ has been followed by permanent good consequences.*

Fig. 100.—Macroglossia in a girl aged 11 years. (*After Humphry.*)

3. **Lymphatic Cyst.**—This appears as a congenital swelling in the neck, axilla, and adjacent parts of the thoracic wall; it was formerly classed under the title "hydrocele of the neck."

Lymphatic cysts are easily recognised. They are always congenital; even at birth they are sometimes of very large size, and exhibit a preference for the anterior triangle. In some instances they extend into the axilla and superior medias-

* Humphry, *Med.-Chir. Trans.*, vol. xxxvi. 113; and Barker, *Trans. Path. Soc.*, vol. xli. 77.

tinum, or project into the posterior triangle (Fig. 101). Their upward limit is, as a rule, indicated by the hyoid bone, but they have been known to reach as high as the parotid gland. The cyst may be unilateral or bilateral; it may consist of a single cavity, or be multilocular, and the various chambers may intercommunicate. In size they vary greatly; some equal a fist, others are bigger than the head of the patient. When the walls of the cyst are thin and the overlying skin is stretched,

Fig. 101.—Lymphatic cyst of the neck in a child two years of age.

the tumour is as translucent as a thin-walled hydrocele of the tunica vaginalis testis.

These cysts originate below the deep cervical fascia, but a portion may make its way through this membrane and become subcutaneous.

Perhaps the most remarkable fact in connection with them is the tendency they exhibit to shrivel and disappear; they are exceptionally liable to inflame, and several cases have been recorded in which the cyst has been ruptured by the child falling upon it. Their proneness to spontaneous cure explains the rarity of such cysts after puberty.

It has been many times observed that the spontaneous

effacement of these cysts is preceded by a sudden increase in their size; they become hot, tender, and pass into a state

Fig. 102.—Child with a lymphatic cyst on the side of the thorax which probably arose in an angeioma.

of inflammation, and as this subsides the cysts slowly disappear.

The walls of lymphatic cysts are often composed of tissue so vascular as to merit the term nævoid; it is probable that some of them have arisen in large cavernous nævi which have been converted into cysts (Fig. 102).

It is important to remember that lymphatics are often very abundant in the ordinary forms of cavernous nævi. It is also a fact of some interest that a lymphatic cyst in the neck and well-marked macroglossia have been observed in the same individual.

ENDOTHELIOMATA.

There is a rare species of tumour, to which attention has been devoted chiefly by German pathologists, which is supposed to arise from the inner walls of blood and lymph vessels. The best examples have been observed in connection with the buccal and nasal mucous membrane and the parotid gland. Such tumours are rarely large, but excessively prone to degeneration; dilated lymphatics are common in them, so that they exhibit an alveolar disposition on section. They are apt to recur (see Chapter XI.).

Those which arise in the gums require careful consideration, for they resemble in their general characters, and even in structure, the cystic epithelial tumours of the jaws described in the chapter on odontomes (page 47).

Tumours of this kind have been observed in the mammary gland; in the skin, especially in association with moles and warts; on the pleura, and the dura mater of the brain and spinal cord.

In addition to malignant tumours arising in lymphatics, there are good reasons to believe that tumours allied to sarcomata arise from the walls of blood-vessels. A remarkable case of this kind was recorded by Griffiths: * the sarcoma probably arose in the wall of the internal jugular vein, invaded its lumen, and then spread and ramified in every direction, extending even into the pulmonary vessels.

There is a rare but remarkable form of sarcoma (angeiosarcoma, Ziegler), which on microscopic examination resembles

* *Trans. Path. Soc.*, vol. xxxix. 311.

Fig. 103.—Microscopic characters of an endothelioma of the gums.

superficially the lobules of the liver (Fig. 104). In this species of tumour the peculiar characters seem to depend upon a cellular overgrowth in the perivascular sheaths of the small vessels.

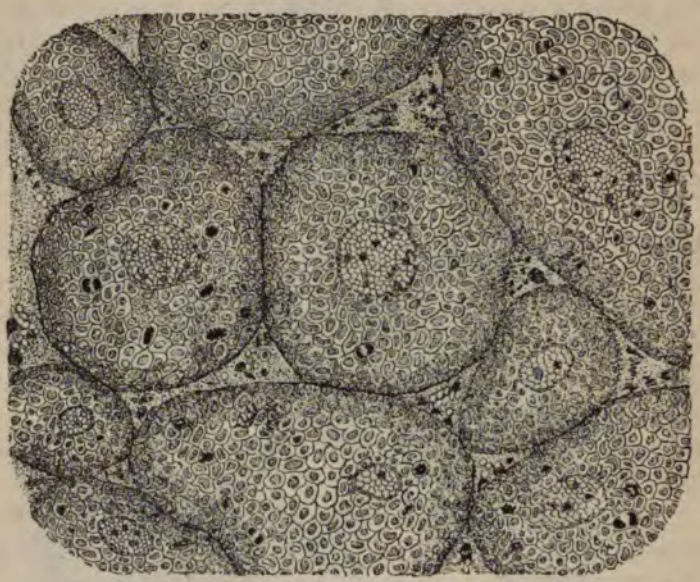

Fig. 104.—Angeiosarcoma of the thyroid gland. (*After Ziegler.*)

The angeiosarcomata have much the same distribution among the organs as the endotheliomata, and are probably of the same nature.

CHAPTER XVIII.

UTERINE FIBROIDS.

THE tumours of the uterus known as fibroids, myomata, or fibro-myomata, are extremely common, and on account of the difficulties and dangers which arise from them directly and indirectly, their pathological and clinical aspects have been studied with very great care. Before minutely describing the structural peculiarities of fibroids, it will be of some advantage to study their topography and gross anatomy. Though fibroids arise in every part of the uterus, including the round ligament, they are more common in the body of the organ than in its neck. Those which arise in the cervix offer peculiar features, and demand separate consideration.

Fibroids of the Body of the Uteurs.—Tumours originating in the uterine walls may be single or multiple. In their early stages they resemble in section knots in a piece of wood. These tumours are distinctly encapsuled, and are firm and even hard to the touch.

For clinical purposes it is convenient to divide them into three sets, according to the part of the uterus in which they arise :—

1. In the true tissue of the uterus : such are termed interstitial or intramural (Fig. 105).
2. In the endometrium : these are said to be submucous.
3. In the layer of muscle tissue subjacent to the peritoneum : these are termed subserous.

Fibroids may arise in and remain confined to any one of these situations, or all the varieties may be seen in the same uterus ; and there is no limit to their number.

It not unfrequently happens that when a fibroid is confined to one wall of the uterus and appears as a single tumour externally, it will be found on section to consist of two or more tumours growing in association, but each possessing its own capsule. Such may be conveniently called **conglomerate**

fibroids. This also holds good of many specimens describ as "general myomatous enlargement of the uterus," in whi this organ is so uniformly enlarged as to resemble an enormo pear.

1. *Interstitial Fibroids.*—This variety may occur singly in multiple. Such tumours in their early stages resemble

Fig. 105.—Uterus in sagittal section to show interstitial and subserous fibroids.

section knots in wood; they have distinct capsules, and firm and even hard to the touch. The bundles of spindle-cell tissue are usually interwoven in such a manner as to present very characteristic whorled appearance. There is no limit their growth, and they sometimes attain a large size, and m weigh upwards of twenty and even thirty kilogrammes.

2. *Submucous Fibroids.*—These tumours arise in the dee parts of the endometrium, and when they attain an apprecia

size project into the cavity of the uterus and give rise to one variety of "fleshy polypus of the womb." Submucous fibromyomata are at first sessile and invested on that surface which projects into the cavity of the uterus with mucous membrane. As they increase in size they dilate the uterine cavity and tend to become pedunculated.

Fig. 106.—Very vascular fibroid in section. (*After Virchow.*)

The presence of the tumour within the uterus acts in the same way as an impregnated ovum, inasmuch as its continued increase in size reacts upon the uterine tissue and leads to great thickening of its walls, accompanied by increased vascularity (Fig. 106), which is often manifested by irregular hæmorrhage from the uterus, or at least by profuse menstruation.

The pedicle of a submucous fibroid may become sufficiently elongated to allow the tumour to pass through the cervical canal into the vagina and even protrude at the vulva. When this happens an interesting change takes place in the epithelium

of the protruded part. So long as the tumour is contained within the cavity of the uterus, the epithelium covering it is indistinguishable from that lining the cavity of the uterus. When the tumour enters the vagina the columnar epithelium stratifies on the protruded surface, but that lining the glandular recesses remains columnar and retains its cilia (Fig. 107).

3. *Subserous Fibroids.*—These arise from the uterine tissues

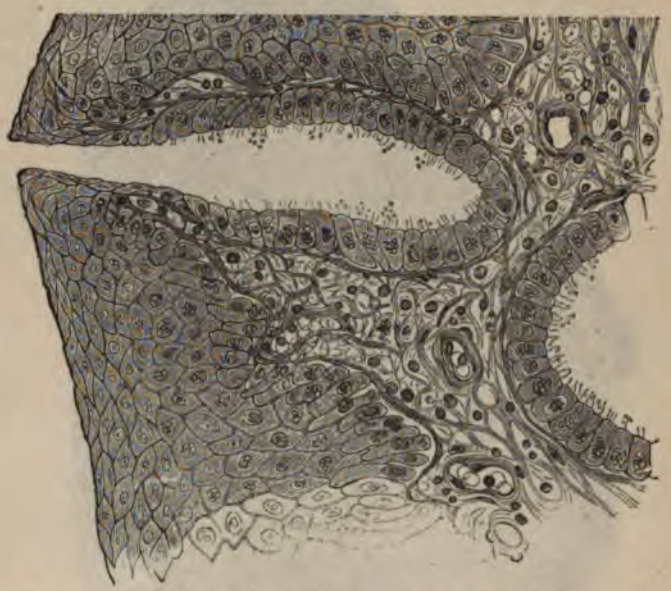

Fig. 107.—Microscopic characters of the epithelium covering the protruded portions of a submucous fibroid: it shows the mutation of columnar ciliated into stratified epithelium as a result of pressure. (*Gervis.*)

subjacent to the peritoneal covering. When numerous, they rarely attain large proportions. When the number is limited to three or four, one or more of them may attain moderate proportions; like the submucous variety, they often become pedunculated, and when numerous they cause the uterus to assume a characteristic tuberous appearance. Sometimes as many as fifteen or twenty of these protuberances may be counted on a uterus, and they vary in size from a pea to a large walnut. In such cases, even when no intramural tumours are present, the walls of the uterus are thicker than natural. Subserous fibroids of this character rarely cause any inconvenience, and

are often found after death in individuals in whom they have never produced the least inconvenience during life, or in whom their presence has not been even suspected. The largest subserous fibroid I have removed weighed sixteen kilogrammes.

Latent Fibroids.—If a number of uteri be examined from women between the twenty-fifth and fiftieth years by the simple means of sectioning them with a knife, in a large proportion of these uteri a number of small rounded bodies resembling knots in wood will appear, their whiteness being in strong contrast with the redness of the surrounding muscle-tissue. These discrete bodies, in many instances no larger than mustard seeds, are fibroids, and are in histologic structure identical with the fully-grown tumours. A uterus may contain ten or more of these small bodies without the least distortion of contour or alteration in its size. These seedling fibroids may never cause trouble, may never pass beyond this stage, and often calcify in old age, but they may at any time grow and become formidable tumours;

A careful consideration of the great frequency of seedling fibroids, and their multiplicity when compared with the number of fibroids which attain a size sufficient to render them clinically appreciable, makes it undeniable that a large proportion of them remain latent. They may be compared to latent buds in trees (knors) and plants, on the ground that they may remain quiescent a number of years and then assume active growth without any known cause.

Latent fibroids have an important practical bearing; it is not an uncommon experience for an operator to dilate the uterine canal and abstract two or more submucous fibroids. However carefully the procedure may be conducted, and however thoroughly the walls of the cavity may be examined for minute fibroids, no honest assurance can be given to the patient that other fibroids will not grow.

The uterus represented in Fig. 108 was removed from a woman 39 years of age. In 1895 she had a subserous fibroid removed, as big as a fœtal head at term. The surgeon stated "that the uterus was normal as to size and consistence, no trace of other growth being discoverable by palpation." Within

five years this patient required hysterectomy for an enlarged uterus reaching to the umbilicus.

From a series of careful observations bearing on this question I have satisfied myself that pregnancy exerts a quickening influence on latent fibroids.

Fibroids of the Neck of the Uterus.—These tumours do not arise so frequently in the neck as in the body of the uterus,

Fig. 108.—A uterus with fibroids seen in sagittal section. The large tumour in the posterior wall was myxomatous and had grown in five years.

but they are fairly frequent, sometimes attain large proportions, and possess peculiar features. When the tumour arises in the cervix and occupies the cervical canal it is called *intracervical.* When it grows from the periphery of the cervix and burrows into the mesometrium it will not expand the cervical canal: this variety may be called a *subserous* cervical fibroid. A typical intracervical fibroid is ovoid, and the fundus of the uterus forms a hillock on its upper pole (Fig. 109).

The topography of a cervix-fibroid is best displayed when the parts are seen in section (Fig. 110), for when divided longi-

tudinally the section always displays an elliptical outline, and the expanded walls of the cervix extend like a thin capsule around it.

The subserous variety of cervix-fibroids sometimes attains a large size, and pushes the uterus high above the pelvic brim: when large, it moulds itself to the true pelvis. The exterior of the large tumours is often tuberose; but, like the intra-

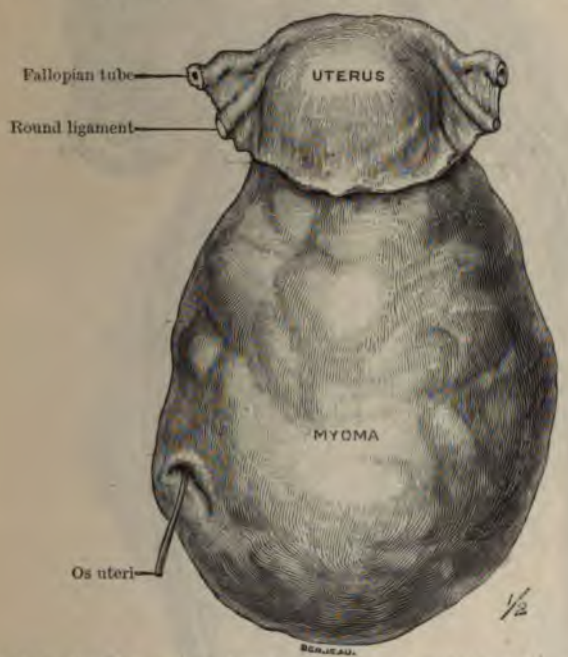

Fig. 109.—An intercervical fibroid from a sterile married woman 40 years of age. The fundus of the uterus reached the level of the umbilicus.

cervical variety, it presents on section a characteristic elliptical outline (Fig. 111).

The ovoid shape of cervix-fibroids is determined by the osseous boundaries of the true pelvis. In a woman with an average pelvis, the pelvic diameters at the level of the middle of the cervix measure—with the soft parts in position—about 10 cm. (4 in.): hence a cervical tumour with this diameter, whether intracervical or subserous, will completely occupy the true pelvis and exert injurious pressure on the urethra and ureters. The smooth, rounded upper pole of intracervical fibroids is due to the moulding effect of the expanded cervix.

Fibroids have been observed growing from the rudimentary horn of a **unicorn uterus.***

Fibroids of the Mesometrium.—The connective tissue

Fig. 110.—An intracervical fibroid in sagittal section.

of the mesometrium (broad ligament) contains a quantity of plain muscle tissue directly continuous with that which underlies the peritoneal investment of the uterus. This muscle

* Routh, *Trans. Obstet. Soc.*, vol. xxix. 2; Doran, *Brit. Med. Journ.*, 1899, vol. i. 1389; Bland-Sutton, *Clinical Journal*, Oct. 23, 1901.

tissue is occasionally the source of tumours identical in structure with uterine fibroids. In the early stages these tumours are ovoid, encapsuled, and often bilateral; they do not cause much inconvenience until they attain the size of cocoanuts; even then they can be easily enucleated. They sometimes grow with great rapidity, and in a few months form tumours

Fig. 111.—A subserous cervical fibroid in sagittal section; from a woman 32 years of age, mother of two children.

weighing as much as ten kilogrammes, and, rising out of the pelvis, carry the uterus and its appendages with them; the relation of these organs to the tumours is shown in Fig. 112.

Some of the large globular tumours of the mesometrium are spindle-celled sarcoma (see p. 74). Doran,* in a recent paper, has contributed some interesting cases and collected the literature, and he points out that they have been observed as early as the twentieth year. The majority occur, according to my observation, after the thirty-fifth year. They are

* *Trans. Obstet. Soc.*, vol. xli. 173.

formidable tumours to deal with, but fortunately they enucleate easily. The largest specimen under my own care weighed thirteen kilogrammes, and was successfully enucleated.*

Fibroids of the Round Ligament of the Uterus.—This structure, like the ovarian ligament, is practically a process of the muscular tissue of the uterus, and tumours in all respects like the fibro-myomata of the uterus arise in this ligament, not only in the segment which lies in relation with the anterior layer of the mesometrium, but also in the terminal portion

Fig. 112.—Bilateral fibroids of the mesometrium.

which traverses the inguinal canal. I have seen tumours of this kind as big as the fist, but their structure was rather that of a spindle-celled sarcoma than of the typical uterine fibroid. Similar tumours have been described as "desmoid," especially those connected with the inguinal portion of the round ligament.

Fibroids of the Ovarian Ligament.—It is no uncommon thing to find a fibroid the size of a cherry in the ovarian ligament, when the uterus itself is occupied by a crowd of fibroids; otherwise it is very rare to find a tumour in this process of the uterus, and especially one large enough to be obvious on clinical examination.

* *Trans. Obstet. Soc.*, vol. xli. 298.

Fibroids of the Utero-sacral Ligament.—Occasionally a fibroid is found burrowing under the posterior layer of the mesometrium and simulating a primary tumour of this structure, but when enucleated it is found attached to the side of the cervix near its junction with the body of the uterus by a very narrow, tendon-like stalk. It is probable that such a fibroid arises in the tissue of the utero-sacral ligament. In two examples under my own care the fibroids had a diameter of 12 cm.

CHAPTER XIX.

UTERINE FIBROIDS (*continued*).

UTERINE fibroids differ much in texture: some are as hard as cartilage, and a few, when calcified, resemble porous stone; others are as soft and succulent as a ripe orange, and occasionally some are equal in consistence to jelly. Between these extremes every degree of hardness or softness occurs, but they

Fig. 113.—Calcified uterine fibroid in section. (*Museum, Middlesex Hospital.*)

all agree in one particular—namely, in the possession of a well-developed capsule, a structure of vital importance to a fibroid, as its life depends upon it. Hard fibroids are yellowish-white on section, softer specimens resemble the normal colour of the uterus. Soft tumours, as a rule, grow quickly, and are very vascular, but the hardest and the gelatinous fibroids are poorly supplied with blood.

It is by no means uncommon to find a uterus possessing many fibroids (twenty or more), some of which are very hard; one or more may be calcified, others are of the same density as the wall of the uterus, whilst one or more are soft and even diffluent.

Attention has already been drawn to the fact that the only

structural feature fibroids have in common is a well-marked capsule, of fibrous tissue, which completely isolates the tumour proper from the uterine tissue. Even in completely calcified fibroids a thin capsule can be demonstrated (Fig. 113), and occasionally the only solid representative of the fibroid is the

Fig. 114.—A sessile subserous fibroid which has undergone extensive mucoid degeneration. From a sterile married woman 37 years of age.

capsule; the originally solid parts of the tumour having slowly liquefied (Fig. 114). Fibroids changed in this way are often referred to as "fibro-cystic" tumours.

The most typical variety of "fibroid" not only resembles the wall of the normal uterus in toughness, but is similar to it in microscopic structure, and consists of unstriped muscle tissue, which has a remarkable tendency to be arranged in whorls (Fig. 115).

The very dense fibroids are composed of tissue which micro-

scopically resembles dense fibrous tissue, with here and there strands of cells resembling unstriped muscle-cells. This variety is often called **fibro-myomata**, and its members display the whorled arrangement in a very striking manner. The fibro-myomata are very liable to calcify. The deposit of earthy

Fig. 115.—The minute structure of a young uterine fibroid: the circular cells are spindle cells cut at right angles. This figure represents a complete section through the equator of a seedling-fibroid the size of a mustard seed.

salts does not take place in an irregular manner, but follows the disposition of the fibres, and the whorled arrangement is easily seen when the sawn surface is examined. When incompletely calcified tumours are macerated, and the decayed tissue washed away, the calcareous matter remains as a coherent skeleton of the tumour. Such changes have taken place whilst the tumour remained in the living uterus; they were formerly termed "uterine calculi." When "calcified fibroids" are

found in coffins, in old burying-grounds, they have been mistaken for vesical calculi.

A subserous fibroid is very prone to calcify, and if its stalk be thin is apt to be twisted, and the tumour may be completely detached and tumble about the pelvis.

The soft, jelly-like fibroids are, in the majority of cases, due

Fig. 116.—Cavities the result of mucoid degeneration in a uterine fibroid. (*Museum, Middlesex Hospital.*)

to secondary (myxomatous) changes in tumours which were originally hard. This is proved by the fact that patches of softening are found in hard tumours, and occasionally fibroids come to hand in which the very hard, calcified, gelatinous and diffluent tissues co-exist (Fig. 116). However, it is important to remember that these changes do not always depend on the age of the tumour, for a very large proportion of uterine fibroids which occur before the thirtieth year are myxomatous, and, what is more important, these soft (almost liquid) fibroids are locally malignant—that is, they recur if enucleated, and this sometimes happens very quickly. In 1898 I removed through the vagina a jelly-like fibroid, as big as an orange, from

the uterus of a woman forty-five years of age, and was careful to remove the whole of the capsule. In six months she returned with a tumour in the uterus occupying the position of the original fibroid, but twice its size. Hysterectomy was carried out, and the uterus found to contain a large myxomatous "fibroid." She has since remained free from recurrence.

It is a fact that women with the hard fibroids rarely complain of ill-health; but when the fibroid is of the jelly-like kind the health undergoes marked deterioration, quite apart from the anæmia due to menorrhagia which may be caused by the tumour.

The consideration of the recurrence of myxomatous fibroids after enucleation leads by natural steps to what is known as "sarcomatous degeneration of fibroids."

A critical examination of the evidence makes it clear that a very large proportion of the cases thus described were examples of infected (septic) fibroids. The most typical example of malignant fibroid which came under my notice occurred in a woman fifty-nine years of age: she had had a fibroid in the uterus fifteen years. It had not caused her inconvenience until shortly before she came under Dr. Finlay's * observation. When she died I made the *post-mortem* examination, and found a pedunculated fibroid, as big as a child's head, attached to the fundus of the uterus: it was adherent to and had penetrated the bladder and intestine. Secondary nodules were found at the base of the right lung, on the wall of the left ventricle of the heart, and in the left kidney. The microscopic characters of the tumour were characteristic of a myoma and a spindle-celled sarcoma. The secondary nodules were identical in structure with the large tumour.

Lymphatics in Fibroids.—It is not uncommon, when removing large uterine fibroids by cœliotomy, to find lymph vessels on the broad ligaments as big as the radial, or even of the size of the axillary vein. Occasionally a firm fibroid will present on section numerous irregular tortuous channels (Fig. 117). These are probably lymph spaces. It has happened to me on several occasions when operating on subserous fibroids to find the tumour adherent to the great omentum, and the

* *Trans. Path. Soc.*, vol. xxxiv. 177.

arteries, veins, and lymphatics in the adherent portions of the omentum were so enormously developed as to form a mixed *rete mirabile;* the arteries being in many instances as big as radials, the veins equal to the cephalic, and the lymphatics of the size of goose-quills. The contrast of the maroon tint of the arteries, the deep blue of the veins, and the light yellow of the thin-walled lymphatics formed an anatomical picture

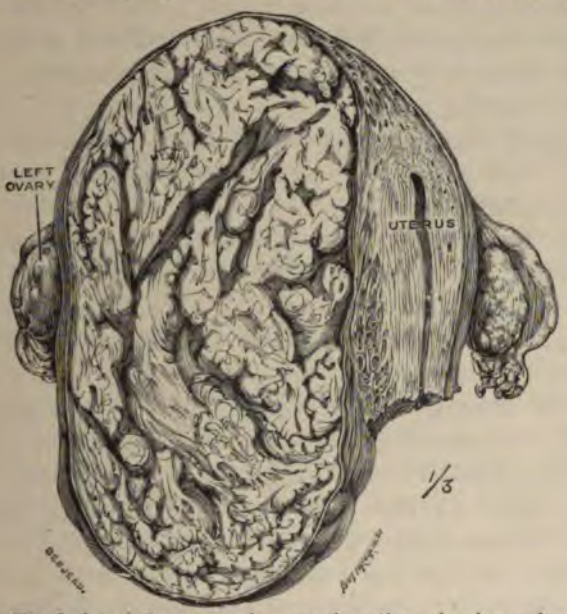

Fig. 117.—The body of the uterus in coronal section, showing a large fibroid traversed by narrow tortuous canals—probably lymph spaces.

scarcely likely to be forgotten by one who has had to deal with such a condition.

The Rate of Growth of Fibroids.—On this subject there are very few facts forthcoming. In general terms it may be stated that soft fibroids grow quickly, the hard ones increase very slowly: those fibroids grow most quickly which soften, and it is a remarkable fact that when the myxomatous change is established in one of these tumours it will often increase in size with astonishing rapidity.

The only observation I have been able to make with any accuracy in regard to the rate of growth of fibroids is the following:—

In 1896 I enucleated by means of an abdominal incision

from the uterus of a woman twenty-three years of age (I obtained a copy of her birth certificate) a fibroid measuring 15 cm. in its major and 5 cm. in its minor axis. The patient, already mother of one child, was delivered of a healthy baby eight months after the operation: it was reasonable to believe that she had become pregnant immediately before coming into the hospital.

Three years later (1899) this woman again came under my care on account of a pelvic tumour: this was watched for three months, and it increased so much that it became necessary to perform hysterectomy. The uterus contained twenty tumours varying in size from a ripe currant to a hen's egg. The largest tumour occupied the cervix. There were no signs of these tumours when the patient was submitted to cœliotomy in June, 1896.

The Nature of Uterine Fibroids.—No very satisfactory explanation of the nature of fibroids is forthcoming, although their structure has been studied with very great care. The large amount of new light which has recently been shed on molluscum fibrosum and neuromata led me to investigate anew the histology of very small fibroids, thinking it quite possible that they might bear the same relation to the nerves of the uterus that the neuromata bear to nerves in other regions of the body. In 1900 I removed a very remarkable uterus from a woman thirty years of age, which, though only about twice the average size, contained one hundred and twenty tumours, some of them the size of a pigeon's egg, but the majority no bigger than mustard seed. Portions of this uterus were carefully prepared for histological examination, but I failed to detect any nerve elements in association with them; in all there was the most intimate association with arteries; indeed, the relation of the arteries to the cell elements of these seedling tumours was such as to convince me that the muscular coats of these vessels are the primary source of "fibroids." *Thus it would appear that some uterine fibroids bear much the same relation to the terminal branches of the uterine arteries that neuromata bear to the epineurium of nerves.*

I have made many efforts to confirm Von Recklinghausen's observations that some fibroids arise in remnants of the Gärtnerian and Wolffian ducts, but so far without success.

CHAPTER XX.

THE MODES IN WHICH FIBROIDS IMPERIL LIFE.

It is too true that fibroids are the commonest of all the species of tumours to which women, whether married, single, fruitful or barren, are liable. It is also a fact that the uterus may contain one fibroid or many and cause neither inconvenience nor suffering—indeed, the individual owning them is ignorant of the existence of a tumour in her womb; but it is equally true that they are often the source of much suffering, and occasionally cause death in insidious ways, some of which will be considered.

Hæmorrhage.—This is the commonest of all the inconveniences which fibroids cause, but it is confined to those which implicate the endometrium. The bleeding occurs under two conditions; most commonly it takes the form of excessive loss at the normal menstrual periods (menorrhagia). The most serious hæmorrhages are associated with septic changes in the tumour. It is a fact of some importance that a small submucous fibroid will induce such profuse bleedings at the menstrual period as to place life in imminent peril, whilst a large interstitial tumour, even though it project into the uterine cavity, scarcely influences the loss.

When a woman with a fibroid bleeds excessively between as well as at the normal menstrual periods, it often indicates that the tumour has become septic.

It is important to realise that oft-repeated losses of blood continued over a long period not only lead to profound anæmia, but also to grave changes in the heart muscle, which frequently end in sudden death, as well as greatly adding to the operative risks when such individuals submit to surgical procedures.

Septic Infection.—This is, perhaps, the most serious complication of a fibroid, and even when it does not cause death is always attended with dangerous consequences. In-

fection of a fibroid may arise in a variety of ways—*e.g.* the extrusion of a submucous tumour into the vagina exposes it to injury, and micro-organisms gain access to it through abrasions in its capsule. Infection may be due to injury from the uterine sound or dirty dilators, or septic changes supervening on labour or miscarriage; occasionally it is due to intestinal gases when bowel adheres to the tumour. An infected fibroid is a soft, dark-coloured, stinking mass, which bleeds freely when touched. In the early stages of the infection it appears on section œdematous, and exhales a sickly odour. On micro-

Fig. 118.—Body of the uterus in section showing two sessile submucous fibroids. The capsule of one has ulcerated and the tumour become gangrenous. The patient suffered from excessive and almost continuous bleeding.

scopic examination the muscle cells are separated by multitudes of inflammatory cells, and colonies of pathogenic micro-organisms can by special methods be demonstrated among the inflammatory cells.

When a large fibroid becomes septic it gives rise to severe constitutional disturbance (septicæmia), like gangrene of other organs, and will, unless promptly removed, inevitably destroy life.

Small fibroids when septic, though they give rise to serious trouble, do not so urgently threaten life, but they work great mischief, for the infection is sure to involve the adjacent endometrium (which sometimes sloughs) and creep into the Fallopian tubes; the septic matter in some cases becomes imprisoned in the tubes by occlusion of the cœlomic ostium;

this is a fortunate event. Occasionally it leaks directly into the peritoneal cavity through an unclosed ostium and establishes fatal peritonitis, as I was able to demonstrate in the case from which the specimen represented in Fig. 120 was obtained.*

An extruded fibroid often becomes septic, for when the tumour passes beyond the external orifice of the uterus, the part lying within the canal is firmly grasped by the uterine walls bounding the internal orifice. Should the tumour be

Fig. 119.—Partial inversion of a uterus due to a fibro-myoma.

very vascular, the venous circulation is interfered with, and the projecting part becomes œdematous. Should the compression continue, the extruded parts become congested, and may even necrose, and as the dead tissue is in a situation easily accessible to air, and consequently to putrefactive organisms, gangrene, with all its attendant evils, is the result.

It is always necessary in examining fibroids projecting into the vagina to be careful to distinguish between the fundus of an inverted uterus and a fibroid extruded from the uterus, and at the same time to remember that a submucous fibroid will occasionally invert the uterus (Fig. 119).

* *Trans. Obstet. Soc.*, vol. xxxii. 171.

Impaction and Its Effects.—A fibroid is said to be impacted (or incarcerated) when it fits the true pelvis so tightly that the tumour cannot rise upwards into the belly. All

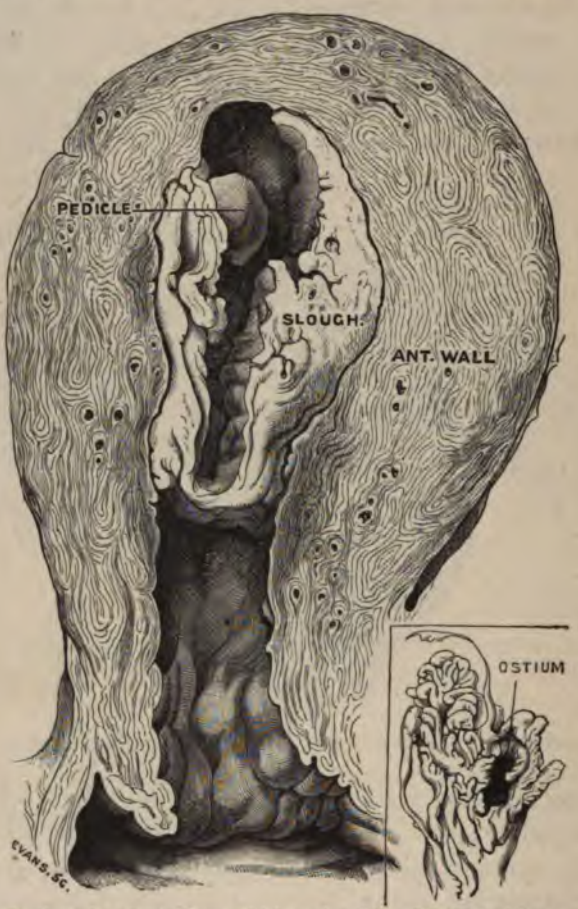

Fig. 120.—Section of a uterus from which a sloughing fibroid had been removed. The mucous membrane was gangrenous, and infective material had leaked into the cœlom through the unclosed ostium.

varieties of fibroids may become impacted, and as the complication is of great clinical importance, it needs detailed consideration.

A subserous fibroid growing from the fundus will often produce retroversion of the uterus, and the tumour occupies the hollow of the sacrum (Fig. 121). As the tumour grows it

appropriates the available pelvic space, and in due course exerts pressure on the rectum and urethra, interfering with defæcation and micturition.

A solitary intramural fibroid may be small enough to rest in the true pelvis without pressing unduly on the urethra or ureters. Presently it increases to such a point that the turgescence which precedes the menstrual flow will cause it to press the urethra against the symphysis, and cause retention of urine. When menstruation occurs the turgidity of the tumour subsides, and the urethra is set free. Frequent recurrence of this pressure permanently damages the bladder and kidneys. Very vascular tumours yield a loud murmur or hum, on auscultation, a sign of very great value in differential diagnosis. In many cases I have been able to demonstrate the existence of a loud murmur for a few days before menstruation, but it disappeared with the flow of blood, and remained in abeyance until a few days before the succeeding period.

Fig. 121.—Uterus in sagittal section: the anterior and posterior walls are each occupied by a fibroid. The posterior one has caused retroflexion of the uterus, and the anterior fibroid projected in the hypogastrium. A small stalked submucous fibroid is lodged in the cavity of the uterus.

The most insidious, and therefore the most dangerous, variety of impaction is that which occurs with cervix-fibroids. It has already been mentioned that when one of these tumours attains a transverse diameter of 10 cm. (4 inches) it has practically used up the spare pelvic space, and exerts injurious pressure on the rectum, ureters, urethra, or bladder. Most commonly it presses on the neck of the bladder and causes

and lead to fatal obstruction. This may happen with small as well as with large tumours. A very large fibroid rising high in the abdomen may rest upon the pelvic brim in such a way as to obstruct the sigmoid flexure. Lastly, an impacted fibroid may press upon the rectum and lead to obstinate constipation and chronic obstruction, with all its inconveniences and evils.

Apart from the various modes already mentioned in which fibroids cause death, they may destroy life in unexpected ways, of which the following is a remarkable and very unusual example recorded by Arnott.* A maiden lady of seventy-two years was knocked down by a large dog, and fell forwards on the pavement. She was seized with severe pain in the belly, and died in thirty-four hours. At the autopsy a circular orifice was found in a coil of ileum which lay between the anterior abdominal wall and a calcified tumour of the uterus. There was extravasation of fæces and intense peritonitis. The tumour, which was as large as a child's head, apparently originated in the anterior wall of the uterus. Several small tumours, also calcified, were attached by pedicles to its capsule.

* *Medico-Chir. Trans.*, vol. xxiii. 199.

CHAPTER XXI.

FIBROIDS IN RELATION TO MENSTRUATION, PREGNANCY, AND THE MENOPAUSE.

THERE is nothing in oncology better established than the fact that all uterine fibroids arise during the menstrual period of

Fig. 123.—Pregnant uterus with multiple fibroids; removed by operation. After the uterus had been removed, an incision was made in the uterine wall, and as *rigor mortis* supervened in the organ, the embryo in its amnion was extruded.

life. In Great Britain this period has an average of thirty years, from the fifteenth to the forty-fifth year. There are,

however, few reliable records of fibroids being found in the uterus before the twentieth year. Submucous fibroids have been removed by cœliotomy from girls of eighteen years (Scharlieb and Madden). Many examples have been observed between the twentieth and the twenty-fifth years.

Between twenty-five and thirty-five, fibroids are fairly common, but the maximum frequency is attained between the thirty-fifth and the forty-fifth years.

The interval between the twenty-fifth and thirty-fifth years is the great child-bearing period, with an average length

Fig. 124.—Gravid uterus with fibroids : removed by operation.

of twelve years. The menstrual epoch of a woman's life may be divided into three periods in relation to pregnancy and fibroids, thus :

1. From fifteen to twenty-five, in which, assuming the environment to be favourable, a woman is infinitely more liable to conceive than to grow a fibroid.

2. From twenty-five to thirty-five ; during this period her liability to pregnancy is greater than in the preceding period, but her liability to fibroids is also greater.

3. From thirty-five to forty-five ; in this the liability to conception is greatly diminished, but to fibroids it is immensely increased.

It is not only true that fibroids arise during menstrual life,

but it is equally certain that they influence menstruation, and I have operated on many cases in which this disagreeable phenomenon has been as profuse between fifty and fifty-five, and even at sixty, as it was at twenty. It is questionable whether the fluxes of blood in women with uterine fibroids after the age of fifty years should be regarded as menstruation in the proper acceptation of the term.

If the conclusion is correct that the interval from twenty-

Fig. 125.—A myomatous gravid uterus in sagittal section. At the beginning of the third month impaction occurred; this was relieved, and as the uterus with its tumours was too long to lie in its natural position, axial rotation occurred. The antero-posterior length of the distorted organ was 20 cm. Only a portion of the large tumour is shown in the figure.

five to thirty-five is the great child-bearing period of a woman's life, it follows as a corollary to the three deductions in the preceding section that, when pregnancy and fibroids co-exist, the subjects of such a combination should be women past thirty, and these should, as a rule, be those who have either married late in life, or, if married early, have remained many years sterile. Two facts may be stated with a fair amount of accuracy thus:

1. When the uterus of a parous woman begins to grow a fibroid, she usually ceases to conceive.

2. When a woman whose uterus contains a fibroid conceives, this event is usually preceded by a long period of unfruitful wedlock. An exception must be made of the solitary subserous fibroid which does not influence conception, though

Fig. 126.—Gravid uterus deformed by fibroids which were soft, red, and one was diffluent. Removed from a woman twenty-eight years of age on account of pain induced by impaction and rotation of the uterus. The arrow lies in the cervical canal (*vide Lancet*, 1902, vol. i., p. 17).

it is occasionally a serious complication of pregnancy as well as of "labour."

Pregnancy not only exerts a quickening influence on fibroids, but it is prone to induce a peculiar alteration in colour and set up degenerate changes. The usual colour of a fibroid is a very pale yellow; in many degenerating fibroids this colour deepens. In pregnancy the fibroid becomes of a deep red or mahogany tint. In the early stages the tumour exhibits

the colour in streaks, but as the pregnancy advances it permeates the whole tumour.

The gravity of the association of fibroids and pregnancy depends largely on the situation of the tumour. The submucous variety is the most, and the stalked subserous kind the least, dangerous. Ovarian tumours have given more trouble to pregnant and parturient women than fibroids, but fibroids have been far more lethal, as they so frequently destroy puerperal women from sepsis.

When a woman with a uterine fibroid conceives, it is certain that her life is in jeopardy, not only so long as the fœtus remains within it, but also when it is expelled, whether this occur prematurely or at the full time. The presence of the tumour not only leads to impaction, but tends to produce abortion; when this occurs the mother may die from hæmorrhage. A submucous fibroid may become septic and slough. A subserous fibroid may become œdematous, and when the uterus empties itself it may inflame and lead to peritonitis or the formation of dangerous adhesions (see p. 185). A cervix-fibroid offers mechanical obstruction to the transit of the fœtus; a submucous fibroid may be driven out in front of the presenting part; more frequently it is extruded subsequently to the delivery of the child. The complete extrusion of a fibroid in this way usually requires from four to six weeks; the peril to life is so great that the majority of women who fall into such straits die unless the aid of surgery be enlisted.

When a woman has a tumour suspected to be a fibroid, and there is reason to believe that it is rapidly increasing, it is worth while to remember—

1. *That she may have conceived, and the enlargement is due to the progress of the pregnancy.*
2. *The tumour may have become septic, or secondary changes may have led to the formation of cyst-like spaces.*
3. *The diagnosis may be erroneous, and the suspected fibroid may be really an ovarian tumour.*
4. *Ovarian tumours and uterine fibroids often co-exist.*
5. *An over-distended bladder has many times been mistaken for a rapidly growing pelvic tumour.*

6. *Hydrosalpinx, pyosalpinx, and even tubal pregnancy sometimes complicate fibroids.*

Even this list does not exhaust the possibilities, for a *myomatous uterus may become impacted in consequence of conception, and when the impaction is relieved axial rotation may occur.*

Fibroids and the Menopause.—It was formerly taught and believed that uterine fibroids cease to be troublesome with the cessation of menstruation. It is quite certain that this opinion requires reconsideration. Uterine fibroids stand alone among tumours in the peculiarity of their age distribution, for, as has already been mentioned, they only arise during menstrual life (15 to 45), but they stand absolutely alone among tumours in possessing another remarkable character: as a rule, they cease to grow after the menopause, and in some instances they undergo a marked diminution in size. Some writers are of opinion that they may disappear. This must be a very exceptional phenomenon, hard to prove and very difficult to believe; therefore, as a concession to superstition, it may be described as an event about as rare as the "advent of a comet."

Though fibroids, as a rule, cease to grow after the menopause, it must not be forgotten that they *sometimes take on unusually rapid growth at this period*; and, apart from this, they are often sources of great peril to life by co-existing with other serious diseases of the uterus, tubes, and ovaries, while the very fact that they are apt to diminish in size is occasionally a source of danger. Apart, however, from these considerations, the fibroids are themselves sources of trouble on account of the degenerate and septic changes to which they are liable. It is also very essential to bear in mind that the existence of a fibroid in the uterus has in a very large proportion of cases a malicious influence in delaying the menopause. The uterus has often been removed from patients between the fiftieth and sixtieth years in whom monthly fluxes of blood were as regular but much more profuse than in women of twenty years. On the other hand, occasionally a woman may have her menopause at the forty-second or forty-fifth year, though a large fibroid is connected with the uterus.

The fact that a fibroid may shrink after the menopause is in itself frequently a source of danger, especially when pedun-

culated, for the tumour may be so big that its size prevents it from tumbling into the pelvis, but after the shrinking consequent on the menopause, such a fibroid may fall into the true pelvis and become impacted. It is a rare complication, but it happens.

The most frequent and dangerous alterations in fibroids after the menopause are necrotic and septic changes. During menstrual life fibroids generally enjoy an abundant blood supply, and in some instances they are almost as vascular as nævi. On the occurrence of the menopause, the cessation of the menstruation is accompanied by a remarkable abatement in the blood supply, and the tumour not only ceases to grow, or even shrinks, but the very fact that its nutritive irrigation, so to speak, is arrested, leads to degenerative changes, and the fibroid becomes in many instances a dead, sequestered body, and so long as septic organisms are denied access it will remain inert. When from various causes putrefactive organisms gain access to these essentially dead tumours, the results are often dire in the extreme.

It is far easier to prove that putrefactive organisms obtain access to dead or dying fibroids than to tell how they get to them. There is, however, one mode of access which is undeniable. The fibroids which give rise to most trouble after the menopause are those of the submucous variety, and there seems a strong tendency, when the uterus passes into its resting stage and the fibroid is shrinking and dying, for the organ to attempt the extrusion of the tumour. A careful study of the cases which have come under my observation teaches me that a fair proportion of troublesome post-menopause fibroids have undergone partial extrusion, or the mouth of the womb is widely dilated and facilitates the ingress of germs.

It has already been pointed out that one of the greatest perils which can happen to a woman with a fibroid in her uterus is to become pregnant, but after the forty-fifth year she is beset with a danger of quite another kind—namely, cancer of the corporeal endometrium. This subject, however, is dealt with in Chap. XXXVI.

Treatment.—All attempts to cure uterine fibroids by medical and electrical methods have been conspicuous failures,

so that those patients needing treatment are obliged to seek the aid of surgery. Small submucous fibroids which are the source of troublesome bleeding can be removed easily and safely through the vagina, but tumours too large to be treated in this way require to be dealt with by means of an incision in the abdominal wall (cœliotomy). By this means pedunculated subserous fibroids may be safely removed after ligature of their pedicles; and large sessile fibroids are occasionally removed by incising their capsules and enucleating them.

For a period of twenty-five years, 1872–1897, it was customary to remove the ovaries in order to anticipate the menopause, with the object of making these tumours shrink. Since I introduced and advocated *conservative hysterectomy*, and insisted that the ovaries are of more importance to a woman than the uterus, oöphorectomy has been abandoned in the treatment of uterine fibroids.

CHAPTER XXII.

OVARIAN FIBROIDS.

In the previous editions of this book regrets were expressed that no reliable evidence was available in regard to solid tumours of the ovary which would enable us to form anything like a satisfactory opinion regarding their innocence or malignancy. Indeed, solid ovarian tumours have been as great a puzzle to the pathologist as to the surgeon, on account of the great difficulty of detecting specific differences in their minute structure, even with all the resources of histological chemistry, which would enable distinctions to be made between a harmless fibroid, a spindle-celled sarcoma, or a myoma.

In the first chapter emphasis was laid on the fact that encapsulation could be depended upon, in a large proportion of cases, as an indication of innocence, and this can be relied on as a conspicuous factor in determining between an ovarian fibroid and a malignant tumour of that gland. Fairbairn * has published a careful paper on "Fibroid Tumour of the Ovary," and has shown that encapsulation can be relied on as a specific character, and reminds us that Virchow drew attention to it in his epoch-making work on Tumours (1867).

In their most typic form ovarian fibroids present easily recognisable characters. They are ovoid and of regular contour, quite smooth, intensely hard, and, as a rule, free from adhesions and unilateral. One pole of the tumour is connected with the ovarian ligament, and if the tumour be bisected in such a way as to include this ligament, a small portion of the normal ovary, amounting in a large fibroid to an infinitesimal portion of the whole tumour mass, will usually be detected associated with the ligament. For example, the specimen represented in Fig. 127 is drawn of natural size, and the remnant of ovary does not offer any great disparity when compared

* *Trans. Obstet. Soc.*, vol. xliv.

with the mass of the fibroid, but when the tumour weighs several pounds the small, bud-like piece of ovary appears very incongruous. A little attention to this relation of tumour, remnant of ovary and ovarian ligament is of importance, as it affords an extremely simple means of recognition. When the tumour is bisected, the cut surface displays the peculiar whorled dis-

Fig. 127.—Ovarian fibroid in longitudinal section (natural size). From a patient 30 years of age. No. 3 in the table on page 206.

position which is such a distinctive feature of the hard uterine fibroid, and it agrees with this species of tumour not only in its microscopic characters, but also in being encapsuled. In small, as well as in tumours of moderate size, it is easy to demonstrate the capsule on any part of its surface. Even in very large examples, in which the capsule has become extremely thin in the parts about the outer pole of the tumour, it is usually quite easily demonstrable around the inner or uterine pole. Fairbairn is careful to point out that although in the typic forms of ovarian fibroid the tumour arises within, and in the majority of cases

remains restricted to and actually encapsuled in, the ovary, no matter what size it attains, yet there are examples which grow within the ovary and project from its surface like subserous fibroids of the uterus. This may be true, and it is probable that some tumours known as corpora fibrosa (Patenko), supposed to arise from corpora lutea, are of this nature.

However much ovarian fibroids may resemble uterine fibroids in possessing definite capsules, and in their gross as well as minute structure, and the extraordinary vortex-like arrangement of the constituent tissues, they differ in a very marked way in their age-distribution. Uterine fibroids only arise during menstrual life, which in its widest sense gives them an age limit of thirty years (15 to 45), but ovarian fibroids arise in advanced life.

Ovarian fibroids sometimes soften, and this leads to the formation of spurious cysts in their substance. Another feature of some importance, and one already mentioned, is their intense hardness; and in some cases this is so obvious that it has enabled me to suspect the nature of the tumour before operation. Calcification had been observed in them, but this is rare; and they are occasionally complicated with hydroperitoneum, and, except in this circumstance, they rarely produce any very obvious impairment of the general health.

Tumours of the ovary described as myomata will require reinvestigation in the light of this additional knowledge; for the present they may be safely included in the same species.

One of the greatest difficulties in connection with our knowledge of the solid tumours of the ovary, especially the variety termed fibroma, has been the absence of information concerning the after-history of cases in which patients have been submitted to operation. This defect has in a very large measure been removed by the publication of these three important papers:—

Doran: "Fibroma of the Ovary; with a Series of After-Histories of Cases."—*Trans. Obstet. Soc.*, vol. xxxviii., 187.

Briggs: "Fibroma of the Ovary."—*Brit. Med. Journal*, 1897, vol. i. 1083.

Fairbairn: "Fibroid Tumour of the Ovary."—*Trans. Obstet. Soc.*, vol. xliv.

My experience is limited to five cases, which are arranged in tabular form :—

No.	Age.	Remote Result.	Reference.
1	66	Well 4 years later	Chelsea Hospital for Women, 1899.
2	27	Well 2½ years later	Fairbairn. *Trans. Obstet. Soc.*, vol. xliv.
3	30	Well 1 year later	*Ibid.*
4	67	Well 1 year later	Chelsea Hospital for Women, 1902.
5	52	Recovered	*Ibid.*, 1903.

McCann * has successfully removed a tumour of this kind from a woman aged 73, and verified her age. She was well four years and a half later.

The earliest age at which these tumours have been observed is the twentieth year. This was a case reported by Doran, † in which the patient married at fifteen, but had borne no children. Previous to the removal of the tumour by Knowsley Thornton (1884) sexual desire appears to have been absent. After recovery this instinct rapidly developed; the patient left her husband, and bore a child to another man. Ultimately she returned to her home in good health.

Ovarian fibroids are easily removed. The results, immediate and remote, are very good.

* *Brit. Med. Journ.*, 1903, vol. i. 127.

† *Trans. Obstet. Soc.*, vol. xxx. 426.

CHAPTER XXIII.

GROUP II.—EPITHELIAL TUMOURS.

In the group now to be considered, epithelium is not only present, but is the essential and distinguishing feature. Epithelium is so disposed in the bodies of complex animals as to serve many functions: in some situations it acts as a protective —*e.g.* the epidermis, where it becomes modified into hair, nail, horn, or into the hardest of all animal tissues—enamel; in others, epithelial cells dip into the underlying connective tissue to form secreting glands; some of them are simple, *e.g.* the tubular glands of the intestine; others are very complex—*e.g.* the liver, mamma, and kidney. Whether a gland is simple or complex, the principle of construction is identical—namely, narrow channels lined with epithelium, resting upon a connective-tissue base, in which blood-vessels, lymphatics, and nerves ramify.

Each epithelial recess of a gland is known as the acinus, and each acinus is in communication with a free surface, either directly by its own duct, as in the case of sebaceous and mucous glands, or indirectly by means of a number of main ducts, as in the case of the mamma; or by a common duct, as in the pancreas. To this rule there are three notable exceptions: the thyroid gland, the pituitary body, and the ovary. It is important to bear in mind the fact that, with the three exceptions mentioned, secreting glands are in direct communication with free surfaces, and are therefore accessible to all kinds of micro-organisms.

The various members of the epithelial group of tumours fall readily into three genera:—1, Papillomata (warts); 2, Adenomata; 3, Carcinomata (cancers).

PAPILLOMATA.

A **papilloma** or **wart** consists of an axis of fibrous tissue, containing blood-vessels, surmounted by epithelium, projecting

from an epithelial surface; it may be simple, and present a uniform surface, or be so covered with secondary processes as to look like a mulberry. When the processes are long the papilloma has a villous appearance.

Warts are most common on the skin, but they also arise from mucous surfaces covered with squamous epithelium. They occur singly or in multiples, and are rarely painful unless irritated, when they are apt to ulcerate and bleed. Crops of warts are often seen on the hands of children. They are common in the region of the anus, vagina, and glans penis when these parts are irritated by foul discharges, especially those of gonorrhœal origin. A curious feature of multiple warts is that they sometimes appear on the hands or scalp almost suddenly, and after persisting many weeks, or perhaps months, disappear as if by magic. When warts are thickly crowded upon a limited area of skin—such, for example, as the glans penis—they are apt to be mistaken for more serious disease, such as warty carcinoma. When warts appear in great number, they are due to local infection by micro-organisms.

Skin warts are overgrown papillæ, and on section the epithelium will be found to pass from one papilla to another in an unbroken line without invading the fibrous framework.

A solitary wart may occur on any skin-covered surface and persist. A wart of this character sometimes attains the size of a walnut, and in some cases is mottled with black pigment. Such warts, late in life, may become the starting-points of melanomata. Occasionally one or two sparse hairs may be detected on a wart, and some fun is made out of this fact by Cressida when her uncle Pandarus says concerning the glabrous chin of Troilus:—

> And she takes upon her to spy a white hair on his chin.

Cressida replies:—

> Alas, poor chin! Many a wart is richer.
>
> Act I. Scene ii.

Solitary warts sometimes grow rapidly, and become so large that they are apt to be mistaken for malignant tumours. They are red, like the comb of a cock, and are smeared with purulent material, and sometimes become abominably fœtid.

Billroth * drew attention to large, rapidly growing tumours of this kind which arose in soft warts of the face, and termed them plexiform sarcomata.

Warts growing from the skin are covered with squamous epithelium, and the surface cells are liable to be transformed into horny material, and form what are called cutaneous horns. Some of these wart-horns have attained almost fabulous dimensions. Thus, the wart-horn, Fig. 128, measured 21 cm., following its greater curve. Horns of this kind are commonly associated with large solitary warts which have existed many years. Warts are by no means uncommon in domesticated animals. They are frequent on the penis of horses and bulls, the lips of lambs, and the pads on the feet of dogs and other Felidæ.

Fig. 128.—Horn which grew from a wart on the cheek of a very old Welsh woman.

Warts similar in structure to those of the skin occur on mucous membranes with a covering of squamous epithelium, such as the lips, buccal aspect of the cheeks, vestibule of the

* "Surgical Pathology," ed. 8, vol. ii. 414. See also McCarthy, *Trans. Path. Soc.*, vol. xxxi. 256; and Bland-Sutton, *ibid.*, vol. xliii. 161.

nose, and the larynx. The œsophagus of the ox is occasionally the seat of a multitude of dendritic warts.

Laryngeal Warts.—In the larynx, warts most commonly spring from the mucous membrane covering the true cords; frequently they grow immediately beneath the cords, and a not uncommon situation is immediately beneath the point of attachment of the vocal cords to the thyroid cartilage. Exceptionally a large mulberry-like wart has been detected growing from the floor of the sinus pyriformis. In number laryngeal

Fig. 129.—Larynx of a child opened posteriorly; it is full of warts. The child died from suffocation.

warts vary greatly. Often one is present; in other cases ten or more will be found. In size there is great difference; some warts are not larger than the head of a pin; they rarely exceed the dimensions of a small cherry, and as a rule they are no bigger than split peas. The warts may be sessile or pedunculated; in the latter case they sometimes possess great mobility, and get nipped between the vocal cords and give rise to urgent dyspnœa, which occasionally ends in suffocation (Fig. 129). In colour they are of a delicate pink, sometimes of a whitish tint resembling that of the healthy cords. Hæmorrhage into their substance causes them to assume a deep red tint.

Laryngeal warts occur in children and in adults. A curious

feature connected with them in children is their disappearance after tracheotomy. This is somewhat similar to the sudden way in which cutaneous warts occasionally vanish.

Intracystic villous papillomata sometimes arise in mammary cysts. The cyst itself in Fig. 130 is formed by the dilatation of a galactophorus duct, and is lined with cubical

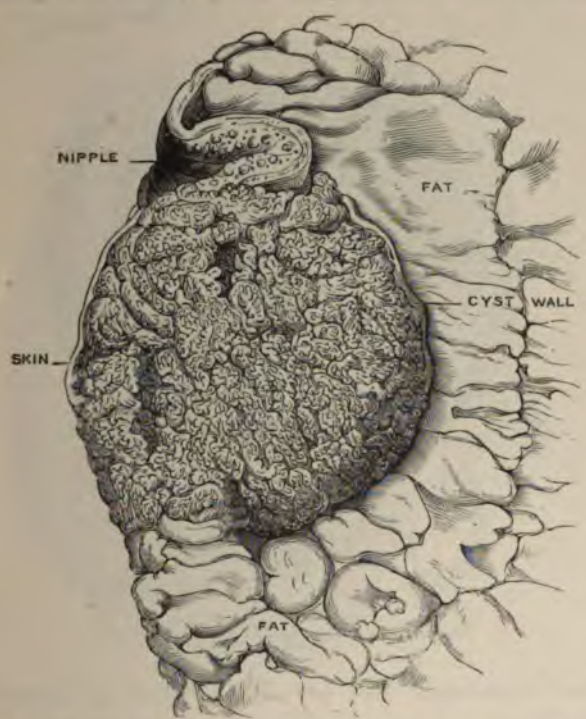

Fig. 130.—Section of a mamma with a dilated duct filled with villous papillomata. (From a woman 68 years of age).

epithelium; from one side of the cyst a villous papilloma has grown, and the processes completely fill and distend its cavity. The processes have exactly the same structure as the villi in vesical papillomata. In this form of intracystic papilloma the analogy to the vesical tumour is further borne out by their liability to hæmorrhage, an abundant discharge of blood-stained fluid from the nipple being a fairly constant clinical feature.

Villous Papillomata. — These grow from the mucous membrane of the bladder, the renal pelvis, and the choroid plexuses of the ventricles of the brain. In the **bladder** the general appearance of the long, branching, feathery tufts recalls in a striking manner the delicate chorionic villi, and when viewed with the cystoscope in the living bladder, they are often exquisite objects. They consist of a connective tissue core

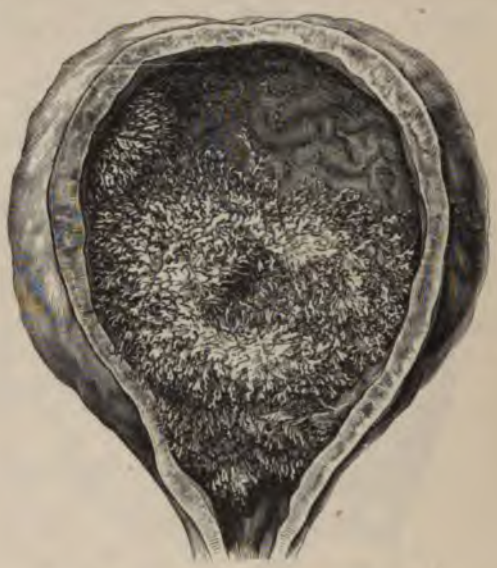

Fig. 131.—Villous papilloma of the bladder.

traversed by delicate blood-vessels, the whole being surmounted by epithelium.

These villous growths sometimes have broad bases, but in other cases the points of attachment are so narrow that the tumours may be described as pedunculated. Usually villous tumours of the bladder occur singly, but two, three, or more may be found in the same bladder. Occasionally there is one large villous tuft with several smaller masses of the size of peas. In some instances they occur at or near the orifice of the ureter, and, though small, the tumour will give rise to serious changes in the corresponding kidney by obstructing the flow of urine from the ureter. When the papilloma is situated near

the neck of the bladder the long villous tufts will sometimes be carried by an overflowing current of urine into the urethral orifice and cause impediment to its free escape (Fig. 131). The delicate character of the villi and their vascularity are sources of danger, because the processes themselves are some-

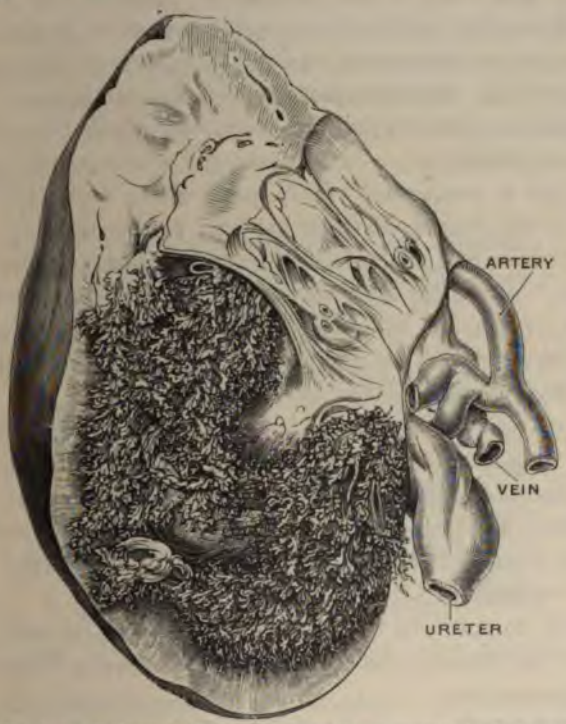

Fig. 132.—Kidney with a villous papilloma growing in its pelvis.

times torn, and the hæmorrhage is occasionally so severe as to place life in great peril.

Villous growths, in every way identical with those found in the bladder, are sometimes found growing from the pelvis of the **kidney** (Fig. 132). In one very striking case of this sort recorded by Dr. Murchison * the pelves of the kidneys of a man sixty-five years of age were found thus occupied, and a singular feature of the case was the presence of two villous tumours in the bladder, one at the orifice of each ureter. It is not

* *Trans. Path. Soc.*, vol. xxi. 241.

improbable, from what we know of the habits of warts generally, that in this exceptional instance the vesical warts were due to transplantations of epithelium from the pelvis of the kidney to the mucous membrane of the bladder.

Villous papilloma of the renal pelvis is a somewhat rare affection, and the subjects are generally past middle life: the condition is often bilateral, and simulates cancer of the kidney.

There is an interesting variety of villous papilloma which arises from the **choroid plexuses** of the cerebral ventricles. These plexuses are fringed with tufts of epithelial-covered villi which occasionally grow luxuriantly and attain a size sufficient to give rise to unpleasant effects, particularly when the choroid plexus of the fourth ventricle behaves in this manner. J. H. Douty * described a case of "villous tumour of the fourth ventricle" in which the tumour was as large as a bantam's egg; it obstructed the interventricular communications and led to distensions of the lateral and third ventricles; the aqueduct of Sylvius was dilated to the size of a quill. The patient was a boy seventeen years old, and the clinical features were such as to permit of accurate localisation of the lesion during life. I had an opportunity of examining this specimen.

Clifford Allbutt,† Ashby,‡ and Bruchanow § have each reported a similar condition in the choroid plexuses of the lateral ventricles.

Villous tumours of the ventricles rarely attain such a size without undergoing calcification and becoming transformed into psammomata.

Psammomata are composed of globular bodies consisting of epithelial cells arranged in layers, usually calcified, and embedded in connective tissue; they are confined exclusively to the pia mater of the brain and spinal cord. In the case of the brain the epithelium is derived from the villous processes of the choroid plexuses of the ventricles; hence psammomata are most frequently found in connection with the velum interpositum, the roof of the fourth ventricle, and those prolonga-

* *Brain*, vol. viii. 409.
† *Trans. Path. Soc.*, vol. xix. 20.
‡ *Ibid.*, vol. xxxvii. 56.
§ *Prag. med. Woch.*, Nov. 24th, 1898.

tions of its choroid plexus which occupy the lateral recesses and come into relation with each cornucopia. The amount of calcareous material in a psammoma is sometimes so abundant that it feels like stone. This earthy matter, not only in composition, but also in its relation to the tissue of the tumour, is identical with that in the pineal body. The earthy matter in psammomata consists largely of cholesterine mixed with layers of epithelium. When exposed to the light it often has a pearl-like appearance. This explains the name cholesteatomata sometimes (but not exclusively) applied to these tumours.

The concentric bodies (Fig. 133) are intimately associated

Fig. 133.—Microscopical appearance of a typical psammoma.

with the blood-vessels of the tumour. A psammoma rarely exceeds in size a shelled walnut, whilst specimens no bigger than peas are very common on the choroid plexuses of the lateral ventricles, and in this situation they are often bilateral; in the third ventricle a psammoma is nearly always single, and this is the case with the fourth ventricle, except when springing from those portions of the plexus which lie in the lateral recesses; they are then apt to be bilateral.

When psammomata occupy the lateral ventricles they will often attain a fair size without giving rise to symptoms, although they produce in some instances deep bays in the substance of the optic thalami.* The situation of the tumour materially

* Eve, *Trans. Path. Soc.*, vol. xxxiii. 14.

influences its effects upon the cerebral functions. Beevor * has described a case in which a psammoma 7·5 cm. by 6 cm. grew from the membranes over the median lobe of the cerebellum in a lad, and caused headache, vomiting, blindness, optic neuritis, priapism, opisthotonos, and other disturbances, ending in death.

The most interesting examples arise from the villi of the choroid plexus in the cornucopia, and are often bilateral (Fig. 134). It is easy to understand that tumours growing in such

Fig 134.—Bilateral psammomata in relation with the lateral recesses of the fourth ventricle. From a man 28 years of age. He was violent, suicidal, blind, and deaf. (*After Strahan.*)†

close relation with important nerves as the trigeminal, facial, vagus, etc., would soon lead to symptoms and surely attract attention, and, as a matter of fact, a large number of examples have been recorded under a variety of names, such as sarcomatous tumours of the fifth and seventh nerves; fibro-sarcomatous tumours of the flocculus; symmetrical tumours of the medulla, and the like. Although fibrous tumours (neuromata) undoubtedly grow from the intracranial portions of the fifth, seventh, and other nerves arising from the medulla oblongata, yet the majority of tumours found in the immediate

* *Brain*, July, 1881

† *Journal of Mental Science*, vol. xxix. 246.

vicinity of the flocculus are psammomata connected with the villi of the choroid plexuses of the fourth ventricle.

Psammomata are fairly common growing from the choroid plexuses of the lateral ventricles of horses (Fig. 135). In this situation they may attain the size of a walnut and not obviously

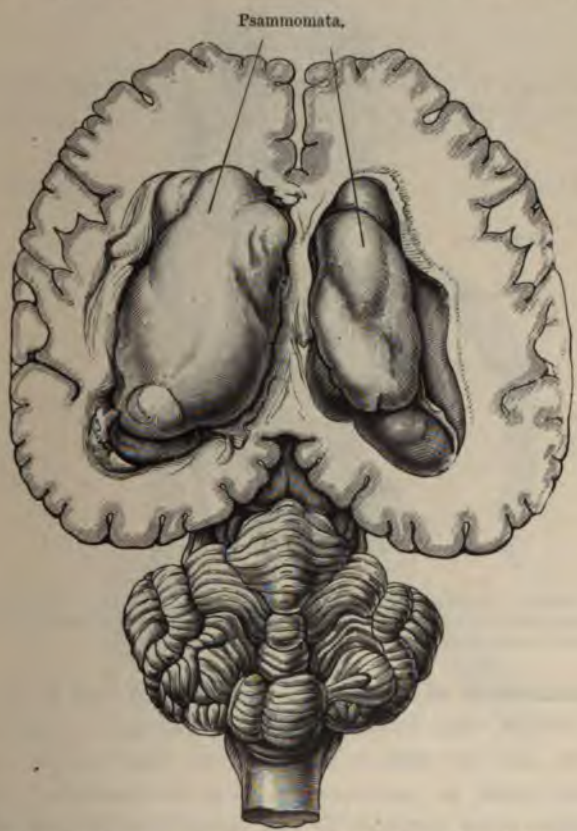

Fig. 135.—Psammomata in the lateral ventricle of a horse's brain.

disturb the function of the organ. Large growths produce grave and even furious symptoms. The pressure effects alone will kill the horse; but in some of the reported cases the animals have destroyed themselves by wild plunges made during attacks of delirium.

Psammomata in horses are very vascular; some of the tumours are soft and contain little grit, while others are quite

hard. Similar variations in the consistence of these tumours occur in the human subject. Every writer on these bodies in the cerebral ventricles of the horse refers to the large amount of cholesterine they contain.

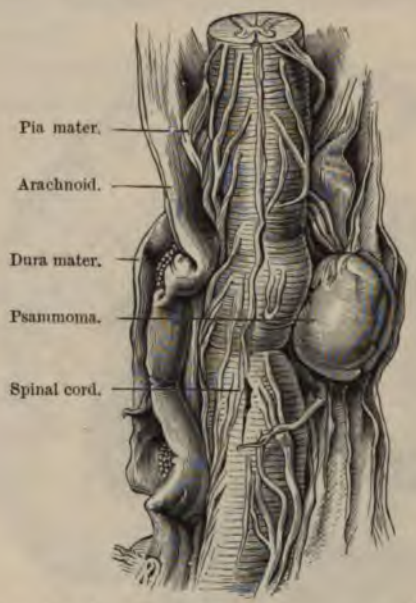

Fig. 136.—Portion of the spinal cord with a psammoma situated at the level of the intervertebral disc between the tenth and eleventh thoracic vertebræ. From a woman 46 years of age. (*Museum, Middlesex Hospital.*)

Psammomata of the spinal membranes lead to far more serious results than tumours of a similar size in the lateral ventricles, and are almost as dangerous when seated high in the spinal canal as psammomata near the flocculus. In the spinal canal these tumours do not attain a large size—indeed, in the few recorded cases there is singular uniformity in their shape and dimensions (Fig. 136).* In recent years these tumours have been successfully removed.

* Cayley, *Trans. Path. Soc.*, vol. xvi. 21; for similar cases see Whipham, *ibid.*, vol. xxiv. 15; Hutchinson, *ibid.*, xxxiii. 23; and Lediard, *ibid.*, xxxiii. 25.

CHAPTER XXIV.

CUTANEOUS HORNS.

Cutaneous horns in the human subject are of four varieties: 1, Sebaceous horn; 2, Wart horn; 3, Cicatrix horn; 4, Nail horn.

1. **Sebaceous horns** are very common, and arise in situa-

Fig. 137.—Cutaneous horn: the widow Dimanche, a "dame aux halles."

tions where sebaceous glands exist. They are formed in consequence of the protrusion of the contents of a sebaceous cyst through a rupture in the cyst wall, or through the duct of the follicle, which becomes desiccated on exposure to the air; fresh material is added to the base of the horn, until at last a horn may be produced measuring in some instances 25 cm.

Sebaceous horns are extremely tough, and present a longitudinal fibrillation; when soaked in a weak solution of liquor

potassæ they quickly soften and the horny material comes away in flakes.

2. A **wart horn** is structurally identical with the sebaceous horn, and it is impossible to decide from an examination of a large horn whether it grew from a sebaceous cyst or from a wart. Sebaceous horns are more frequent on the scalp than elsewhere, whilst wart horns are most frequently found on the penis, and are not rare on the pinna. It is important to bear in mind that carcinoma is apt to originate in the skin around the bases of wart horns, especially in elderly patients.

Fig. 138.—Sebaceous horn in a mouse.

The only means of deciding between a wart horn and a sebaceous horn is by dividing them longitudinally, and ascertaining the existence or otherwise of a cyst at the base of the horns. In the case of the mouse sketched in Fig. 138, some pathologists who examined it were of opinion that it was a wart horn, but on dissection a large sebaceous cyst was found to occupy its base. Horns of this character are not rare in mice, and have been seen on a mouse which lived in a church, and on one which was caught in Westminster Abbey.

The most elaborate collection of cases illustrating cutaneous horns is contained in a small work published by Dr. Hermann Lebert.* He gives accounts of one hundred and nine cases,

* "Ueber Keratose," Breslau, 1864.

with references, the earliest dating from the year 1300. The horns were found on the scalp, temple, forehead, eyelid, nose, lip, cheek, shoulder, arm, elbow, thigh, leg, knee, toe, axilla, thorax, buttock, loin, penis, and scrotum. In length they varied from 1 to 20 cm. Lebert, however, makes no attempt to discriminate between the variety of horns.

The most curious situation in which cutaneous horns occur is in ovarian dermoids, growing from sebaceous cysts in the skin lining the cavities of these tumours. The conversion of epithelium into horn in cases of sebaceous cysts and warts

Fig. 139.—Head of an African rhinoceros with a large wart posterior to and in a line with its nasal horns.

is something more than desiccation from exposure; it is doubtless akin to the change by which nail and horn are formed under normal conditions.

A good physiological type of a wart horn is presented by the nasal horn of the rhinoceros, for this formidable cutaneous appendage is nothing more than a gigantic wart. Professor Flower exhibited at the Zoological Society,* London, a portion of the skin from the head of a rhinoceros (shot by Sir John C. Willoughby † in Central Africa) furnished with three horns. The accessory horn is structurally a wart; it was 12 cm. high and 42 cm. in circumference (Fig. 139).

A physiological type of sebaceous horns is furnished by the

* *Proc. Zool. Soc.*, 1889, 448.

† "East Africa and its Big Game," 1889, 155.

curious patch of spines on the forearm of Hapalemur (*Hapalemur griseus*). It is present only in the adult male. The spines are identical in structure with sebaceous horns, and are formed of hardened secretion furnished by a multitude of glands in the skin immediately underlying the patch of spines. The male ring-tailed lemur (*Lemur catta*) has a curious horn-

Fig. 140.—Head and leg of a thrush with cutaneous horns. The horns were cast each time the bird moulted.

like spur upon its forearm near the wrist, also associated with a collection of glands.*

Cutaneous horns are sometimes found on cows, sheep, and goats. They may attain a large size. The museum of the Royal College of Surgeons contains a very large horn that grew from the flank of a ram. This horn is nearly a metre in length, and in its dried condition is 28 cm. in circumference at the base. This specimen is described, with others, by Sir Everard Home in an interesting paper in the *Phil. Trans.*, 1791. Rabelais

* *Proc. Zool. Soc.*, 1887, 369.

tells us that the mare on which Gargantua rode to Paris had a little horn on her buttock.

Birds are liable to cutaneous horns; they grow very rapidly, and sometimes attain great lengths. It is also a curious fact that they follow the rule with regard to the epidermic structures in this class generally, and are cast off when the birds moult (Fig. 140).

A good physiological type of wart horn among birds is furnished by the American white pelican, *P. trachyrhynchus*.

Fig. 141.—American white pelican *P. trachyrhynchus*. (*From a specimen in the Zoological Gardens, London.*)

The beak of this bird is furnished with a horn structurally resembling the wart horns occasionally seen on other birds. This horn is shed in the autumn, when the pelican moults, and is rapidly reproduced with the feathers. Mr. Spencer F. Baird * states that Mr. Ridgway visited the breeding-ground of these birds on an island in Pyramid Lake, Nevada, and found the pelicans nesting by thousands. Towards the end of the season the ground became so strewn with these shed horns that they could be gathered by the bushel.

3. **Cicatrix horns.**—These are rare, and grow generally

* *Ibis*, 1869, 350.

from the scar left by a burn. These scars, when extensive, are liable to ulcerate and then slowly heal again, but as they heal they become covered with a mass of scales, which sometimes form a horny outgrowth composed of hard desiccated tissue, often laminated like a pie-crust.

Cruveilhier * described a very remarkable example of this kind of horn growing from a hand, probably deformed in consequence of a burn: the horny processes vary from 2 cm. to 20 cm. in length. In reference to this specimen, which formed part of Béclard's collection, he states that similarly shaped horns came under his notice on the thighs of old women at the Salpêtrière; they grew from the scars of old burns caused by chaufferettes. When the horns became detached they left painful ulcers. Later observations show that as these ulcers heal again a new horn forms.

4. **Nail horns** do not call for much consideration. They are extremely common on the toes of bedridden patients, especially old women and those who are dirty. Although nail horns may grow on any of the toes, they are most frequently met with on the big toe. The horns may attain a length of 7 cm., and become twisted so as to resemble rams' horns.

Treatment.—Cutaneous horns are easily detached by a sudden jerk with the thumb and forefinger; if they are too firmly fixed to be removed in this way, then they may be excised. An exceptional case will demand amputation, and in a few instances surgeons have thought it necessary to remove the extremity of the penis when the skin surrounding the base of the horn has been ulcerated. When cancer attacks the skin at the base of a horn, it should, with the surrounding skin, be early and freely excised.

* *Anat. Path.*, pl. vi., livraison vii.; see also Edmunds, *Trans. Path. Soc.*, vol. xxxviii. 352.

CHAPTER XXV.

ADENOMA.

An **adenoma** is a tumour constructed upon the type of, and growing in connection with, a secreting gland.

Adenomata occur as encapsuled tumours in such organs as the mamma and liver, and in glands like the parotid and thyroid; in the mucous membrane of the rectum, intestine, and uterus they are pedunculated. A single adenoma may be present, but two or more may exist in the same gland. In the case of the intestine a score or more may co-exist in the same individual. In size they vary greatly: some are no larger than peas, whereas in the mamma an adenoma will occasionally attain the dimensions of a man's head.

The effects of adenomata depend mainly upon the situations in which they grow. The following statements are true for all:—When completely removed there is no recurrence; they do not infect neighbouring lymph glands, nor give rise to secondary deposits. When an adenoma causes death, it is in consequence of mechanical complications, depending on the situation and size of the tumour.

Although the distinguishing structural peculiarity of an adenoma is the presence of epithelium disposed as in a secreting gland, the connective tissue (stroma) entering into its composition must also be taken into account. In many adenomata the epithelial element is the most conspicuous; in others the connective tissue is out of all proportion to the epithelium, and occasionally preponderates to such a degree that the tumour from some writers receives the misleading name of "adenosarcoma." When the epithelium-lined spaces are distended with fluid, the tumour is termed a cystic adenoma (adenocele). The source of this fluid is of some interest, because adenomata are similar in structure to the gland in which they arise (Fig. 142), yet they are unable to furnish the secretion peculiar to the gland. In the case of adenomata growing from mucous

membrane—*e.g.* the rectal and uterine adenomata—the glandular pits furnish a perverted secretion. This is also true of some forms of prostatic adenomata.

In the case of the thyroid gland, the adenoma is so encapsuled that the secretion furnished by the gland-tissue of the tumour cannot escape, and, slowly accumulating, converts the adenoma into a cyst. This occurs also in the mamma;

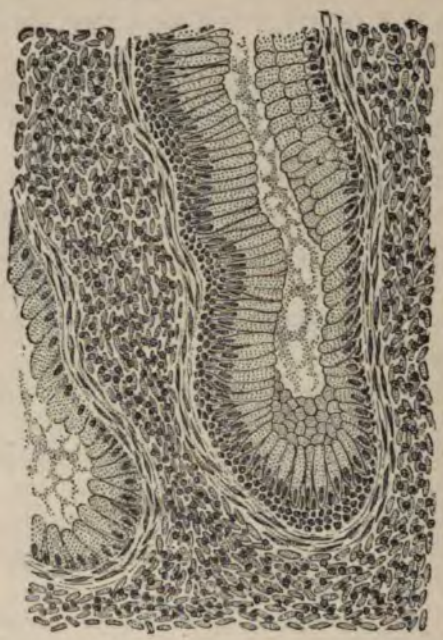

Fig. 142.—Section of an adenoma from a child's rectum. (*Highly magnified.*)

but it will be shown in connection with adenomata of this gland that the fluid sometimes escapes by the natural duct.

Adenomata exhibit peculiar characters, and give rise to disturbances which vary with the gland in which they arise; it will therefore be convenient to consider each variety separately. It will be useful to point out that although adenoma and carcinoma may, and often do, co-exist in the same gland, an adenoma never becomes transformed into cancer (Fig. 8, p. 11).

Adenoma of the Mamma.—There are two varieties of mammary adenoma:—1, **Fibro-adenoma**; 2, **Cystic adenoma.**

1. *Fibro-adenomata.*—These occur as spherical or oval tumours, furnished with capsules, lodged in the superficial parts of mammæ; exceptionally they may be situated deeply in the breast substance. As a rule, they are firm and elastic to the touch, and slip about under the examining finger. It is not rare to find a fibro-adenoma in each mamma, nor is it unusual to find more than one tumour in the same gland. When occupying a superficial position they will, even when small, project the skin so as to cause an irregularity in the contour of the breast; very exceptionally they may be pedunculated.

Fig. 143.—Cystic adenoma with a glandular process. The cyst communicated with a duct in the nipple.

Although the majority of mammary adenomata do not exceed the dimensions of a walnut or of a Tangerine orange, some are as big as cocoanuts.

Structurally they consist of fibrous tissue in which glandular acini are embedded; the tumour itself is isolated from the surrounding gland tissue by a definite capsule.

Tumours of this character are commonly met with in the years succeeding puberty. It is rare to meet with them before

the age of fifteen, but Patteson * has published a careful description of two cases met with in girls of thirteen years. These are probably the two earliest cases yet recorded.

2. *Cystic adenomata.*—As women increase in age, and especially if the breast has an opportunity of fulfilling its function, then adenomata which arise in the gland contain much more epithelium and far less connective tissue. The epithelial cells are larger, and approach in character those of the active

Fig. 144.—Dilated galactophorus duct with intracystic growth.

mamma. Adenomata of this kind form far larger tumours than those to which the term fibro-adenoma is usually applied. Occasionally the glandular acini become dilated with fluid and form cystic spaces; the tumour is then termed a cystic adenoma (or an adenocele). At times a cyst of this kind will retain its communication with the galactophorus duct (Fig. 143), and the secretion will sometimes escape at the nipple. Indeed, it is at times possible, when examining a breast, by gently squeezing the tumour to force a jet of fluid from the cyst. This is a

* *Journal of Anat. and Phys.*, vol. xxvi. 509.

diagnostic sign of great value. It sometimes happens after removal of a large cyst of this kind that a bristle can be passed from the cyst along a galactophorus duct. In some adenomata the cystic portion largely preponderates, the glandular element merely projecting as a bud into the cyst. A sharp distinction, however, must be drawn between a cystic adenoma and a dilatation of a galactophorus duct with intracystic growth (Fig. 144). This variety is closely allied to duct cancer and duct papilloma.

Some of the rarer but larger and more formidable kinds of mammary adenomata are those which combine all the characters of the three preceding varieties. That is, they contain much fibrous tissue, numerous and fairly large cystic spaces, many of which are almost completely occupied by intracystic processes. Mammary tumours of this kind sometimes attain very large proportions, weighing upwards of five or even ten pounds. These tumours have had a variety of denominations, such as sero-cystic tumours, adeno-sarcomata, and so on. However, clinically they are quite innocent, and do not recur after removal.

It is a remarkable thing to remove a large complex adenoma of this kind and to find it completely encapsuled, whilst the breast lies like a small process quite isolated from the tumour.

The description of adenoma of other organs will be found in the succeeding chapters.

CHAPTER XXVI.

CARCINOMA (CANCER).

A CARCINOMA is a malignant tumour arising in epithelium. When the source of the cancer is the epithelium of a gland, it is spoken of as a glandular carcinoma, but when arising from surfaces covered with stratified or squamous epithelium, it is termed squamous-celled cancer.

The microscopic structure of a carcinoma is very simple, and consists of columns of cells, so that when the columns are cut at right angles the section has the appearance of a number of alveolar spaces filled with epithelium (Figs. 145 and 146). The walls of these alveoli are composed of fibrous tissue, presenting various degrees of density, in which blood and lymph vessels ramify. These cell-columns are not always simple, but may branch in various directions and thus produce in some sections very complicated appearances, the softness or hardness of the cancer depending on the amount of fibrous tissue between the columns of cells. This plan of structure underlies all the varieties of malignant epithelial tumours, even those which arise on surfaces covered with squamous epithelium. The cells composing the columns depend upon the character of the epithelium in which the cancer originates, and this feature is so striking that the histologist can often pronounce with certainty the particular gland in which a cancer arose, merely from studying a carefully prepared specimen under the microscope.

Squamous-celled cancer may arise on any surface covered with stratified epithelium, but it is more common in situations where there is a transition from one kind of epithelium to another, and especially where skin and mucous membrane come in relation—*e.g.* the anus, vulva, or the lip.

It may make its appearance as a wart-like growth, more frequently as a small circular ulcer with raised rampart-like edges, or as a fissure, and it is particularly apt to arise on the scrotum of the chimney-sweep.

Although the three clinical varieties of squamous-celled cancer look so different, they are identical in structure. When sections are cut so as to include the margin of the ulcer and underlying tissue, the surface-epithelium will be seen invading it in the form of long, simple, or ramified columns. Weichselbaum has pointed out that the cells composing the columns retain more or less the characters of the epithelium from which they originate. When the cones grow rapidly, the cells become flattened, and some finally cornify (Fig. 145). In this way the so-called epithelial pearls or nests are produced. When lateral pressure is made on a fresh specimen, whitish plugs are forced out; these plugs are the cellular cones.

Fig. 145.-Section of an epithelial cone (*magnified*).

It is important to bear in mind that the three clinical varieties of squamous-celled cancer occur in most of the situations liable to this disease, such as the lips, tongue, cheeks, vulva, and glans penis. This disease is occasionally met with in the urethra, pinna,* and the conjunctiva, especially when this mucous membrane has been injured by lime: its occurrence in relation with a conjunctival scar is interesting, because it sometimes arises at the edges of cicatrices of burns in other parts of the body, and also of lupus scars (Bayha,† Berry‡).

The liability of chronic ulcers of the leg to become cancerous is well known, and the frequency with which leucoplakia of the tongue and long-standing syphilitic ulcers of this organ become cancerous is a well-established fact; the same is true in regard to leucoplakia of the vulva.

The cancerous ulcer, when left to follow its own course, may extend and involve extensive tracts of tissue, or fungate and form huge granulating dendritic masses. In both cases

* Hulke, *Trans. Path. Soc.*, vol. xxvi. 187; Bowlby, *ibid.*, vol. xxxv. 330; Williams, *ibid.*, vol. xxxv. 331.

† Bruns' *Beiträge*, bd. iii. s. i.

‡ *Trans. Path. Soc.*, vol. xlii. 308.

the superficial parts are continually cast off in a foul, fœtid discharge containing sloughs of tissue, cellular detritus, and blood. Vascular tissues, such as skin, muscle, and mucous membrane, are quickly infiltrated and destroyed; even bone is rapidly eroded. Cartilage resists invasion; this is seen in a striking way in those rare instances when cancer attacks the pinna; the skin and soft tissues quickly disappear, whilst its cartilaginous framework stands prominently out amidst the surrounding ruin.

In whatever situation squamous-celled cancer occurs, it destroys life rapidly. The quickness with which it ulcerates and overcomes all resistance enables it to open large blood-vessels should any lie in its way. Hence death from hæmorrhage is frequent; when the cancer is near the air passages, foul material is inspired and initiates septic pneumonia.

Gland Cancer.—This variety arises in the epithelium of secreting glands; it is exceedingly common in some and rare in others, so it will be convenient to discuss the liability of the various glands separately; but the general features of this disease are the same in whatever gland it arises.

A striking feature of cancer is the fact that it is not circumscribed. When examined clinically it is rarely possible to define the limits between the tumour and the surrounding tissues, and this indefiniteness is more obvious when, in the course of an operation, the surgeon cuts into it; but, what is more significant, when the periphery of a cancer is subjected to microscopic scrutiny the searching eye of a competent pathological histologist is unable to discern with accuracy the limitation of the cancerous territory.

This illimitation of cancer constitutes one of the greatest difficulties in dealing with it surgically, for if with the aid of a microscope there is difficulty in defining its limits, it is clear how uncertain the surgeon must be in determining its extent with only fingers and eyes to guide him during an operation. This has led to the practice in recent years of complete extirpation, whenever possible, of cancerous organs. Although a cancer is for a time limited to the gland in which it arises, we have no means of distinguishing with any reasonable certainty, when the individual comes under observation, that the cancer

is limited to the gland, for its outrunners quickly involve surrounding structures, whether skin, fat, mucous membrane, muscle, or bone. When adjacent parts are infiltrated in this way, it is convenient to describe them as being implicated in the cancer. This implication of organs is a grave feature, and a common cause of death, and it is often a bar to operative intervention.

Although cancers, like all epithelial structures, are in free

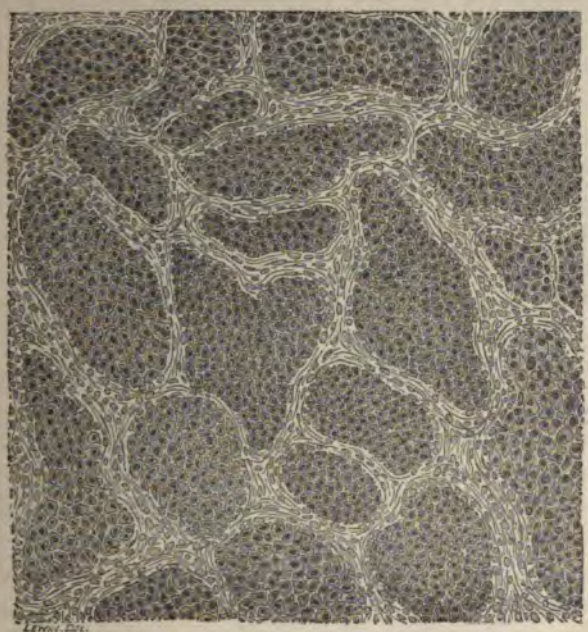

Fig. 146.—Section from a mammary cancer. (*Highly magnified.*)

communication with the lymphatic system, they are poorly supplied with blood; this leads to retrograde changes which it is customary to describe as degeneration. The commonest of these changes is known as colloid degeneration, in which the epithelium in the cell-columns (or alveoli) becomes changed into a structureless material resembling jelly. In many situations, particularly the stomach and the breast, this change occurs so frequently and so extensively that a cancer changed in this way is even now often referred to under the meaningless name of colloid carcinoma.

Infection of Lymph Glands.—The surfaces of our bodies, whether skin or mucous membrane, are rich in lymphatics, and as the secreting glands are primarily derived from these surfaces, it naturally comes about that they are in free communication with the lymphatics and lymph-glands. It follows that the lymphatics involved in the cancerous material convey the cancer elements to the associated lymph-glands, and these may become so surcharged as to burst their capsules. Lymph-glands enlarged in this way sometimes form very large masses, and it is not uncommon to find a primary carcinoma with a diameter of two centimetres associated with a collection of lymph-glands as big as a fist. Lymph-gland infection varies in rapidity and degree; great differences occur not only in regard to cancer of particular organs, but also in relation to the same organ in different individuals. Occasionally lymphatic channels are so stuffed with cancerous material that they may be dissected from the connective tissue and traced to the lymph-gland. Hillier* has described a case in which the thoracic duct was stuffed with cancerous material secondary to cancer of the stomach throughout its length and its lumen completely obliterated. The extent to which lymphatic infection has occurred is a matter which cannot be accurately defined in a given case of carcinoma, and this adds an additional factor of uncertainty in estimating the value of surgical procedure.

The rapidity with which lymph-glands are affected constitutes at the same time the most remarkable and the most dangerous feature of squamous-celled cancer; the size the infected glands attain in many cases is often astonishing, and their enlargement stands in no relation to the size of the initial lesion, for a primary focus 2 cm. square, or less, will lead to the formation of a lymph-gland tumour as big as a cocoanut. Such conditions are most frequently met with when the tongue, lip, and scrotum are the seats of this disease.

This lymph-gland complication is always an element of danger. When the cervical glands are enlarged they interfere with the trachea and œsophagus. They also become firmly

* *Trans. Path Soc.*, vol. liv.; Troisier, *Bull. et Mém. de la Soc. Méd.*, Paris, 1898, p. 455; and Mathieu, p. 827. Also Unger, Virchow's *Arch.*, bd. cxlv. 581.

adherent to the sheaths of big vessels, and as the glands break down the ulceration not unfrequently opens up the jugular vein or carotid artery, and, in the inguinal region, the femoral vessels. A peculiarity of glands infiltrated by carcinoma is the tendency they exhibit to break down in the centre and form spurious cysts. When the skin becomes implicated large portions of the infected glands slough, and leave large, horrible gaps, from which a foul, fœtid fluid issues, whilst the edges of the chasm

Fig. 147.—A mass of secondary cancer in the right ovary successfully removed from a patient aged 43 years. The right breast was removed in 1894 for primary cancer and the left in 1900 for recurrent disease; and the ovarian mass was excised in 1902. Patient was alive and well April, 1903.

produced by the sloughing continue to extend and involve the neighbouring tissues.

Dissemination.—Cancers are exceptionally prone to become disseminated; the secondary growths may make their appearance in any organ or tissue, and not unfrequently in the bones. The cancer particles that give rise to these secondary nodules are transported by lymph and blood-vessels, and when these minute emboli are lodged in suitable situations they

multiply, giving rise to a growth which in its histologic features exactly resembles the parent tumour. So faithful is this reproduction that the nature of the primary tumour can often be correctly inferred from a microscopic examination of a secondary nodule.

The amount of dissemination varies greatly. In some cases secondary deposits will be found only in the liver, whilst in another and apparently identical case, in so far as the structure of the tumour is concerned, secondary knots occur in almost every organ of the body, including the skeleton. In the case of squamous-celled cancer it cannot be said that secondary deposits are rare, but dissemination certainly happens far less frequently, and never so extensively, as in cancer arising in secreting glands. It is also noteworthy that the squamous-celled variety is, in some situations, more liable to disseminate than in others. For example, secondary deposits are rarely met with when this disease attacks the larynx, and the mucous membrane in relation with the mandible or maxillæ, and the œsophagus. The explanation sometimes offered of this peculiarity is that carcinoma in these situations usually runs a rapid course, and often destroys life so quickly that the period is too short to allow of the formation of secondary nodules. This is inadmissible, for in cancer of the scrotum dissemination is almost as exceptional as when the larynx is attacked.

Secondary deposits of cancers are not always so small as merely to merit the name of knots, but form occasionally tumours of some magnitude.

The tumour represented in Fig. 147, which replaced the right ovary, measured in its main diameters 16 cm.; it is a mass of secondary cancer. The primary tumour arose in the right breast.*

The vitality and power of independent growth possessed by minute detached portions of carcinoma is very remarkable. These minute epithelial emigrants not only live and grow, but they reproduce the peculiarity of the primary cancer. It is astonishing to find a secondary cancerous deposit in the humerus with all the characters of the glands of the rectum; a multitude of secondary nodules in the skin with the structural

* *Lancet*, 1902, vol. ii. 1052.

features of gastric glands; nodules in the lungs exactly reproducing that peculiar form of hepatic carcinoma which arises in the biliary ducts; the familiar closed follicles of the thyroid gland reproduced in the body or spinous process of a vertebra; nodules resembling the structure of mammary carcinoma in the ovary, brain, or choroid coat of the eye; and a mass growing from the frontal bone with all the characters of the prostate gland, secondary to cancer of that organ. It is one of the great triumphs of pathological histology that it has demonstrated that carcinoma takes its type of epithelium from the secreting gland in which it arises.

This power of independent growth possessed by the epithelium of cancer is a very dangerous feature, and does not always need blood or lymph vessels for its manifestation. It sometimes happens that an abdominal viscus is attacked by cancer, and a small outgrowth makes its way through the peritoneal covering and bursts, and sheds its cells into the general peritoneal cavity; these are distributed by the peritoneal fluid and the movements of the bowels, and in a few weeks the whole of the serous membrane will be dotted with hundreds, and sometimes thousands, of nodules, each reproducing the type of the parent tumour. This mode of epithelial infection of the peritoneum I have found in cancer of the gall-bladder, ovary, and especially in cancer of the body of the uterus; no form of dissemination gives rise to such innumerable secondary nodules as this, nor demonstrates in a more remarkable way the power of epithelium to engraft itself, to live, and to grow.

Secondary deposits of cancer may occur in any organ and tissue of the body; my own observations teach me that among the malignant epithelial tumours, cancer of the breast and of the pylorus give rise to the widest form of dissemination. Thus it may be stated that cancer is very infectious to the individual affected with cancer, but not to others. The rarest of all tissues in which to find secondary deposits is voluntary muscle, and the rarest of all organs is the heart. Secondary deposits are even met with in the eyeball, and it is a curious fact that the great majority of cases occur in association with mammary cancer, and in one exceptional case both eyeballs contained secondary nodules. Secondary cancer of the globe has also

been observed in connection with carcinoma of the stomach and the thyroid. The chief records have been collected and analysed by Devereux Marshall.*

Very wide dissemination of cancer-emboli, especially when such organs as the eyeball, ovaries, and brain, as well as bones and skin very distant from the primary focus, are the seat of cancer secondary to the breast or stomach, indicates that the cancer elements have obtained an entrance into the systemic circulation.

De Morgan Spots (*Canceroderms* †).—It is not uncommon to find on the skin, especially of the abdomen of patients debilitated by cancer, numbers of small raised red spots looking like nævi. These are often called "De Morgan spots," after Campbell de Morgan,‡ who regarded them as almost pathognomonic of cancer. They are patches of pigment, and not nævi, and though frequent in cancerous patients, are very often present in the non-cancerous after middle life.

Secondary Cancer of the Lung.—The extraordinary frequency with which the lung is infected with malignant disease, whether sarcoma or carcinoma, is owing to the fact that dissemination is due directly to the circulation. In the case of sarcoma the particles gain the circulation entirely through the veins, but in the case of carcinoma, while the cancer-emboli may also enter the blood stream by the veins, the most usual channel is the right lymphatic or the thoracic duct, according to the situation of the primary focus of disease. In this event, of course, the migratory elements are discharged into the innominate veins, and as they are forced into the pulmonary vessels, they become filtered from the blood by the capillaries of the lungs, and after their arrest find in the vascular tissue an excellent soil in which to grow. The relation of the nodules in the lungs to the vessels is of some interest in relation to the corporeal distribution of secondary nodules, because ordinary emboli entering the lungs would be regularly

* *Royal London Ophth. Hosp. Reports*, vol. xiv. 415. See also Rowan, *Trans. Ophth. Soc. of the United Kingdom*, vol. xix. 103; and Hogg, *Australian Med. Journal*, 1899, 283

† Brand, "Ætiology of Cancer," *Brit. Med. Journ.*, 1902, vol. ii.

‡ "Origin of Cancer," 1872.

restrained by the network of small capillaries acting as an efficient filter. However, the secondary nodules sometimes attain considerable size, and may erode and discharge cells into the efferent vessels of the lungs, which gain the left side of the heart, and thus become arterial emboli; in this way they may be transported into bone, brain, skin, eyeball, and indeed into any viscus; in fact, they have a distribution as wide as that of the blood corpuscles.

In discussing secondary deposits in the lungs due to cancer-emboli conveyed by the blood-stream, it must not be forgotten that cancer of adjacent organs, such as the mammary glands, the œsophagus, stomach, etc., may locally invade the pleura and give rise to a widely scattered crop of miliary nodules on the pulmonary pleura. This mode of infection must be distinguished from that in which the lungs are infected by emboli transported by the blood. The pleuræ, however, may be infected by a multitude of discrete nodules, due to a true embolic cancerous nodule protruding through the pleural investment of the lung, its minute cells being distributed throughout the pleural cleft by the lymph, aided by the movements of the parts in respiration.

Cancer Infection.—It has long been known that normal cutaneous epithelium, when accidentally engrafted into the subcutaneous tissue, the cornea, or iris, will live and grow. It has also been demonstrated beyond all cavil that when women have been ovariotomised, especially in cases of large ovarian adenomata, tumours have in some instances subsequently grown in the abdominal cicatrix; these, on microscopic examination, have displayed cysts furnished with the regular large mucin-bearing cells so characteristic of the ovarian adenoma. As these tumours have been unassociated with any recurrence in the pelvis, or secondary nodules in the peritoneum or the viscera, the conclusion is irresistible that they were due to infection of the edges of the abdominal incision in the course of the ovariotomy. These cases are profoundly interesting, because they illustrate what often happens in the course of an operation for the removal of cancer; and it is this local soiling of the wound with minute cancerous particles that constitutes the accident which may be called cancer infection.

A careful study of the clinical aspects of cancer, as well as the most critical inquiry in the post-mortem room, has convinced many that cancer exhibits peculiarities in regard to mode of growth, infection of lymph-glands, dissemination, and the way it destroys life, according to the gland in which it arises. Even this only partly expresses the real truth, for the course of carcinoma of the same gland is not only widely modified by age and constitution, but the same disease in two patients, apparently alike in age and environment, will progress so differently that no surgeon can predict with any reasonable certainty the expectancy of life, result of operation, liability to dissemination, or the chances of recurrence. Therefore, in deciding whether it will be to the patient's advantage to have a cancerous organ extirpated, the surgeon is guided by the known peculiarities of the particular organ affected, the extent to which the adjacent tissues are implicated, the degree to which the associated lymph-glands are infected, and the absence of signs indicating dissemination. In spite of every care, the operation is occasionally followed by such rapid local recurrence that the course of the disease is accelerated rather than retarded.

It is a fact which every surgeon who has had much experience in operating for cancer must have noticed that, in some instances where he has conducted carefully planned but extensive operations for cancer, the patient has had rapid recurrence, and the disease has manifested itself in a manner far worse than when left to run its natural course. This phenomenon, I believe, may be explained. In removing the affected organ the infected lymphatics and blood-vessels stuffed with the cancerous material are divided, and the cancer cells are let loose over the damaged tissues, which they infect, and lead to an extensive outbreak of local cancer. Knowledge of this kind is important, because it leads us to exercise greater care in keeping well wide of the diseased area whilst removing it; and though we cut out the cancer with its implicated lymphatic ducts and infected lymph glands, we should exercise every precaution not to incise the diseased parts, and thus unwittingly scatter the diseased cells over the denuded surfaces.

The Cause of Cancer.—There are many facts indicating that cancer is induced by micro-parasites, for those parts of

the body which are in direct communication with the air, food, water, or intestinal gases are most prone to become cancerous, *e.g.* the mamma, rectum, and stomach; whereas cancer of the prostate and thyroid gland is unusual. Yet the immunity of the mucous membrane of the nasal passages, the naso-pharynx, the trachea, bronchi, and lungs from primary cancer is remarkable; with the exception of the heart, there is no organ in the body which is so rarely occupied by a primary malignant tumour as the lung. In the few cases recorded as primary cancer of the lung there is good ground for the belief that the disease arose in the mucous glands of the bronchi.*

Coats † investigated a tumour of the right lung in a boy of seventeen years; there were secondary nodules in the left lung, the femora, some of the ribs, vertebræ, left ilium, and the liver. Many of the secondary knots were small cysts lined with ciliated epithelium.

The great frequency of cancer in the cervical endometrium in comparison with its infrequency in the corporeal endometrium, and its extreme rarity in the mucous membrane of the Fallopian tube, are also significant facts in relation to invasion by micro-parasites. The greatest difficulty in connection with the micro-parasitic or infective theory as to the origin of cancer is the extraordinary fact that the secondary deposits are structurally identical with the primary tumour independently of the tissues in which they are deposited. This is quite contrary to the behaviour of disseminated foci in such typical micro-parasitic diseases as glanders, actinomycosis, and tuberculosis. Of course, it is possible that in cancer the cell-emboli with the micro-parasite when lodged in foreign tissue multiply in virtue of the presence of the parasite. However, the latter is as yet purely hypothetical. A very significant feature in connection with cancer is the greater liability of diseased organs to become cancerous than those which are thoroughly healthy. This is particularly true of the breast, the uterus and the thyroid gland, the gall bladder, and the tongue.

* Langhans, Virchow's *Arch.*, vol. liii. 470.

† *Trans. Path. Soc.*, vol. xxxix. 326. See also Passler, Virchow's *Arch.*, bd. cxlv. 191.

CHAPTER XXVII.

CARCINOMA OF THE MAMMA (BREAST).

CANCER arises in connection with the glandular elements of the mamma in two situations, namely, in the acini and in the ducts. The former, the most frequent and dangerous, is called *acinous cancer*, and the latter, *duct cancer* of the breast.

1. **Acinous Carcinoma.**—This variety presents much histological diversity, which has led to great confusion in surgical writings. In the most typical form it occurs as a solitary hard tumour, situated at the base of the nipple; but it may occur at any part of the gland, even at its periphery. When the tumour is near the areola it will often induce retraction of the nipple; when situated in other parts of the breast it will lead to dimpling and puckering of the overlying skin.

On section such a tumour has the appearance and consistence of an unripe pear; microscopically, it will be found to consist of columns of epithelial cells, disposed like the lobules of the gland, embedded in dense fibrous tissue. The tumour has no capsule, and fades away indefinitely into the surrounding tissues. When the parts beyond the tumour are examined, isolated collections of cells will often be detected.

In other cases the tumour will be only moderately firm, and on section exhibits a succulent appearance. When microscopically examined it presents alveolar spaces lined with epithelium, here and there raised into irregularly shaped heaps. Such cases are difficult to distinguish from adenomata; but when the sections are attentively examined, parts will be found in which the alveoli are completely filled with irregularly shaped epithelial cells.

In many examples of mammary cancer the tumour, when bisected, appears to the naked eye merely like a tract of cicatricial tissue, and feels as hard as cartilage; when examined microscopically it will be found to consist of strands of fibrous

tissue enclosing here and there a few epithelial cells. This variety is sometimes spoken of as "withering" or contracting cancer: it runs a much slower course than the preceding kinds, and gradually, by its contraction, causes the gland to shrivel, so that at length the patient presents an appearance as if the breast had been removed. Some of these cases have been known to last ten and even fifteen years.

Among unusual forms of cancer of the breast may be classed the rare condition in which it arises in a supernumerary mamma situated in the axilla. The best described example of this we owe to Paul.*

Fig. 148.—Cancerous breast in section: the dotted line indicates the extent to which the nipple and areola have retracted.

Clinical Features.—Acinous cancer of the breast is never manifest before puberty, and is rare before the age of thirty; it is most common between forty and fifty; after fifty it gradually becomes less frequent, and is rare after seventy. I have seen it in a woman ninety years of age.

This variety of breast cancer occurs in the single as well as the married; in the sterile as well as in those who have had many children; in women who have nursed their offspring and in those who have never given suck. It also attacks the male breast. Mammary cancer is one hundred times more frequent in women than in men. Concurrent primary cancer of both breasts is not unknown, but it is an extremely rare event

* *Trans. Path. Soc.*, vol. xlvi. 153.

It is an important and well-established fact that cancer is more prone to attack a breast that has been the seat of previous disease (mastitis) than one that is obviously healthy, and Sir William Mitchell Banks * has recently emphasised the importance of appreciating this fact in regard to successful treatment.

Cancer usually attracts attention as a circumscribed hard lump in the mamma ; it never forms a large tumour—indeed, a mammary cancer rarely exceeds the dimensions of a fist. The rate of growth may be slow, often extremely slow, especially in old individuals. When cancer appears during lactation it progresses with frightful rapidity.

As the tumour increases in size it infiltrates surrounding tissues, becomes adherent to the fascia of the pectoral muscle, and even implicates the muscle. These infiltrated tissues shrink and cause the cancerous breast to become smaller, often much smaller, than its fellow (Fig. 148). The general shrinking of the breast is an important factor in diagnosis, and must not be confounded with *retraction* of the nipple, which is rarely of diagnostic import, as it occurs under a variety of conditions.

Lymph gland infection occurs early in cancer, and is an important clinical sign. The glands of the axilla which run parallel with the free border of the greater pectoral are first affected, but the infection quickly extends to and involves the whole set, and in later stages the glands lying in the posterior triangle of the neck immediately above the clavicle enlarge.

It by no means follows that, because a tumour of the breast is unassociated with large lymph glands, the tumonr is not a cancer. By the time the glands are sensibly enlarged the tumour has made its way towards the surface, and at last the involved skin ulcerates. The advent of ulceration is heralded by a purplish or bluish appearance of the skin, which sometimes resembles a recent cicatrix with veins radiating from it, or the surrounding skin may be dotted with small knots of the size of a split pea or even larger.

After the skin breaks the ulcer tends to spread, and soon assumes the typical appearance of a cancerous ulcer : its edges

* *Medical Society's Trans.*, 1900, vol. xxiii. 146.

are raised and rampart-like, and surround an irregular depression, the floor of which is formed of firm granulations, discharging a foul ichorous or blood-stained fluid.*

Pain.—There is no symptom more variable in mammary cancer than pain. A large proportion of patients experience no painful sensations whatever, and are absolutely ignorant of the presence of any disease in the breast until their attention is arrested by some irregularity in its outline, or some marked difference in the comparative size of the two breasts, or it is accidentally observed by a friend. In some the pain is localised, but in others it radiates from the tumour to the surrounding parts. The pain in mammary cancer is usually a concomitant of the late stages of the disease. Pathology has totally failed to furnish an explanation why, in two patients of about the same age, temperament, and character, each having a tumour in the breast in corresponding situations, and in structure identical, one should suffer anguish too terrible to describe, and the other be absolutely free from pain, and often devoid of any feeling of discomfort.

Concurrently with, but more often subsequently to, infection of the lymph glands, secondary deposits occur in the viscera, especially the liver and lung; but any organ may be the seat of deposit.

When the liver is attacked it enlarges, and there may be hydroperitoneum, rarely jaundice; deposits in the lungs and pleuræ set up pneumonia and pleurisy. When effusions occur in the pleuræ, peritoneum, or pericardium, as a result of cancerous infection, the fluid is often blood-stained.

Secondary deposits in the brain give rise to mental alienation and coma. Deposits in the bones cause "spontaneous" fracture, and when the vertebral column is implicated paraplegia, preceded by acute suffering, is the usual consequence. Enlarged glands and secondary deposits may so involve large vessels and lymphatic trunks in the axilla as to produce solid œdema of the arm.

It must also be remembered that in the late stages of the

* T. W. Nunn, in his work, "On Cancer of the Breast," London, 1882, gives some admirable and life-like illustrations of the various stages of mammary cancer.

disease the tissues covering the thorax may be infiltrated, and this local extension may implicate the ribs and directly infect the pleura.

One of the rarer effects of secondary deposits is when they break out in a great number of small knots over the skin on the front of the chest and both breasts, and induce such induration of the skin that it becomes so rigid as to resemble a firm leather shield, a condition which has earned for it the name of "cancer en cuirasse." In this extreme condition the skin is so firm and hard (pig-skin) that it is impossible to wrinkle it. This peculiar condition is probably due to cancerous invasion of the cutaneous lymphatics.

As the cancer extends locally and ulcerates, and more especially when there is evidence of secondary deposits, the patient's health begins rapidly to decline and the tissues to waste. It is, however, astonishing how women with breasts infiltrated with cancer, or eroded by large and foul ulcers, will sometimes be able to get about and busy themselves with household matters; and this state of things will continue for many months, perhaps until the supervention of pleurisy, pneumonia, or some complication due to the dissemination of the cancer incapacitates them and extinguishes life.

Lymphatic Œdema.—This occasional complication of mammary cancer must be considered, on account of the inconvenience and distress it produces. It is a condition which cannot be mistaken. The œdema usually becomes manifest in the skin about the shoulder, and gradually extends to the skin of the arm, and in due course involves the forearm and hand; the skin covering the scapula is also implicated. The limb in typical cases has a swollen appearance, as though anasarcous; but when the skin is pressed, instead of pitting on pressure it will be found firm, brawny, and unyielding.

The limb grows extremely heavy, and the patient finds it necessary to support it in a sling; exceptionally the weight of the limb prevents the patient from taking walking exercise, and usually produces a moderate degree of lateral curvature of the spine. The connective tissue may be so infiltrated with lymph that the skin becomes so tense as to prevent movement at the wrist, elbow, and shoulder: under such conditions

the arm resembles a wax cast rather than a living limb, and is absolutely useless.

When the tissues of such a limb are examined immediately after death, it will be noticed that the increase in size is due to infiltration of the subcutaneous tissue with lymph, which causes the cut surface to resemble in colour and in texture the pulp of a succulent orange, and large quantities of lymph flow from the incisions. The muscles are smaller than natural and infiltrated with fat. In the character of the fluid which exudes from the limb, and the firmness of the infiltrated connective tissue, it resembles the œdema characteristic of myxœdema.

In the condition we are considering, the obstruction to the lymphatic circulation of the upper limb is due to the pressure of lymph glands infiltrated with cancer, or to secondary nodules lying in the course of the main lymphatic channels at the apex of the axilla. Exceptionally it complicates the rare form of cancerous dissemination known as cuirass cancer.

Lymphatic œdema of the upper limb may supervene in patients with cancerous breasts who have never been submitted to operation, in those in whom the axillary lymph glands were removed when the breasts were amputated, and in those whose axillæ were not interfered with. Many more cases have come under my notice in the right than in the left arm. Pain is experienced in the limb by most of the patients, and it is often very severe. This is due not to the œdema, but to the enlarged glands or cancerous nodules pressing on the cords of the brachial plexus or their branches.

2. **Duct Carcinoma.**—Towards the approach of the menopause the breast enters into a resting stage; its glandular structures atrophy, and nothing but ducts remain.

Breasts in this condition often present on their deep surfaces large numbers of cysts varying in size from a mustard seed to a cherry. These are often called *involution* cysts, and are filled with mucous fluid which causes them to assume a bluish tint when the breast is examined after its removal from the body. The cysts are most abundant on the deep surface of the gland.

Cystic breasts of this kind are most frequently met with between the forty-fifth and fifty-fifth years. In sterile women

they occur somewhat earlier, and, as a rule, both breasts are affected. When cystic disease of this kind is more advanced in one breast than the other, it is apt to be mistaken for diffuse cancer. This variety of cystic disease is often accompanied with pain. Cystic mammary glands of this character require attentive study, because the walls of the dilated ducts are occasionally the starting points of cancer. In rare instances villous processes, or papillomata, sprout from the walls of such cysts, particularly when the cysts represent dilated lacteal sinuses.

When cancer arises in dilated mammary ducts it is now customary to speak of it as **duct cancer**. This variety occurs most frequently in the terminal ducts, and especially in the ampullæ (lacteal sinuses), usually as a single tumour; occasionally several isolated nodules are present in the same gland. The tumour is in some cases no larger than a walnut, but may be as big as a child's fist. When situated near the skin it assumes a deep red or even purple colour.

Seen in section, the cancer will be found provided with a distinct capsule (the dilated duct), whilst the mass within projects as a soft red outgrowth from the cyst wall; sometimes this is so large as completely to occupy the cavity. When this intracystic growth is examined microscopically it will be found to consist of glandular spaces lined with regular columnar or subcolumnar epithelium. Sometimes the intracystic mass takes the form of villous processes, like those met with in the bladder. Such is termed **duct papilloma** (Fig. 130, p. 211).

Clinical Features.—Duct papilloma and duct cancer appear most frequently between the ages of thirty-five and sixty-five. The tumour is always softer than in the common, or acinous, variety. When seated near the skin it assumes a dark red or even purple tint, and has even been mistaken for a melanoma. The nipple is not retracted, but may be inverted. This is, however, a sign of no value. In a very large proportion of cases there is an abundant discharge of blood-stained fluid from the nipple. The tumour grows very slowly, rarely implicates the lymph glands, and exhibits very little tendency to recur or to become disseminated. It is the least malignant variety of mammary cancer.

Treatment.—With our present knowledge, the only method of treatment which offers any hopeful prospect to individuals affected with mammary cancer is *early and thorough removal of the whole mamma with the pectoral fascia, the lymphatics and axillary lymph glands.* Unfortunately, the chief difficulty the surgeon finds in recommending this very clumsy though appropriate remedy arises from the circumstance that patients so often conceal the fact that they have a tumour until compelled by pain, discomfort, and often actual misery, induced by ulceration and sloughing of the cancer, to seek advice. There is, of course, a small proportion of women who absolutely refuse to submit to operation in the early hopeful stages, and wait until the skin becomes involved before they realise their unfortunate condition. When the tumour has been allowed to run its course and infect the axillary lymph glands or ulcerate, the chance of doing good by operation is seriously diminished.

Careful observations show clearly enough that those patients do best who have the cancerous mamma extirpated at the earliest possible date after the tumour is perceived. There is a consensus of opinion among surgeons who have had the largest experience in cancer that when a patient comes under observation with a nodule in the mamma which it is reasonable to regard as cancerous, it is the duty of the medical attendant to advise the removal of the breast. It is, however, a remarkable fact that mammary tumours, innocent and malignant, have been subject to observation for centuries, yet there is no organ in the body in which tumours give rise to more doubt or difficulty in diagnosis than in the mamma. This is so generally recognised that it is the duty of every surgeon, before amputating a breast, to make an incision into the swelling, in order to assure himself that he is really dealing with a malignant tumour and not a simple cyst, abscess, or localised inflammation.

The most favourable cases are those in which the cancer is limited to the breast, does not involve the skin, and has not produced any appreciable enlargement of the axillary lymph glands. In such a case the removal of the whole breast, with the lymphatics and lymph glands, is a proceeding which, if properly carried out, is devoid of operative risks: recurrence

or dissemination is indefinitely delayed, and the patient may enjoy many years (five, ten, or even fifteen) of useful life.

When the cancer has been allowed to implicate the skin, or has ulcerated, and there is extensive infection of the lymph glands, then very wide removal of the tissues is imperative. This necessarily adds to the risks of the operation; and though in many instances patients have allowed the disease to advance in this way before coming to the surgeon, yet a fair proportion enjoy some years of immunity from recurrence, but their expectancy of life is not great. The difficulty the surgeon has to contend with in this stage is the uncertainty of the presence of secondary nodules in the viscera.

When cancer of the breast extensively involves the skin and has ulcerated deeply—and especially if it implicates the pectoral muscle and chest wall—then operation is useless.

Although it is extremely difficult to indicate even approximate rules as to the advisability, or otherwise, of operating in certain conditions of mammary cancer, there are cases in which it can be definitely laid down that operations are useless. For instance:—

1. When the supraclavicular lymph glands are infected, whether the cancer has ulcerated or not; such extensive infection of lymph glands indicates a high degree of malignancy.
2. When a large area of skin is implicated, and particularly in cases where it is brawny or beset with small nodules (cuirass cancer).
3. In no case where there is reason to believe that dissemination has occurred.

The variety known as duct cancer gives the best results to operation, for in typical forms recurrence and dissemination are very rare, and even when these events occur their manifestation is long delayed.

Perhaps one of the most extraordinary facts connected with mammary cancer is this:—Two patients may have their breasts removed for cancer; they may be alike in age, habit of body, and circumstances; the tumours may be alike as far as eyes, fingers, and microscopes can determine; the operations may be conducted by the same surgeon and by the same method,

yet one patient may die in a few months with wide dissemination, and the other may be spared ten or even fifteen years. Herein lies all our difficulty, for the surgeon, however wide his experience, cannot forecast from the clinical character of the tumour the future of his patient; neither can the morbid histologist predict the course of the case. Even when a competent knowledge of surgery and pathology has been combined in an individual operator, he rarely ventures to prophesy. It may be truly said that some cases for which surgery seemed to promise much have been tragic failures, and that some which seemed almost hopeless have given admirable results after operation. This state of things is not due to any supineness on the part of pathologists, for, as Rindfleisch has pertinently written: "The tumours of the female mammary gland have been so often, and already at so early a period, the subject of earnest histological investigation that in this sense we might not improperly call the mammary gland the nurse of pathological histology."

It has already been mentioned that cancer rarely attacks both breasts; it, however, occasionally happens that, after one breast has been removed for cancer, the disease appears in the other.

Recurrence.—It is now clearly established that local recurrence after removal of a cancerous breast is due to two causes, namely, incomplete removal and cancer-infection. In respect to imperfect operations, Sir Benjamin Brodie, many years ago, wrote in regard to the removal of the whole breast:—"You may imagine this is a very easy thing to be done, but it is not so easy in reality; for in amputating the breast you will be very apt, in a thin person, if you are not very careful, to leave small slices of the gland of the breast adherent to the skin, and I have no doubt that the part or parts thus left behind in some cases have formed the nidus of future disease." We now know this is perfectly true. I have, in several instances, carefully examined microscopically small recurrent nodules, and found them associated with small fragments of gland tissue. A more serious form of recurrence is due to insufficient removal of the overlying skin: in this event, after the wound has healed, the skin around the cicatrix is often slowly converted into a hard, brawny plaque.

Sometimes the surgeon removes a cancerous breast, takes every care to keep wide of the tumour in making the skin incision, dissects out the gland tissue, removes the major and minor pectorals, and clears the lymph glands, with the surrounding fat, from the axilla. He closes the wounds, and congratulates himself on the completeness of the operation. Occasionally his industry is rewarded, but now and then these extensive enterprises are followed by rapid and wide recurrences, which often take the form of infiltration of the skin raised in the operation and the underlying chest wall. This dire result is due to the distribution of cancer cells in the course of the operation; in short, to **cancer-infection.** This mode of infection is sometimes announced along the edges of the cicatrix, many of the holes made by the needles in the suture of the flaps being indicated by nodules which are due to infection of the skin. The lymphatic channels running from a cancerous mammary gland are sometimes so stuffed with cancerous elements that they may be easily dissected with the naked eye from the connective tissue of the axilla. It is clear that if these channels are divided, the cell-contents are sown broadcast and infect the "field of operation."

The practice followed by many surgeons of rudely pulling out the axillary lymph glands one by one, especially if they be cancerous, is very liable to infect the connective tissue of the armpit, and lead to the formation of a hard, brawny induration of the axillary tissues.

For a long time I have been particularly careful, in clearing out the axilla when extirpating the mamma for carcinoma, to treat the adipose tissue with its lymphatics and embedded lymph-glands as if they were one organ, and dissect these tissues from the chest wall with great care. The remote consequences of this proceeding have been very gratifying.

Although surgery is in some of these cases fairly successful, yet, broadly reviewing the whole subject of operation for the relief of cancer, we must admit that our present mode of treating it, namely, "to cut out the diseased organ or part affected," though extremely clumsy, is the only really effectual method as yet devised.

The Treatment of Inoperable Cancer of the Breast.—When a cancerous breast comes under the observation of the surgeon after it has so widely implicated adjacent tissues or infected the associated lymph-glands to such an extent that it cannot be completely removed by operation or by caustics, it is said to be "inoperable"; and the same term is applied to cases in which the skin and internal organs are the seat of cancer nodules, and in patients with recurrent cancer infiltrating the chest wall or implicating the large blood-vessels and nerves in the axilla. With the hope of doing good in these circumstances, Dr. Beatson, after careful reasoning on the effect which double oöphorectomy is supposed to exercise on the mammary glands, advocated the removal of the ovaries and Fallopian tubes, and the administration of the extract of thyroid gland; the object being to promote and hasten the fatty degeneration of the cancer elements.

The results in some instances where bilateral oöphorectomy has been performed have been astonishing. In some patients the disease has completely disappeared; in others the disappearance has been followed by recrudescence; and in one remarkable case under my own observation dissemination occurred after bilateral oöphorectomy, but the nodules subsequently disappeared. In many women the operation has temporarily checked the course of the disease, but in the majority it has had absolutely no effect.

It is at present impossible to state whether oöphorectomy is likely to take a permanent place in the surgical treatment of cancer of the breast, but its results have in some instances been very extraordinary. A careful review of the question is furnished by Morris, *Brit. Med. Journal*, 1902, vol. ii. 1293. For a tabular statement of the published results, see Alexis Thomson, *Brit. Med. Journal*, 1902, vol. ii.

CHAPTER XXVIII.

EPITHELIAL TUMOURS OF SEBACEOUS GLANDS; AND RODENT CANCER.

THE consideration of tumours connected with sebaceous glands naturally follows upon that of tumours of the mammary gland, because the latter is regarded as being a highly specialised sebaceous gland or group of glands.

Tumours connected with sebaceous glands are :—1, Sebaceous cysts or wens; 2, sebaceous adenomata.

1. **Sebaceous Cysts** (Wens).—The sebum resulting from the activity of a sebaceous gland escapes as it is formed on to the free surface. Should the orifice of the follicle become occluded, the secretion is retained, and the glandular acini, becoming distended, give rise to an appreciable swelling known as a sebaceous cyst. This is the usual description of the mode by which these cysts arise; but even a superficial examination of a number of sebaceous cysts will serve to show that in many there is no obvious obstruction—indeed, the duct may be widely open and the sebum exuding, so that obstruction of the duct is not an explanation that will cover all cases.

It has long been known that the sebaceous follicles often contain one or more examples of the *Demodex folliculorum*. It is usually stated that these arachnids are harmless; but judging from the grave lesions one species of demodex produces in the external auditory meatus of the dog, it is quite open to question if their presence is merely an epiphenomenon.

These cysts occur in all situations where sebaceous glands abound; an exceptionally common place is the scalp. The cyst may be single; sometimes many are present—indeed, sixteen or more may be counted on one scalp. In size they vary greatly: many are as large as walnuts; others are of the size of peas; they are rarely bigger than Tangerine oranges.

In most situations sebaceous cysts are readily recognised,

as they are distinctly circumscribed and lodged in the skin. On the surface of sebaceous cysts occurring in any part of the trunk and head save the scalp, close scrutiny will reveal either a black dot or a small dimple. This is the orifice of the follicle, and on picking off the black spot and squeezing the cyst, sebum will exude, and thus furnish positive evidence of the nature of the cyst. It is a curious fact that in wens of the scalp the orifice is rarely seen, except those which occur along the junction of the skin of the forehead with the hairy scalp.

A sebaceous cyst, unless it has been inflamed, is easily

Fig. 149.—Sebaceous glands in the velvet of the antler of a stag (*Cervus elaphus*).

shelled out of its matrix. It then presents a capsule and contents. The capsule may be exceedingly thin and pliant, the inner surface presenting an epithelial lining; or it may be laminated, thick, and hard. The contents of the cyst may be pultaceous material, consisting of shed epithelial scales, fat, and cholesterine; or laminæ of firm yellowish-white material arranged like the layers of a bulb. These laminæ represent the epithelium of the lining wall that has been shed in successive layers. In rare instances the contents of sebaceous cysts calcify. Sebaceous cysts are sometimes mistaken clinically for dermoids, and *vice versâ*.

Sebaceous cysts occur not only in the scalp, but also in the

skin covering any part of the trunk. They are excessively rare on the limbs. These cysts are not uncommon in the skin of the penis and scrotum, as well as in that of the labia majora and minora. Among other curious situations may be mentioned the interior of ovarian dermoids and in the "velvet" covering the growing antlers of deer. The "velvet" of a growing antler is covered with fine downy hair furnished with large sebaceous glands (Fig. 149).

Sebaceous cysts, apart from the inconvenience their presence often causes, and their unsightliness when growing in exposed situations, become sources of discomfort when their contents decompose or the cyst inflames. Apart from this, they are liable to secondary changes, whereby they form peculiarly foul and fungating ulcers, or they may develop horns. Each of these changes will be considered.

Decomposition of the Contents.—It has already been mentioned that the contents of a sebaceous cyst sometimes ooze from the orifice of the follicle. In some instances such cysts give rise to an extremely offensive odour. This is due to decomposition of the cyst contents in consequence of admission of air, and as the substance within the cyst contains a large proportion of fat and epithelium, the odour evolved is not difficult of explanation. Decomposition of the cyst contents occurs independently of inflammation of the cyst, and is almost confined to sebaceous cysts occurring on the trunk.

Inflammation of the Cyst.—When sebaceous cysts grow in situations where they are exposed to injury, as, for instance, on the side of the head, where they may be injured by the hat, or on parts of the body where they are liable to be rubbed by the clothes, they are apt to inflame and suppurate. An inflamed sebaceous cyst has a characteristic colour, and resembles the deep red of a ripe plum. Such inflammation may subside and recur. These recurrent attacks of inflammation cause firm adhesion between the capsule of the tumour and the skin, which renders its removal somewhat tedious. When it suppurates the wall thins, and at last bursts, unless this result is anticipated by the timely use of a scalpel. The suppuration often leads to its cure; but fragments of capsule may be retained and lead to the formation of a sinus. In some instances the

cyst bursts, the pus escapes, and the point of rupture heals, the cyst wall being retained. When this is the case the cyst refills with sebaceous matter. Thus in dealing with these cysts surgically it is an important thing to remove thoroughly every particle of the cyst wall.

Horns.—Mention has already been made of the fact that sebaceous cysts are occasionally the source of horns, sometimes of very large size. In their general appearance and structure they are indistinguishable from wart-horns. (Chap. XXIV.)

2. **Sebaceous Adenomata.**—It has been so customary to regard all tumours arising in connection with sebaceous glands as wens or sebaceous cysts, that it is quite an exceptional event for them to be submitted to microscopical examination. It has already been pointed out that there are two varieties of sebaceous cysts, one in which the cyst contains sebum and epithelial *débris*, and another in which the contents are arranged in thick laminæ. In addition to these, tumours occasionally occur in the skin and furnish the usual clinical signs of wens, but when removed and examined microscopically they are found to be composed of lobules which structurally resemble the exuberant masses upon the nose that used to be called lipomata, but are now known to be due to overgrowth of the large sebaceous glands that occupy the skin in this situation (Shattock *). These tumours are sebaceous adenomata, and they are liable to ulcerate, and exceptionally to calcify (Eve †).

There can be little doubt that a few of the supposed wens on the scalp are adenomata, especially those which fungate. Such tumours consist of more or less circular masses of red vascular tissue with definite edges, raised a centimetre or more above the level of the surrounding skin, and resemble cancer—a resemblance that is rendered more complete when the adjacent lymph glands are enlarged. The discharge from such tumours is always very fœtid.

There is usually no difficulty in recognising the nature of these masses when they occur on the scalp, as they are not unfrequently associated with wens (Fig. 150). These appearances are usually described as the result of inflammation and

* *Trans. Path. Soc.*, vol. xxxiii. 290.
† *Trans. Path. Soc.*, vol. xxxiii. 335.

subsequent rupture of a sebaceous cyst. This is probably the correct explanation in some cases, but in others the tumour is made up of adenomatous tissue, which makes it certain that, in a few instances at least, the supposed fungating cyst is an ulcerating sebaceous adenoma.

Treatment.—A sebaceous cyst is easily removed; when the skin covering one is incised and the capsule exposed, the cyst usually shells out quite easily. When the cyst has been

Fig. 150.—Fungating wen (adenoma) on the scalp of a woman 83 years of age.

inflamed and is firmly adherent to the skin, some little dissection will be necessary to effect its removal.

A suppurating cyst can in many instances be dissected out. Often, however, the wall is so thin that the cyst is best treated as an abscess—that is, by free incision.

Before surgeons appreciated the importance of extreme cleanliness, the removal of sebaceous cysts was often followed by septic inflammation. An excellent notion of the fears which surgeons entertained in regard to secondary complications after the removal of wens is furnished by the case of George IV., who had a sebaceous cyst on the top of his head. This formed the subject of a serious consultation attended by

Cline, Astley Cooper, Brodie, and others. Eventually Cooper, with Cline's assistance, removed the wen; and his anxiety lest erysipelas should supervene seems scarcely compensated by the baronetcy which the king bestowed upon him as a reward for the successful issue of the operation.*

Cancer of Sebaceous Glands (Rodent Ulcer).—In British writings on surgery it has been customary for many years to describe under the name of rodent ulcer a form of cancer which exhibits extraordinary clinical characters. In its common form a smooth, rounded knob of about the size of a split pea is noticed on the skin of the face, either on the nose, eyelids, orbital angles, or cheek. This knob may remain for years (seven, eight, or even twelve) and cause no inconvenience save unsightliness; then without obvious reason it may ulcerate and destroy the surrounding skin and underlying tissues, involving all tissues in its vicinity—skin, muscles, fat, cartilage, eyeball, and bone—and producing horrible destruction of the face; in some cases even destroying the base of the skull and meninges and exposing the brain. To produce such terrible effects the disease requires sometimes five, ten, or even more years. In its course it destroys everything, never cicatrises, and is painless.

In recent years the histology of the early knobs which mark the beginning of the disease has been investigated with great care. All observers agree that the disease begins as a solid growth beneath the epidermis. If in this stage the nodule is excised and sections are examined microscopically, it will be seen to consist of gland-ducts filled with epithelium, though sometimes they take the form of solid cylinders. In the latter stages, when ulceration is in full sway, these appearances are lost.

The origin of the initial knob has been ascribed to the following sources:—1, Sebaceous glands; 2, sweat-glands; 3, the hair-follicle; 4, the outer layer of the root-sheath of a hair; 5, epithelial remnants in the course of the facial fissures;

* "Life of Sir Astley Cooper," vol. ii., chap. ix. Brodie refers to this case in his "Autobiography" thus:—"Eventually the operation was performed by Sir Astley Cooper in the presence of Sir Everard Home, Mr. Cline, Sir William Knighton, the King's physicians, Sir Henry Halford, Sir Matthew Tierney, and myself; making a very large assembly for so small a matter."

6, vestiges of the tear-pits of ruminants; and occasionally a hairy mole. My own investigations induce me to ascribe its origin to the sebaceous glands.

Although rodent cancer arises mainly in the facial situations already mentioned, it may occur on the neck and the pinna: it has been met with on the trunk, but never, so far as I know, on the limbs. It occurs most frequently in advanced life, but is not uncommon between thirty and fifty. It has been recorded at the age of twenty, but never before puberty (fifteenth year). It is more frequent in men than in women. The extraordinary features which distinguish it from the common kinds of cancer are the following:—1, It does not infect lymph-glands; 2, it does not disseminate; 3, though as a rule solitary, it may be, and often is, multiple; 4, its duration may extend over many years.

Treatment.—This variety of carcinoma gives excellent results to adequate surgery. When freely excised in the early stages recurrence is exceptional. Even in the late stages, as Moore demonstrated in 1867, bold and free excision often permanently arrests the disease.

In cases in which operative measures fail, much good may be done by means of the X-rays, and McFeely * has reported good results from the injection of formalin.

* *Medical Press and Circular*, Sept. 3, 1902.

CHAPTER XXIX.

EPITHELIAL TUMOURS OF THE THYROID GLAND.

Adenomata.—Two varieties of adenoma are met with in the thyroid gland; by most writers they are described as adenomatous goitre and cystic goitre or bronchocele, to distinguish them from the general enlargement of the entire gland known as "parenchymatous" goitre. A thyroid adenoma is an encapsuled tumour of the thyroid gland containing vesicles of the same character as those which make up the normal gland. The size of these adenomata varies greatly; many are no bigger than cherries, whilst others are bigger than fowls' eggs. When both lobes contain an adenoma the gland will maintain its normal shape; when one lobe only is involved, the gland becomes unsymmetrical; exceptionally an adenoma will develop in the isthmus. As the tumour increases in size the vesicles coalesce, the septa gradually disappear, and a thyroid cyst or bronchocele is formed. Bronchoceles sometimes attain very large dimensions, and six or more may grow concurrently in the same gland. Their capsules are formed of dense fibrous tissue, which may contain calcareous plates; in some old specimens the capsules are converted into calcareous shells. Small bronchoceles contain a thick peripheral stratum of glandular tissue; their central cavities contain colloid material or a thinner fluid of a reddish colour, due to hæmorrhage; not unfrequently the fluid is largely charged with cholesterine. In very large bronchoceles all traces of gland tissue disappear; nothing remains but a tough, more or less calcified cyst-wall.

Aug. Reverdin * recorded a case in which an old man of sixty-two years had a cystic adenoma of the thyroid 60 cm. in circumference. On puncturing it a large number of bodies, white in colour and crenate like mulberries, escaped with a large quantity of brown fluid. Reverdin stated that the composition of these bodies was like coagulated fibrin.

* *Journal de la Suisse Romande*, 1883.

Bronchoceles sometimes attain great proportions. Perhaps the largest is one successfully enucleated by P. Bruns * from a woman fifty-eight years of age: the tumour was so large as to reach as low as the navel, and its weight produced lordosis in the cervical and kyphosis in the thoracic regions of the spine

Fig. 151.—Bronchocele of unusual size. (*P. Bruns.*)

(Fig. 151). The cyst was single-chambered, the walls were in part calcified. The tumour was so heavy that the woman was in the habit of resting it upon the table when she sat down.

Mention must be made of a very rare form of thyroid cyst in which the walls are beset with papillomata. Cysts of this kind are apt to recur after removal. A very remarkable example of this has been recorded by Barker and Pollard.†

Treatment.—Adenomata of the thyroid gland and broncho-

* Bruns' *Beiträge*, bd. vii. 650.

† *Trans. Path. Soc.*, vol. xxxvii. 507.

celes, when of small size, rarely cause trouble, and a unilateral bronchocele the size of a closed fist, though it appears unsightly, is often quite harmless. Large bronchoceles sometimes cause pain, and when they press upon the trachea give rise to dyspnœa, which will in some cases become so alarming as actually to endanger life. There is a very rare variety known as **wandering goitre** on account of its mobility. So long as the tumour restricts its excursions to the neck no harm results, but occasionally these tumours will descend as low as the thoracic inlet. When this happens, the bronchocele becomes squeezed between the manubrium of the sternum and the trachea. This impaction induces urgent symptoms of dyspnœa.

When, from unsightliness or other causes, it is deemed necessary to interfere with an adenoma of the thyroid or a bronchocele, it is safe practice to enucleate it. The affected lobe is exposed through a median incision, and the thyroid tissue incised until the capsule of the tumour is exposed. By means of a raspatory the adenoma can be shelled out of its bed quite easily. This method of treatment is safer and quite as efficient as thyroidectomy, and the patient runs no risk of hæmorrhage, tetany, or myxœdema.

The success with which such operations can be carried out is demonstrated by the results recorded by Kocher,* who has performed 555 consecutive operations for "colloid struma" with one death, and this was due to the anæsthetic.

The large bronchoceles, although very unsightly, are not so likely to lead to mischief as the small bronchoceles and the more solid adenomata which compress the trachea laterally, causing this air-duct to assume the shape of a scabbard. (See Figs. 4 and 5, p. 6.)

Carcinoma.—The thyroid gland is liable to carcinoma and sarcoma, but the clinical effects of the two diseases are so much alike that it is scarcely possible to determine between them.

Cancer of the thyroid is an extremely rare condition in England; in twenty years only three examples have come under my observation. It is more liable to attack a diseased thyroid than one which is healthy, and this probably explains its greater frequency in goitrous districts.

* *Corresp. Blatt. f. Sch. Artze*, 1898, bd. xxviii. 545.

Cancer of the thyroid usually occurs between the fortieth and sixtieth years. I had a case under my care in a girl seventeen years of age: the nature of the tumour was determined by microscopic examination of portions of the growth removed during life. In its early stages it resembles an ordinary goitre, but it steadily increases in size and becomes very hard, and later bossy outgrowths disturb the regular outline of the gland. This is always a suspicious sign, and when it is accompanied by pain and paralysis of the recurrent laryngeal nerve it indicates that the adjacent parts are being infiltrated; this is also indicated by the fixity of the enlarged thyroid. In the course of the case the internal jugular vein and the carotid artery may be implicated, and even the nerves of the brachial plexus, but the most serious local effect is due to the disease extending into the trachea. This is a very serious feature of the tumour, because the implication of the trachea not only induces dyspnœa, but when the intruding process ulcerates it sets up septic pneumonia, which is usually rapidly fatal. In the early stages of the disease the tumour may so resemble an ordinary bronchocele that the surgeon attempts to enucleate it: this happened to me on one occasion, but the free bleeding and indefiniteness of the tumour soon apprised me of the nature of the case. The patient recovered from the operation, but a huge fungating mass slowly made its way through the cicatrix and destroyed life in eight months. It is a significant fact that there is a very scanty literature in relation to the operative treatment of malignant disease of the thyroid gland, and this is a clear indication of its comparative rarity and the hopelessness of operative treatment; this last fact is amply confirmed by the perusal of the few published statistics. There is a feature of carcinoma of the thyroid gland which must be referred to, and that is the rarity with which it disseminates. That it occasionally gives rise to secondary deposits is beyond dispute, and the similarity of the structure of the secondary nodules to the closed follicles of the thyroid has been made the subject of much careful study.

General Thyroid Malignancy.—This term is applied to a rare but very remarkable form of disease, in which tumours structurally identical with the thyroid gland appear in the

bones. The fact which invests them with more than ordinary interest is that they have, in nearly all instances, been associated with an obvious enlargement of the thyroid, which clinically is indistinguishable from the common kind of enlargement known as parenchymatous goitre. The earliest cases were observed by Cohnheim * and Morris †.

Since 1880 a score of cases have been described, and from the records the following facts may be stated. The tumours occur most frequently in women (5 to 1), and are most common between the fortieth and sixtieth years, but one case has been observed as early as twenty-six. They show a striking preference for the skull, but have been observed in the femur, clavicle, sternum, humerus, and on several occasions in the vertebræ.

In some of the patients the secondary tumours are large, and pulsate. In the extraordinary case recorded by Cramer ‡ the secondary mass occupied the sternum, and pulsated so markedly and caused so much pain that it was mistaken for an aneurysm: this induced the surgeon to ligature some of the large vessels.

In England the chief cases have been observed and recorded by Haward,§ Coats, || and Horsley.¶ Goebel ** has collected the German literature in an interesting paper, and has shown that in many instances these secondary tumours have been subjected to operative treatment, and on the whole with satisfactory results.

I think the explanation of this interesting condition may lie in the fact that in the early stages carcinoma of the thyroid is such an insidious disease, and mimics so closely the innocent bronchocele, that the primary disease is overlooked. This view receives some confirmation from the fact that a very similar condition of things is sometimes associated with carcinoma of the prostate.

* Virchow's *Arch.*, lxviii. 547.
† *Trans. Path. Soc.*, vol. xxxi. 259.
‡ Langenbeck's *Arch.*, bd. xxxvi.
§ *Trans. Path. Soc.*, vol. xxxiii. 291.
|| *Trans. Path. Soc.*, vol. xxxviii. 399.
¶ *Clin. Journal*, vol. xiii.
** *Deut. Zeitsch. f. Chir.*, bd. xlvii. 348.

The Pituitary Body.—The close functional and structural relationship of the glandular part of the pituitary to the thyroid body makes it desirable to describe tumours of this structure in sequence to those of the thyroid gland.

Adenomata of the pituitary body bear much the same relation to it that parenchymatous goitres do to the thyroid body; indeed, they are sometimes referred to as pituitary goitres. A few cases have been observed in man.* Goodhart † described an interesting case in a baboon, with its clinical history; and Sibley ‡ observed a specimen in a ewe.

These tumours are at first isolated from the general cavity of the cranium by the circular fold of the dura mater known as the *diaphragma sellæ*, and they generally produce erosion of the pituitary fossa.

* Wills, *Brain*, vol. xv. 465; Loeb and Arnold, Virchow's *Arch.*, bd. lvii. 172.

† *Trans. Path. Soc.*, vol. xxxvi. 36.

‡ *Trans. Path. Soc.*, vol. xxxix. 459

CHAPTER XXX.

CARCINOMA OF THE LIPS; MOUTH; TONGUE; PHARYNX; AND LARYNX.

Cancer of the Lips.—In this situation squamous-celled cancer is common between the thirty-fifth and sixtieth years; it has been recorded as early as the twenty-fifth year and as late as 102 (Jalland). A remarkable feature is the very great preference it shows for the lower lip. Thus out of 565 cases tabulated by Loos in Bruns' Klinik at Tübingen. 534 arose in the lower lip. Of these, 467 of the patients were men and 67 women. It is also remarkable that though men are infinitely more liable to cancer of the lower lip than women. yet the liability is equal for both sexes in regard to the upper lip. Out of the 31 cases of cancer in the upper lip in Loos' total of 565, 16 occurred in men and 15 in women.

Cancer of the lip, when left to run its course, soon infects the lymph glands in the submaxillary region. Occasionally it will attack the right side of the lower lip, but infect the lymph glands in the left submaxillary region, and *vice versâ*. No anatomical explanation of this anomaly is forthcoming. The tissues of the lip are gradually destroyed, and the mucous membrane covering the mandible is implicated and the bone itself eroded. In the later stages the glands in the neck form huge masses, which gradually implicate the overlying skin, causing it to ulcerate, and at last the ulcer in the neck and the primary ulcer on the lip join; and as the underlying tissues slough a horrible chasm is formed in the neck, on the floor of which large vessels may be seen pulsating. Death is due to asthenia from repeated hæmorrhage, or from a profuse hæmorrhage, septic pneumonia, or œdema of the glottis. The average duration of life in untreated cases is twelve months.

Treatment.—Cancer of the lip in the early stages is easily

removed by the V-shaped method, or some one or other of its many modifications.

When the submaxillary or submental lymph glands are enlarged they should be dissected out. When the disease has been allowed to extend until it involves the underlying bone and extensively infiltrates the cheek and neck, operative interference can rarely be undertaken with good prospects.

After the excision of cancer of the lip, **recurrence** may take place along the edge of the scar, or in the submaxillary lymph glands, and as these enlarge, the periglandular tissue also becomes infiltrated with cancerous material, which renders the removal of the diseased tissue a difficult and often impossible task. There is a form of recurrence which begins near the angle of the mandible, and spreads up each side of the body of this bone in such a way as to resemble a periosteal sarcoma.

The early removal of cancer of the lip is more likely to be followed by good results than in any other part of the body. Occasionally the operation is followed by quick recurrence, even when the primary lesion was very small; but in a large proportion of cases recurrence is delayed two, three, or more years, and in a few cases a cure is brought about.

Cancer of the Tongue.—In this situation cancer is most frequent after the age of forty years, but it has been recorded in patients as young as twenty-five and in individuals of seventy-five years; it is three times commoner in men than women. The predilection of this disease for the tongues of men is usually attributed to the habit of smoking. It generally makes its appearance on one side of the tongue, near its tip: in a fair proportion of cases it begins on the dorsum, but always distinctly to one side of the middle line, and the beginning of the disease is always at some spot in the anterior two-thirds of the tongue.

In a fair proportion of cases cancer of the tongue is preceded by changes known as **leukoplakia** and **ichthyosis**: they are frequently referred to as **pre-cancerous conditions**.

It is a fact of some importance that lingual leukoplakia is often due to syphilis, and, as will be mentioned in dealing with cancer of the vulva, this disease is in that situation often preceded by leucoplakia frequently of syphilitic origin. Every

surgeon who has had much to do with cancer of the tongue has noticed that chronic syphilitic ulcers of the tongue are very liable to become cancerous.

Ichthyotic patches upon the tongue do not necessarily become cancerous in every individual, and when cancer attacks an ichthyotic tongue it does not always begin in the ichthyotic patch; indeed, cancer is sometimes seen on one side of the tongue and ichthyosis on the other. Even after excision of a cancerous tongue the stump may become ichthyotic and the disease not recur in it.

When cancer attacks the tongue it usually destroys life quickly: the lymph glands in the neck are soon infected, and, as a rule, the disease runs its course in about a year. The average duration of life varies from six to twenty-four months.

Death ensues in a large proportion of cases from exhaustion, the result of pain, distress of mind, and difficulty in taking food; in some it occurs from septic pneumonia, the result of inhaling the fœtid discharges from the mouth; a few die early from hæmorrhage when the ulceration opens up the lingual or the carotid artery. Death is occasionally due to asphyxia. This may arise from two causes: the cancer may extend to the base of the tongue and infiltrate the epiglottis and its folds, producing œdema of the glottis, or a mass of enlarged glands in the neck may press upon the trachea and cause suffocation.

In addition to the tongue and lips, cancer may begin in the mucous membrane of the **cheek,** the **gums, soft palate, tonsils,** and **pharynx.**

In the case of the **cheek,** cancer is sometimes preceded by a patch of leukoplakia, as in the case of the tongue. The disease often starts close to the angle of the mouth, and extends backwards into the cheek; or it begins in the fold of mucous membrane between the gum and the cheek; and occasionally it starts in the centre of the cheek, often on a level with the meeting-place of the crowns of the upper and lower molar teeth.

Squamous-celled cancer may begin in any part of the **gum,** but it appears more frequently in the mucous membrane covering the lower than in that covering the upper alveolar processes. The disease often starts near the **stump of a carious tooth,** and quickly infiltrates the adjacent mucous

membrane; thus, whilst it is eroding the bone, it is creeping along the mucous membrane towards the cheek on one side and the tongue on the other. Similar effects may be observed when the disease attacks the gums in relation with the maxilla: as the alveolar process is destroyed the cavity of the antrum is exposed, and a foul ulcerating chasm formed. One of the facts connected with cancer of the mucous membrane of the mouth—and it matters little whether the disease begins on the tongue, cheek, hard or soft palate, or gums—is the extraordinary size which the infected lymph glands in the neck sometimes attain, whilst the ulcer scarcely exceeds 1 cm. in diameter. This is worth bearing in mind, because an enlargement of the cervical lymph glands in individuals past middle age should always induce the surgeon to examine the various recesses of the mouth and fauces for small, inconspicuous cancerous ulcers, and with every care they sometimes escape detection during life. It is necessary to emphasise this, because a good deal has been written about "branchiogenous cancer," or, as it is sometimes called, "malignant cyst" of the neck. The tumour is most commonly observed after the age of fifty, and is deeply seated in the neck, usually near the fork of the carotid; it grows with great rapidity, and in many cases softens in the centre and gives rise to fluctuation. The overlying skin becomes brawny and red, and the resemblance to an abscess is very striking. Gradually the implicated skin sloughs, and then a cancerous chasm forms in the neck. Some writers believe that these are primary cancers arising in remnants of branchial clefts. My belief is that, in most of the cases, these gland masses are secondary to cancer originating in recesses of the pharynx or naso-pharynx, and the theory that they arise in remnants of branchial clefts is pure fiction. They run a rapidly fatal course: the average duration of life is about six months. These tumours resent interference, and in the few cases where patients have survived operation quick recurrence has been the rule.

Treatment.—The results of the operative treatment of cancer of the tongue stand in striking contrast to those which follow operations for this disease when affecting the lower lip.

The manner of removing a cancerous tongue is modified

according to the situation and extent of the disease. The excision of the anterior portion of the tongue, or the right or left anterior fourth of the organ when the disease is localised to one side, is an operation devoid of risk or difficulty. When the disease deeply invades the tongue, involves the floor of the mouth, or extends so far backwards that, in order to get beyond the limits of the disease, the surgeon interferes with the pillar of the fauces, then the operation is often hazardous. The chief difficulty is connected with hæmorrhage, and in order to obviate it a variety of methods have been advocated for the excision of the tongue. A careful selection of cases, wide removal of the diseased tissues, and removal of the infected submaxillary lymph glands are the points to bear in mind.

It is an important point in operating upon the tongue to avoid the entrance of blood into the trachea, as it is then drawn, during inspiration, into the lungs, and gives rise to septic pneumonia. Should blood in considerable quantity get into the trachea, it may cause suffocation. To avoid these complications it is useful, in extensive operations on the tongue, to perform laryngotomy and administer the anæsthetic through a laryngotomy tube; and in order to prevent blood from getting into the trachea, the pharynx is plugged with a sponge.

The mortality of operations for the removal of cancerous tongues is not less than 10 per cent.: the chief causes of death are hæmorrhage, septic pneumonia, and asthenia.

Although after excision of the tongue recurrence in the stump or cervical lymph glands within a year of the operation is the rule, nevertheless it is in some cases delayed for five and even seven years. It is also useful to bear in mind that, in some cases where the disease is advanced and too extensive to admit of removal, the pain may be relieved by division of the lingual nerve; and a few patients are rendered comfortable by ligature of the lingual and facial arteries.

It has been already mentioned that cancer occurring in the gums will afterwards invade the mandible or maxilla, according to its situation. Although in the majority of instances in which the maxilla is implicated the disease begins in the gingival mucous membrane, there is a small number of cases in which patients past middle life complain of pain in the jaw

for which no adequate cause can be assigned. Gradually a slight fulness is observed in the infra-orbital region, with perhaps œdema of the eyelid: the skin becomes brawny, and at last a cancerous ulcer appears in the skin of the cheek, and the antrum is then found to be filled with a tumour. When such a case is submitted to operation and the skin of the cheek reflected, the inroads the disease has been silently making on the surrounding parts are seen to be truly extraordinary. The greater part of the maxilla will be found destroyed, and outrunners from the growth will be found in the orbit and among the pterygoid muscles. The skin of the cheek is usually so infiltrated that it must be removed. The successful treatment of such cases demands much boldness on the part of the operator, as he will find it necessary to sacrifice the eye and the orbital contents, the palatine aspect of the maxilla and a portion of the skin covering the cheek: as a result a large yawning cavern is left. Life is rarely prolonged, but the patients are spared much pain and discomfort.

Bolam * has carefully studied the histology of primary epithelial tumours of the mucous membrane, and has satisfied himself that the structure of some of them indicates that they arise in the glands of the antrum. My independent examination of some of my own cases leads me to take the same view.

Carcinoma of the Larynx.—When this disease originates in the mucous membrane of the ventricles, vocal cords, or ventricular bands, it is said to be **intrinsic.** When cancer arises in the aryteno-epiglottic folds, or the mucous membrane covering the arytenoids or the inter-arytenoid folds, it is said to be **extrinsic.**

In addition, the larynx may be implicated in carcinoma of the tongue, fauces, or upper part of the œsophagus. Both forms of laryngeal cancer are essentially diseases of adult life.

Intrinsic cancer of the larynx usually commences in one of the ventricles, and is almost invariably of the warty variety: it is particularly rich in cell-nests, and these are exceptionally horny. The papillomatous character of intrinsic laryngeal cancer must be borne in mind, or it may lead to grave errors in diagnosis. The laryngeal wart is essentially a disease of

* "Antral Carcinoma," *Journal of Pathology and Bacteriology.* Edinburgh, 1898.

children and young adults, whereas carcinoma is an affection of adults, especially men who have passed the meridian of life. A wart-like growth in the larynx of an individual over forty years of life should be viewed with suspicion. Lymph-gland infection and dissemination are not marked features of intrinsic laryngeal cancer.

Laryngeal cancer is usually rapid in its progress: death occurs in from twelve to eighteen months, and is rarely prolonged beyond two years. The fatal result is due to asthenia, which is intensified by the difficulty these patients experience in swallowing, and pneumonia. Actual suffocation is obviated early in the course of the disease by tracheotomy.

Extrinsic cancer of the larynx appears to be a far more formidable affection than the intrinsic form. It not only extends more rapidly and infects the lymph glands at a very early period, but implicates the surrounding parts far more extensively than the intrinsic variety; the duration of life is therefore shorter. Dissemination is extremely rare.

Treatment.—It is of great importance to recognise early the nature of this grave disease of the larynx: as a rule, there is little difficulty in appreciating the extrinsic variety, but the papillomatous nature of intrinsic cancer of the larynx makes the diagnosis somewhat dubious in the early stages. Thus it is customary, when there is an element of doubt as to the nature of a laryngeal growth in an adult, to remove a fragment by means of laryngeal forceps and submit it to microscopical examination.

Acting on the principles that prevail in the treatment of cancer in other parts of the body, surgeons have in recent years (following the lead of Billroth, 1873) attempted to cure cancer of the larynx by excision. Unfortunately, there is very little to urge in favour of complete extirpation of the larynx; it has been abandoned by most surgeons in the extrinsic form of the disease, and even for the intrinsic form laryngectomy is fast falling into disfavour. The operation has an excessively high mortality: a very large proportion of the patients succumb to septic pneumonia, and the few that recover are often in a miserable and pitiable condition.

Excision of a lateral half of the larynx for intrinsic cancer is a much more successful operation; and this is also true of

the operation known as thyrotomy, in which the thyroid cartilage is divided in the median line and the diseased soft tissues dissected out.

The reason that thyrotomy is more successful than laryngectomy is due to the fact that the laryngeal cartilages are not very liable to be infiltrated by carcinoma. It is therefore a comparatively simple operation to split the thyroid cartilage in the middle line, thoroughly expose the interior of the larynx, and remove the affected tissues. In view of the great improvement in the details of this operation, its risks have been reduced almost to a vanishing point. In cases too advanced for thyrotomy, the needs of the patient are in most cases best satisfied by a simple tracheotomy.

CHAPTER XXXI.

CARCINOMA OF THE ŒSOPHAGUS; STOMACH; INTESTINES; RECTUM; AND ANUS.

It is clearly established by a careful study of death-returns, that in more than half the cases in which death is attributed to cancer the primary seat of the disease is in the digestive organs. In the preceding chapter attention was drawn to the peculiar sex-distribution of cancer of the lips and the excessive liability of the lower lip of men to squamous-celled cancer: the infrequency with which the anus is attacked primarily is unaccountable, especially when we bear in mind that cancer of the rectum is very common. The distribution of cancer in that part of the alimentary canal which occupies the belly is somewhat remarkable. For example, the stomach is not only the commonest primary seat of cancer when compared with other digestive organs, but it stands third in order of frequency among all organs, the breast (mamma) being first and the uterus second in order of liability. The small intestine (duodenum, jejunum, and ileum) is very rarely attacked by cancer, but in the rest of the canal (colon and rectum) it is a very frequent disease. Even in its attacks on the big bowel cancer exhibits a partiality at present inexplicable, for it is common to find it in the rectum and sigmoid flexure, but its appearance in the vermiform appendix and ileo-cæcal valve is phenomenal; and its presence in the cæcum may be fairly described as unusual. It is as difficult to explain the comparative immunity of the ileo-cæcal valve from cancer as to find an adequate cause for its excessive frequency at the pylorus.

The Œsophagus.—The gullet is liable to two varieties of cancer: that which attacks its upper two-thirds is squamous-celled, whereas cancer of the lower segment is of the glandular type. This disease appears to be four times more frequent in men than in women, and is common between the fortieth and

sixtieth years. It has been observed as early as the thirtieth year, and my oldest case was eighty-four. Certain parts of the œsophagus are more liable to be attacked than others; the usual situations are: 1, at the level of the cricoid cartilage; 2, where it is crossed by the left bronchus; 3, at its termination.

Nothing is known of the early stages of cancer of the œsophagus, as it produces few symptoms until neighbouring structures, such as the larynx, trachea, pleura, etc., are implicated.

The disease runs a very rapid course; most cases terminate fatally within a year from the time the patient comes under observation. Death occurs in a variety of ways: inanition and exhaustion are the results of obstruction to the passage of food; pleurisy and septic pneumonia are due to perforation of the pleura and trachea. In very rare instances an œsophageal perforation into the pleura may establish a well-marked pneumothorax. A fistula between the trachea and œsophagus is common in this disease. Mediastinal abscess, which may perforate the pleura or pericardium, sometimes forms, and ulceration has been known to broach the aorta. When cancer begins at the commencement of the œsophagus, the recurrent laryngeal nerves are apt to become entangled and cause paralysis of the laryngeal muscles.

When the disease occupies the middle and lower parts of the œsophagus, the lymph glands of the mediastinum and lumbar region enlarge. When the upper third of the tube is implicated, the mediastinal glands and those at the root of the neck are infected. It does not necessarily follow that the glands nearest the seat of disease are those most enlarged, for it occasionally happens that the neighbouring glands are apparently unaffected, whilst those at some little distance are charged with cancerous material. For instance, in a case in which a man died from a large cancer of the middle third of the œsophagus, the mediastinal glands were slightly bigger than usual; but in the neck, immediately above the clavicle, there was one hard gland, the size of a bean, just beneath the skin. The enlargement of this gland was detected during life, and regarded, in the presence of other signs, as an indication of the malignant nature of the œsophageal stricture. The infection of this gland is probably due to the involvement of

the cervical lymphatics secondary to infection of the thoracic duct. Dissemination is rare.

When cancer attacks the œsophagus where it passes through the diaphragm, the tumour assumes the shape of a spool, and

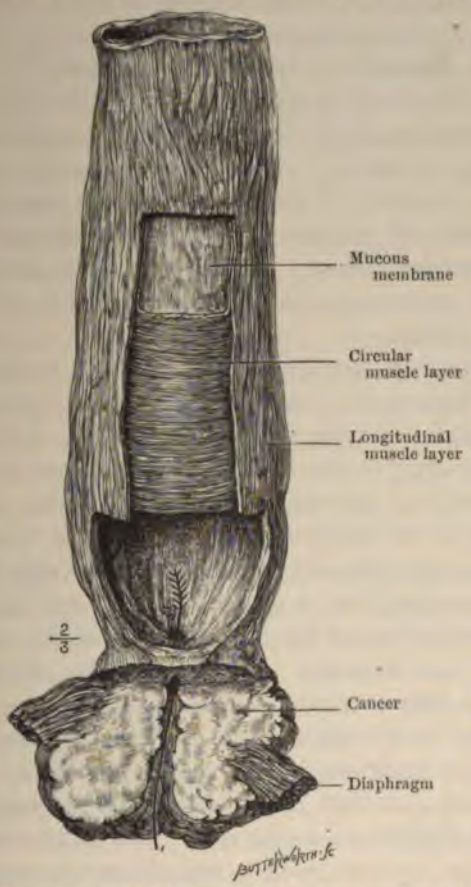

Fig 152.—Cancer of the cardiac orifice of the œsophagus, from a man aged 48 years. The gullet has been dissected to show the great enlargement of the muscular layers.

as the orifice becomes contracted, the muscle fibres of the gullet markedly hypertrophy (Fig. 152). This explains the great force with which patients under these conditions eject food and drink when they attempt to swallow.

Treatment.—Attempts have been made to remove cancer of the œsophagus when it has been situated high enough to

be accessible in the neck. The results are not encouraging. When the disease so obstructs the gullet as to render the patient liable to starvation, gastrostomy has been found useful, and this is especially serviceable when the cancerous mass is high in the œsophagus, and causes liquid to trickle into the larynx in the act of swallowing.

The Stomach.—Cancer of the stomach is very common, and stands third, as we have seen, in the order of frequency among the organs, the mamma being first and the uterus second in order of liability. The disease arises in the glands which are so abundant in the gastric mucous membrane. In carefully prepared sections the epithelium will be found to be of the columnar variety. One of the most striking features of gastric cancer is the readiness with which the cells undergo colloid change.

We have no precise knowledge of the manner in which the cancer begins; it is commonly situated at or in the immediate neighbourhood of the pylorus. "If a line be drawn from one inch (2·5 cm.) to the left of the œsophagus, to a point on the lower border of the stomach four inches (10 cm.) from the pylorus, the part to the left of this line will be found to suffer very rarely from cancer. The rest of the surface, the right and upper part, is the peculiar seat of cancer" (Wilks and Moxon).

Cancer arises at the cardiac orifice of the stomach in about 4 per cent. of cases. Occasionally this disease attacks the edges of chronic ulcers, and there is reason to believe that it may arise at the edges of the cicatrix of a gastric ulcer.

In the early stages the disease is limited to the mucous membrane; it then invades the muscular and, in a fair proportion of cases, the serous coats. The infiltration of the tissues about the pylorus leads to its obstruction, which is often so extreme that an ordinary probe can scarcely traverse it. The mucous surface of the tumour ulcerates, sloughs, and bleeds. Occasionally the pyloric branch of the hepatic artery is eroded, and the bleeding may be so profuse as to terminate life in patients whose strength has been reduced by small hæmorrhages, frequently repeated, from the ulcerating surface of the cancer. Whilst these changes are in progress on the mucous aspect of the tumour the subserous tissues become infiltrated, the

overlying peritoneum is involved, and adhesions form between it and the omentum, the parietal peritoneum, liver, and occasionally the transverse colon.

The extent to which the disease infiltrates the surrounding parts varies greatly. In a large number of cases it remains restricted to a zone extending 3 cm. on each side of the pylorus; exceptionally it will implicate the duodenum as low as the orifice of the common bile duct. More often the disease creeps along the lesser curvature of the stomach. When the cardiac orifice is attacked, the cancer will extend into the œsophagus and downwards along the lesser curvature.

For a time the disease remains restricted to the walls of the stomach, but later it spreads along the adhesions to such structures as the liver, pancreas, gall bladder, duodenum, colon, spleen, and diaphragm; then, as ulceration follows, it happens that the floor of the ulcer will be formed by the liver, the pancreas, or the spleen. When such parts as the colon or duodenum form the base of the ulcer, perforation occurs, and a gastro-colic or gastro-duodenal fistula is formed. These fistulæ are more common with cancerous than with the simple forms of gastric ulcers.

The lymph glands in the gastro-hepatic omentum are infected in more than half the cases; extensive enlargement of the lumbar glands sometimes happens, and those lying in the posterior mediastinum may be infected; the infection in exceptional cases may extend to the glands at the root of the neck, and occasionally the walls of the thoracic duct become cancerous and its lumen obstructed (Mathieu, Hillier).

Dissemination is the rule with cancer of the stomach. The secondary nodules usually make their appearance in the liver, lungs, and frequently in one or both ovaries.

Finlay * has recorded a case in which a cancer originating at the cardiac orifice of the stomach became widely disseminated, and the skin of the trunk was thickly studded with hard subcutaneous nodules varying in size from a pea to a walnut. There were a few nodules on the arms and legs. The lymph glands in the groins and axillæ were enlarged. During life two nodules were excised, and when examined

* *Trans. Path. Soc.*, vol. xxxiv. 102.

microscopically were found to consist of alveoli lined with columnar epithelium. This circumstance indicated that the primary growth was in the alimentary canal, although during life its precise locality could not be fixed.

There is a curious and somewhat rare condition of the omentum associated with cancer of the stomach. That it is little understood may be inferred from the variety of names applied to it—colloid or hydatid tumour; colloid cancer; myxo-sarcoma of the omentum. There can be little doubt that the uncertainty of knowledge concerning it is very largely due to its rarity. In typical cases the omentum is greatly thickened (5 to 10 cm.), and it may weigh upwards of ten pounds. The surface is flocculent, and on close inspection small rounded collections of gelatinous material may be seen in the midst of the villous processes; some of them are stalked and look like white currants. On microscopic examination the bulk of the omentum is found to be made up of myxomatous tissue, but here and there are collections of epithelial cells surrounded by incomplete capsules of fibrous tissue. The general impression I have formed from an examination of the only specimen that has come under my observation is that the condition is due to infiltration of the great omentum from a cancerous stomach, and that the cancerous material with the proper omental tissue undergoes colloid or myxomatous degeneration. The subject requires the close investigation of perfectly fresh material for its proper elucidation.

Attention has already been drawn to the extreme liability of cancer of the stomach to undergo colloid degeneration.

Clinical Features.—Cancer of the stomach is rare before the thirtieth year; it is most common between the fortieth and sixtieth years; it has been demonstrated as early as thirteen —it occurred near the cardiac end of the viscus, and the patient was a girl.*

Gastric carcinoma runs a very rapid course, life being rarely prolonged beyond twelve months from the time the disease is first recognised. Its rapidly fatal course, especially when the pylorus is implicated, is largely due to the obstruction offered to the escape of food into the duodenum; hence the food is retained

* Norman Moore, *Trans. Path. Soc.*, vol. xxxvi. 195.

in the stomach, which often becomes dilated into a huge sac, sometimes reaching as low as the pubes. Fermentation of the retained and partially digested food occurs, and the contents of the stomach are vomited at irregular intervals, mixed with altered blood which escapes from the ulcerated surface of the tumour.

When cancer involves the cardiac orifice, the stomach is usually contracted. Cancer of the stomach causes death in various ways. Of these the chief are—exhaustion due to starvation and frequent hæmorrhage; perforation into the general peritoneal cavity and fatal peritonitis. In exceptional instances the diaphragm is perforated and fatal pleurisy ensues.

Treatment.—The only radical method for the relief of gastric cancer is wide excision. When the disease attacks the pylorus this part is excised, and the cut edges of the stomach and duodenum (pylorectomy) are carefully sutured. When this is impracticable on account of the wide extent of the disease, or lymph-gland infection and dissemination, then, in order to obviate inevitable death by starvation, a fistula may be established between the stomach and jejunum (gastro-jejunostomy), a proceeding which has occasionally been followed by a small amount of success; but it is merely a palliative procedure.

Encouraged by the occasional success of pylorectomy, surgeons have extended their efforts, and in 1897 Schlatter * removed the entire stomach from a woman aged fifty-six for carcinoma. The patient survived the operation fourteen months, and died with local recurrence and dissemination. Gastrectomy has been performed several times subsequently to Schlatter's successful operation.

The best and most recent literature relating to the operative treatment of gastric cancer is that of Keen,† Barker,‡ Mayo Robson,§ and Rutherford Morison.||

Carcinoma of the Rectum.—This disease becomes clinically recognisable as a hard tuberous mass in the mucous membrane,

* *Lancet*, 1898, vol. i. 141.
† *New York Medical Record*, 1898.
‡ *Clinical Journal*, 1898.
§ *Brit. Med. Journ.*, 1900, vol. i. 694.
|| *Ibid.*, 1898, vol. i. 481.

which slowly spreads at its periphery and gradually travels round the bowel and forms a thick circular diaphragm with a central perforation no wider than a crow-quill. In some specimens the lumen of the bowel is narrowed not so much by the exuberance of the growth as by the contraction it exercises upon the intestinal wall. Sometimes the tumour will have a

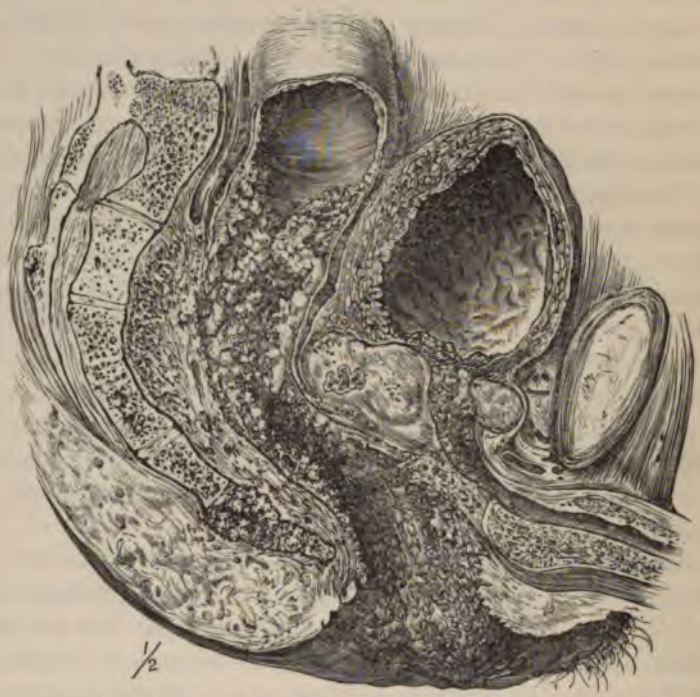

Fig. 153.—Side view of the male pelvis in an advanced case of rectal cancer, to show its infiltrating tendency.

diameter of 2 cm. and less, yet its power of contraction is so great that it completely obstructs the bowel. This variety is more frequent in the colon than in the rectum.

In some cases the disease, instead of forming a localised tuber, tends from the first to infiltrate the muscular as well as the submucous tissues, and even extends beyond the confines of the gut to adjacent parts such as the peritoneum, pelvic connective tissue, prostate, or vagina. Ulceration occurs early in this variety. Whilst in one case the cancer tends to

penetrate the wall of the rectum, in another it will form large and exuberant masses, blocking up the gut and even protruding beyond the anus. It may in a third case be restricted to a narrow area of the bowel, and remain apparently indolent for a long period.

Rectal carcinoma consists of glandular recesses, lined with tall columnar cells, embedded in a stroma of dense connective tissue. In order to make out the nature of the growth, sections should be taken from the margins of the tumour, because the deeper parts are much altered by ulcerative and necrotic changes. As a matter of fact, in many cases of rectal cancer, judging merely from the appearances under the microscope, it would be difficult to determine whether the section was prepared from an adenoma or a carcinoma; but it must be borne in mind that the adenoma remains restricted to the mucous membrane, whereas in cancer we find the glands with their characteristic columnar cells interspersed among the muscular fasciculi of the gut wall. The proportion of connective tissue varies greatly. In some cancers the glands are closely set; in others they are ill-formed, arranged irregularly, and embedded in an abundance of connective tissue. Occasionally collections of lymphoid tissue are observed. When a rectal cancer invades the anus, the part of the tumour which involves the anus loses its glandular character and assumes the squamous-celled form (Harrison Cripps). Rectal cancer is very rare before the age of twenty; it is commonly met with between the thirtieth and fifty-fifth years.

The pelvic and lumbar lymph glands are first involved, then those glands lying in the course of the external iliac artery. Should the skin of the anus become infiltrated, then the inguinal lymph glands may be infected. The liver is the seat of secondary deposits in a large proportion of cases of rectal cancer. Occasionally widespread dissemination occurs, and nodules are formed not only in the liver, but in the lungs, kidneys, and bones. Few things are more surprising than, on examining a cancer-nodule from the liver, or from a long bone like the humerus, to find Lieberkühn's glands, with their tall columnar epithelium.

When rectal cancer invades the peritoneum, this serous membrane will sometimes become dotted over with minute elevations like sago grains.

Carcinoma of the Intestine.—Cancer of the small and large intestine is of the same structure, and has the same relation to the gut, as that which occurs in the rectum. The liability of the various sections of the intestine to cancer varies greatly. In the duodenum, jejunum, and ileum this disease is very rare. When cancer attacks the duodenum it is apt to involve the common bile duct; in a fair proportion of cases it begins around the bile papilla (see p. 295). In the large bowel, excluding the rectum, cancer is fairly frequent, and exhibits a curious tendency to occur at the sigmoid, splenic, and hepatic flexures. The relative frequency with which the various parts of the intestine, from the beginning of the duodenum to the anus, are attacked by cancer may be represented in the following way:—

Fig. 154.—Cancer of the sigmoid flexure of the colon.

Of every one hundred cases, seventy-five occur in the rectum; of the remainder, twenty-three would be localised in the large bowel and two in the small intestine, including the ileo-cæcal valve.

A search through the home literature indicates that few records of cancer of the **ileo-cæcal valve** exist, especially if care be taken to distinguish between cancer of the cæcum involving this valve, and primary cancer of the valve itself. In one remarkable case, cancer of the ileo-cæcal valve caused intussusception, and the valve appeared at the anus. The cancerous valve was cut away, and the vermiform appendix recognised as the peritoneum was opened. The patient, a woman of 75 years, died suddenly ten hours later.* It is also necessary to mention that cases of cellulitis involving the cæcum are sometimes mistaken for cancer. Primary cancer of the **cæcum** is rare, but it is rarer in the vermiform appendix;

* Ball, *Brit. Med. Journ.*, 1903, vol. i. 481.

a few examples have been recorded in this vestigial structure. The literature has been collected by Rolleston.*

Concerning the mode in which cancer of the small intestine, cæcum, and colon begins, nothing is known. The symptoms to which it gives rise are those of obstruction, and diagnosis is, in most cases, a matter of conjecture, mainly based upon the age of the patient and the gradual manner in which the signs develop, when the surgeon arrives at the conclusion that the trouble is due to cancer in some part of the large intestine. As far as I am aware, the diagnosis of primary cancer of the small intestine has not been made, for when seated in the small gut below the duodenum cancer usually gives rise to signs of acute obstruction. From this it follows that our knowledge of intestinal cancer is based upon a study of the disease in its advanced stage. One of its most characteristic features is the way it travels round the gut and forms a zone of hard material projecting into its lumen, and then, as it contracts, the diseased parts, as seen from the outside, look as if the intestine had been girt with a ligature (Fig. 155). In the later stages the lumen of the gut becomes so straitened that nothing but a narrow, tortuous channel traverses the cancerous mass, and this allows the liquid fæces retained in the dilated segment of the gut on the proximal side of the tumour gradually

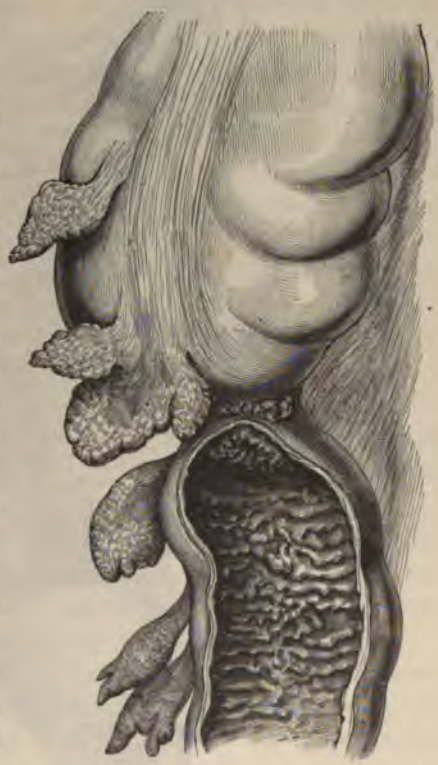

Fig. 155.—Cancer of colon (constricting variety).

* *Lancet*, 1900, vol. ii. 11.

to trickle through, and at times even this limited channel of escape becomes closed. Occasionally, after many days of complete obstruction, a portion of the cancer sloughs, and the

Fig. 156.—A cæcum with the vermiform appendix and adjacent segments of the ascending colon and ileum. The cæcum is occupied with a cancerous mass, which has perforated its mesial wall and not only implicated the adjacent segment of the ileum, but has penetrated its lumen. The parts were successfully resected from a woman æt. 55.

obstruction is temporarily relieved. The enormous quantity of fæces that sometimes escapes on such occasions is almost beyond belief.

A large proportion of patients with intestinal cancer succumb from the effects of obstruction; in others death is brought about by other means. For example, the retention of the contents of the bowel leads to dilatation of the gut above the stricture; this may induce ulceration and gangrene, which terminates in perforation. In this event the effect depends on the part of the gut perforated. Should the opening allow fæcal matter to escape into the peritoneal cavity, peritonitis is the consequence, and as a rule kills the patient in a few hours. In the case of the cæcum, the ascending and descending colon, the extravasation may take place behind the peritoneum and give rise to a fæcal abscess. Such abscesses in connection with the right colon will point in the neighbourhood of Poupart's ligament (usually above, but sometimes below this band), or at the crest of the ileum. I have known pus from an abscess of this kind in connection with the descending colon travel between the muscular planes of the belly-wall as far as the linea semilunaris, and the intestinal gas caused the whole of the left half of the belly-wall to be emphysematous.

In chronic intestinal obstruction due to cancer of the descending colon, the cæcum becomes greatly distended with fluid fæces; this leads to ulceration of its wall, which occasionally perforates and sets up rapidly fatal peritonitis.

It occasionally happens that a distended coil of bowel immediately above a cancerous stricture will adhere to an adjacent piece of healthy intestine, which will be infiltrated by the cancer; sloughing follows, and a fistula forms between the implicated coils. Such an event rarely improves the patient's condition, as the communication almost always takes place with a piece of intestine on the proximal side of the stricture. It has happened to me on three occasions to meet with cancer in the loop of an omega-shaped colon. The convexity of the loop had in two instances come in contact with, and perforated into, the bladder. Uterine cancer sometimes perforates into the peritoneal cavity and implicates the colon; hence care is necessary in discriminating between a cancerous

colon adherent to the uterus and a cancerous uterus implicating the colon. Cancer of the sigmoid flexure is, in a large proportion of cases, localised in that portion of the flexure in relation with the brim of the true pelvis, and it is a curious fact that in such cases the left ovary is often adherent to, and occasionally forms the base of, a cancerous ulcer in this part of the colon.

Briefly summarised, the modes of death in cancer of the intestines are:—Intestinal obstruction, intussusception, perforation into the peritoneal cavity, and suppurative nephritis when the disease is in the rectum and involves the ureters.

Cancer of the Anus.—This is of the squamous-celled variety, and is about equal in frequency to this disease in the scrotum and labia. It is more frequent in women than in men, and rarely begins before the fortieth year. In about half the cases the inguinal glands are affected on one or both sides. When seen in the early stages and its nature recognised, cancer of the anus admits of free and complete removal, and the results of such interference are admirable. In cases where the disease runs its course life is rarely prolonged beyond twelve months; whereas in cases where the growth is satisfactorily removed life has been prolonged several years (five to eight). In cases where the disease cannot be extirpated, the patients are sometimes made more comfortable by diverting the course of the fæces (colotomy).

Treatment.—Cancer of the **rectum** can in many instances be easily and freely excised (proctotomy). A ready way in which surgeons estimate the suitability of a rectal cancer for excision is to introduce the index finger through the anus, and if the tip of the finger passes beyond the tumour it is taken as an indication that, so far as implication of the rectum is concerned, the disease admits of removal. The favourable cases are those in which the cancer is of such limited extent that it can be circumscribed by the finger, is mainly limited to the posterior wall of the gut, and does not involve the anus, prostate or vagina, according to the sex. When rectal cancer is too extensive for excision, patients are often rendered comfortable by inguinal or lumbar colotomy. The routine employment of colotomy for every case of rectal cancer that cannot be excised is to be deprecated.

In the case of the **colon** various methods have been advocated. The ideal operation consists in resection of the diseased area of the gut and sutural union of the cut ends so as to restore the continuity of the intestine.

Another method is to perform *colotomy*, an extremely simple proceeding when the position of the cancer can be ascertained.

In all patients that come under my care with intestinal obstruction, supposed to depend upon cancer of the colon, and in whom no tumour can be localised by physical signs, I prefer to explore the intestines through an abdominal incision, and then perform colotomy or resection, according to the nature and situation of the cancer.

It is also a fact well worth bearing in mind that after the pressure upon a section of colon, straitened by cancer, is relieved by a timely colotomy, the obstruction after a time partially disappears and allows fæces once more to pass into the distal portion of the gut. Indeed, in some cases the passage through the cancerous segment becomes so free that patients allow the colotomy opening to close.

The various methods of performing resection of the bowel, and the results, immediate and remote, are discussed in the admirable works of Treves and Jacobson on Operative Surgery.

CHAPTER XXXII.

EPITHELIAL TUMOURS OF THE LIVER, GALL BLADDER, AND PANCREAS.

THE histological characters of the liver render it possible for epithelial tumours, whether adenoma or carcinoma, to imitate the tubular arrangement of the bile ducts, or the disposition of cells characteristic of a hepatic lobule.

Adenomata.—Fully developed adenomata of the liver are encapsuled tumours of a spherical shape; they may be situated in any part of the liver. Hepatic adenomata vary greatly in size: a solitary adenoma may be no larger than a marble; when multiple they will be as big as Tangerine oranges. In colour some are bright green, others are dull white. The peripheral parts of the tumour consist of solid columns of cells, but on approaching the centre they gradually acquire a lumen. These blind ducts are lined with a single layer of columnar epithelium, and contain an inspissated green-coloured material. As the ducts make up the bulk of the tumour, it is clear that the olive-green colour of the tumour is due to imprisoned bile. In adenomata of this kind the columnar cells are so striking that some observers have described these tumours as columnar-celled carcinomata of the liver (Fig. 160). In other specimens the cells, instead of

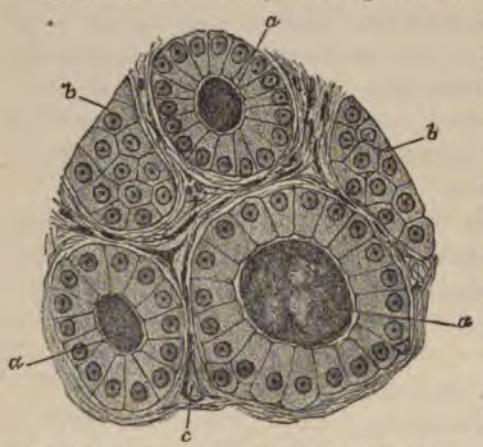

Fig. 157.—Adenoma of the liver. (*After Paul.**) *a*, section of blind duct filled with green fluid; *b*, liver cells; *c*, connective tissue.

* *Trans. Path. Soc.*, vol. xxxvi. 238.

being arranged in this tubular fashion, are grouped around a minute central lumen two or more deep.

So far as our knowledge at present extends, it would appear that hepatic adenomata as described above are of little clinical importance, and they have been found during the performance of a *post-mortem* examination when the liver has been sliced up in the course of the inspection. Keen,* however, has successfully removed a hepatic adenoma, measuring 9 by 6 cm., from a woman thirty-one years of age. The circumstance that such tumours can be dealt with surgically will lead, in all probability, to an extension of knowledge concerning them.

Carcinomata.—Hepatic cancer varies greatly in its external appearance; sometimes it assumes the form of compact nodules of a white colour projecting from the surface of the liver and visible on every cut surface, the nodules varying in size from a marble, or ripe cherry, to tumours as large as and even exceeding the fist. Many of the surface nodules present a central depression or umbilicus.

In other cases the cancer assumes the form of an irregular infiltration of soft growth of an olive green; some of the tracts are yellow. In all cases the liver is enlarged, sometimes to twice its natural size. The surface is in most cases irregularly lobulated.

Dissemination of the cancer is the exception; secondary nodules have been found in the lung, and enlarged lymph glands in the portal fissure; in one of the cases in which secondary nodules occurred in the lung, the mediastinal lymph glands were enlarged and infiltrated with cancer.

In point of structure hepatic cancer conforms to two types, the **tubular** and the **acinous**, but the imitation in the case of cancer is not so good as with hepatic adenoma.

Rindfleisch, in reference to the tubular species of adenoma, writes:—"The peculiar intention which is expressed in the whole foundation advances to a delusive imitation of a tubular gland." The difference between the tubular adenoma and the tubular carcinoma is that the imitation is still more delusive, and this is equally true of that which is called the acinous species.

* *Boston Med. and Surg. Journal*, April 28, 1892.

Clinical Features.—Hepatic cancer occurs equally in men and women, and is most frequent between the fortieth and sixtieth years. It is, however liable to arise at a much earlier age; and Acland * has published an excellent paper on this subject, and collected nine cases of primary cancer of the liver occurring in children under twenty years of age. All observers

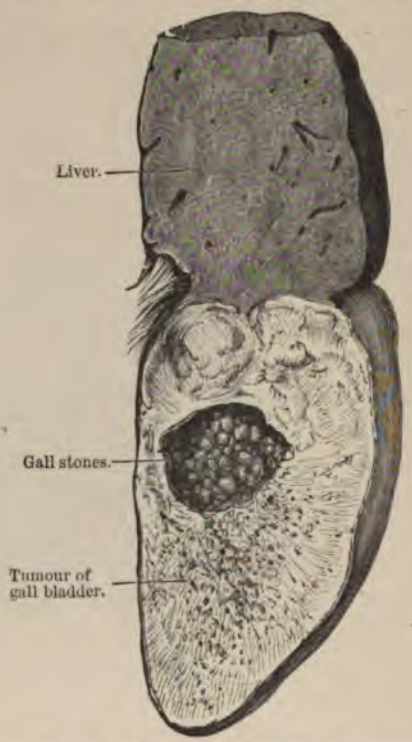

Fig. 158.—Cancer of the gall bladder in section. (*Museum of the Middlesex Hospital.*)

agree that primary cancer of the liver is very rare, and, as is the case with many rare diseases, there is very little reliable evidence forthcoming concerning it.

Cancer of the liver leads to enlargement of this gland and jaundice, which may be slight and transient or of great intensity; in a few it has only been observed towards the termination of life. Ascites occurs in most cases. The available facts indicate that it runs a very rapid course.

* *Lancet*, 1902, vol. ii. 1314; see also Hale White, *Guy's Hosp. Rep.*, 1896.

Secondary Cancer of the Liver.—The liver plays the same part in the portal circulation that the lungs play in the pulmonary circulation when any viscus or organ drained by it is the seat of carcinoma—namely, to act as a filter and deprive it of cancer-emboli. Like the lungs, the liver also offers an extremely favourable territory wherein such emigrants may thrive. Secondary cancerous nodules in the liver attain larger proportions than in the lung. It is a curious fact that in many cases reported as primary cancer of the liver, the nodules were multiple. This is a very exceptional condition in other viscera, and this renders it very important, in reporting a case as primary cancer of the liver, to make a thorough search of the whole intestinal tract, and particularly of the rectum and anus, when conducting a *post-mortem* examination, as well as to make a careful microscopic examination of the hepatic nodules.

Cancer of the Gall Bladder.—There is a fair number of cases recorded in medical literature under the name of cancer of the gall bladder, but it is an unfortunate circumstance that very few of the specimens have been submitted to careful microscopic examination.

The gall bladder is lined with mucous membrane furnished with columnar epithelium, and beset with mucous glands. Recent researches in primary cancer of this receptacle prove, what would be expected from the normal structure, that in the majority of specimens the carcinoma contains columnar epithelium. The disease, however, so alters the normal relations of parts that it is usually difficult to decide whether the carcinoma arises in the glands or the mucous membrane.

Cancer is more common in the fundus of the gall bladder than near or in the cystic duct, but it may arise in this duct. In many specimens the disease infiltrates the walls of the gall bladder and transforms it into a hard solid body, so that it would be difficult often to determine the relation of parts except by finding a central cavity occupied by biliary concretions (Fig. 158). In some specimens the disease projects into the cavity of the gall bladder in the form of villous processes. Occasionally the cancer may be localised to the fundus of the gall bladder, and I have known a process of the tumour to

perforate the wall and form a bud-like projection on the peritoneal coat no larger than a pea; yet the cells detached from this little process had been distributed throughout the peritoneal cavity, and given rise to innumerable tiny nodules on the peritoneum from the diaphragm to the recesses on the floor of the pelvis. Dissemination of this kind is rare. Secondary deposits are more common in the liver. The lymph glands in the fissure of the liver are often infected, and the liver itself is sometimes extensively implicated by the primary tumour.

A feature of great interest in connection with cancer of the gall bladder is its almost constant association with biliary concretions. It has been assumed from this that the calculi are the cause of the cancer, but this, like so many other phenomena connected with cancer in general, cannot be determined. It is, however, noteworthy that primary cancer of the gall bladder is at least three times more common in women than in men, and this agrees with the relative numerical frequency of gall stones in women compared to men. The ages of greatest liability to gall stones and cancer of the gall bladder are the same—namely, from the fiftieth to the sixtieth years. The evidence indicates that if gall stones do not predispose to or even actually cause cancer of the gall bladder, there are some closely allied conditions favourable to the occurrence of each. This is more significant since it has been clearly demonstrated that micro-organisms are the main agents in disturbing the epithelium of the gall bladder, and thus initiating the change in the secretion which precedes the formation of the concretions. Kelynack * has carefully discussed the relation of gall stones to primary cancer of the gall bladder, and collected the literature.

Primary cancer of the gall bladder runs a very rapid course, and is usually fatal within six months from the onset of symptoms. The chief signs are the presence of a hard but tender tumour in the region of the gall bladder, accompanied by epigastric pain. Jaundice occurs in about one-third of the cases.

Cancer of the Common Bile Duct and its Papilla.—Primary cancer of this duct is an excessively rare affection, especially when care is taken to exclude the cases in which it is implicated by cancer of the head of the pancreas and primary

* *The Practitioner*, April, 1896.

cancer of the duodenum. There are cases carefully observed and reported which prove that cancer may arise primarily in the common duct. An example occurred in the Middlesex Hospital in a woman 50 years of age. The cancer arose from the wall of the common duct, occluded its lumen, and caused the gall bladder and the hepatic ducts to be distended with bile; the gall bladder contained many gall-stones.*

When primary cancer arises in the duodenum it is apt to surround the bile papilla. Halstead † has recorded a case of this kind in a woman 60 years of age. He excised the cancer, the bile papilla, and adjacent section of the common duct, and implanted its cut end into the duodenum. The patient recovered, but died several months later from recurrence of the cancer in the duodenum and pancreas.

Treatment.—The operative treatment of cancer of the liver and gall bladder has been carried out in a fair number of cases with some success. The literature has been collected by Terrier and Auvray,‡ Keen,§ and Thompson.‖

Cancer of the Pancreas.—This is an affection of peculiar interest, because it is in itself very insidious, and rarely becomes clinically recognisable except when it attacks the head of the pancreas. Its chief clinical manifestation then depends mainly on environment, for it implicates the termination of the common bile duct and causes obstructive jaundice. Cancer of the pancreas attacks the head of the gland six times more frequently than its tail. In one unusual case a cancerous deposit has been found in the head and tail of the same pancreas (Hale White).¶ The difficulty of recognising cancer in the head of the pancreas is increased by the fact that the tumour, though it scarcely exceeds the dimensions of a medlar, is sufficient to obstruct the bile duct, yet is not large enough to be appreciable to manipulation through the abdominal wall of a living individual.

Cancer of the pancreas forms a sort of indefinable hardness

* *Middlesex Hosp. Rep.*, 1880, 116.
† *Johns Hopkins Hospital Bulletin*, January, 1900.
‡ *Revue de Chirurgie*, 1898.
§ *Annals of Surgery*, Sept., 1899, 267.
‖ *Annals of Surgery*, Sept., 1899, 284.
¶ *Clinical Journal*, vol. xvi. 97.

in the gland, and was formerly called "scirrhus of the pancreas"; sometimes it forms a tumour as big as a fist. Microscopically the tissue of the tumour is simply a caricature of the gland tissue.

The disease is rare before middle life, and it attacks both men and women. The chief manifestation, save in quite the late stages, is deep jaundice, often unaccompanied by pain. As the disease progresses and the jaundice deepens, an oval tumour is sometimes appreciable in the right lumbar region; this is the over-distended gall bladder, and it is painless to touch. In a certain proportion of cases a second swelling can be made out in the region of the head of the pancreas. This disease is rarely a source of pain, but in some cases the late stages of cancer of the pancreas are accompanied by much suffering.

It would be interesting to determine how far the lethal effects of the cancer are hastened by the associated jaundice. That cancer of the pancreas is fatal is proved by the fact that when the disease is situated in the body of the gland, it would appear to run almost as quick a course as when the bile duct is implicated.

Occasionally dissemination occurs in cancer of the pancreas; * the gland is itself rarely occupied by secondary deposits of cancer.

Treatment.—The insidious character of the disease, the almost inaccessible situation of the gland, and the large blood and lymph vessels in its neighbourhood, do not favour surgical enterprise. On one occasion I diverted the bile into the bowel by anastomosing the distended gall bladder with the hepatic flexure of the colon in a case of pancreatic cancer with jaundice, hoping that if the biliary outflow could be re-established life might be prolonged. It was not successful.

In order to secure the full benefit of an operation upon a cancerous pancreas, it would be essential to remove the whole gland. This in itself would be physiologically disastrous, because experiments on animals demonstrate that complete extirpation of the pancreas is followed by diabetes.

* Percy Kidd, *Trans. Path. Soc.*, vol. xxxiv. 136; Norman Moore, *St. Barth. Hosp. Rep.*, vol. xvii. 205.

CHAPTER XXXIII.

CARCINOMA OF THE URINARY ORGANS.

EVERY part of the urinary system is liable to cancer—kidney, ureter, bladder, prostate, and urethra. It is common in the

Fig. 459.—Cancerous kidney in section. From a man 54 years of age.

bladder; next in order of frequency come the complex glandular organs—the kidney and prostate. It is rarest in the conduits—the ureter and the urethra.

We shall find it convenient to consider each part in anatomical sequence, beginning with the kidney.

Cancer of the Kidney.—Carcinoma of this organ starts in the epithelium of the uriniferous tubules, and gradually transforms the renal tissue without violently distorting the shape of the gland (Fig. 159). The cancerous tissue creeps into the pelvis of the kidney and invades the ureter, extending sometimes the whole length of the duct, and the outrunner has been observed to enter the bladder. This relation of the

Fig. 160.—Microscopic characters of renal cancer.

carcinoma to the ureter explains the frequency of hæmaturia as a concomitant of this disease.

The minute characters of renal carcinoma are very striking, and consist of tubules lined with regularly arranged columnar epithelium (Fig. 160), and the general arrangement of these tubules in microscopic sections presents "a rough but striking resemblance to the tubular structure of the kidney" (Sharkey).

Our knowledge of the general characters of renal carcinoma is very limited, because it is only during the last ten years that any serious efforts have been made to separate the epithelial malignant tumours (carcinoma) of the kidney from the connective tissue (sarcomatous) tumours, which are by far the most common form of malignant tumours that attack this gland.

Renal carcinoma is uncommon before middle life and increases in frequency after the fiftieth year, and is usually limited to one kidney. The unilateral character comes out strongly when the disease attacks a horseshoe kidney, for even under these conditions it remains restricted to one half of the compound gland (Fig. 161).

Cancer of the kidney is a very deadly disease, and a careful

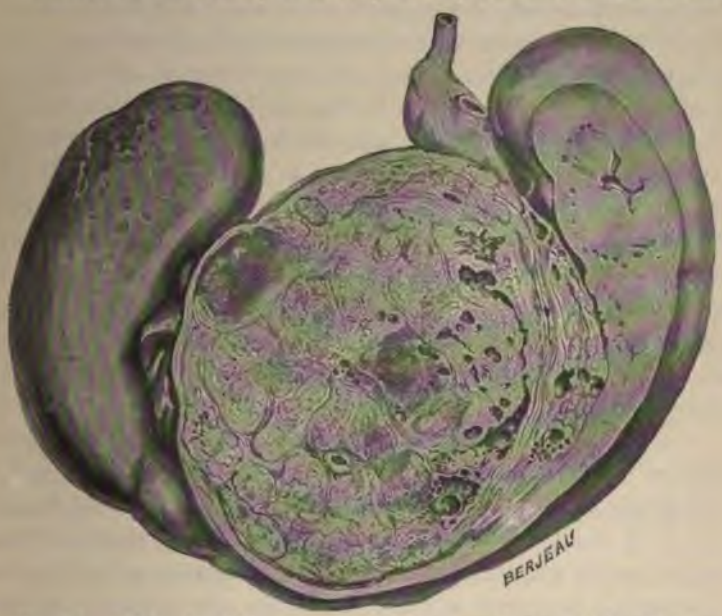

Fig. 161.—A horseshoe kidney; one half of the organ is the seat of carcinoma. (*Museum, Royal College of Surgeons.*) From a woman 60 years of age.

study of the records relating to cases in which the histology of the tumour was carefully determined shows that more than half the cases in which the kidney was removed die from the direct effects of the operation. This is partly due to the exhausting effects of the cancer and hæmaturia upon individuals advanced in life. Of the patients that recover from the operation, I know of no record where life was prolonged more than a year.

Cancer of the Ureter. The terminal orifices of ducts are not uncommon situations for primary cancer, *e.g.* the duodenal end of the bile duct, the urethral orifice in both sexes, and the vesical as well as the dilated or pelvic portion of the ureters.

It is, however, rare for cancer to arise in any part of the ureter between the renal pelvis and the bladder. Voelcker * has recorded a case in which a primary carcinoma arose in the right ureter at the spot where it crosses the brim of the pelvis. The patient, a man sixty-eight years of age, came under observation on account of hæmaturia. At the *post-mortem* examination a tumour as big as a cherry, which on microscopic examination furnished the characters of carcinoma, was found in the ureter. The lymph glands on the corresponding side of the aorta were infected. There was a large secondary mass of cancer in the liver and there were nodules in the right lung, which agreed in their microscopic characters with the tumour in the ureter.

Cancer of the Bladder.—In this viscus cancer is of the squamous-celled variety, and arises in the mucous membrane. From what is known of the habits of this disease elsewhere, it would be anticipated that in a certain proportion of cases it would begin at the orifices of the ureters. This is actually the case; but it must not be assumed that when the ureteral orifices are found involved in the late stages that the disease originated at these orifices.

Cancer of the bladder seems to be more common in women than in men. The signs of its presence are hæmaturia, painful micturition, and cystitis. Such signs are, of course, equivocal, and it is usual to demonstrate its existence by means of the cystoscope, or a cystotomy in men, and dilatation of the urethra in women. It is very unusual before the age of forty. Death results from renal complications, exhaustion from repeated bleeding, bodily suffering, and frequent micturition.

Treatment.—Operations on the bladder are of two kinds: (1) those which are performed to relieve the patient of the frequency of micturition and the attendant pain, and (2) those which are directed to the extirpation of the cancer.

Operations of the first kind consist of cystotomy, either through the perinæum or above the pubes. I have found the best consequences follow a suprapubic opening. The urine flows away as soon as it enters the bladder, and the patient soon learns to manage the necessary tube and receptacle, and is not obliged to remain in bed.

* *Trans. Path. Soc.*, vol. xlvi. 133.

The more radical treatment consists of either removal of the tumour with the implicated segment of the bladder, or complete extirpation of the viscus. In the case of women the ureters have been diverted into the vagina, and in the case of men into the rectum. It is a fact of some value that the rectum will accommodate a fairly large quantity of urine under such conditions. The results of complete removal of the bladder are not encouraging.* Partial resection of the bladder is attended with better consequences, especially when the tumour is situated on or near its summit. Operative treatment of bladder tumours is necessarily restricted, because in the majority of cases the tumour arises in the vicinity of the ureteral orifices.

Epithelial Tumours of the Prostate.—Strictly, the prostate is an appendage of the genital system, but it is more convenient to discuss tumours of this gland in connection with the urinary organs.

After the age of fifty years the prostate is liable to become greatly enlarged; this increase in size may depend upon aberrant growth of its muscular tissue leading to the formation of sarcomata (see p. 116), or upon changes originating in the epithelium giving rise to adenoma or cancer.

Adenoma.—It is by no means rare for the glands in the prostate to enlarge late in life, so that the organ becomes increased to twice or thrice its natural size; but there is a variation in the disposition of the glandular elements of the prostate that not unfrequently renders the change peculiarly disastrous. Commonly the glands in the prostate are arranged in each lateral half of the organ in such a way that their ducts open into the urethral channel in the recess, or prostatic sinus, on each side of the verumontanum. In a small proportion of cases a collection of glands is situated posteriorly to the verumontanum, and in such a way as to serve as an isthmus uniting the glands in the lateral lobes of the prostate. This arrangement of glands has been particularly studied by J. Griffiths.† When a prostate in which this third group of glands exists becomes adenomatous, the median group also enlarges, and in many cases projects into the channel of the urethra and narrows its vesical orifice

* Tuffier et Dujarier, *Rev. de Chirurgie*, 1898, 278.

† *Journal of Anat. and Phys.*, vol. xxiii. 374.

(Fig. 162). In a typical case, an adenoma of this kind consists of a narrow portion occupying the prostatic urethra and a prominent part protruding into the bladder, so that its relation to the urethra resembles that of a cork in the neck of a champagne bottle. These median prostatic adenomata are covered by mucous membrane dotted with minute holes, which represent the orifices of glands embedded in the tumour (Fig. 163). Small and thoroughly innocent in so far as structure is concerned, this variety of prostatic adenoma often acts so efficiently as a plug

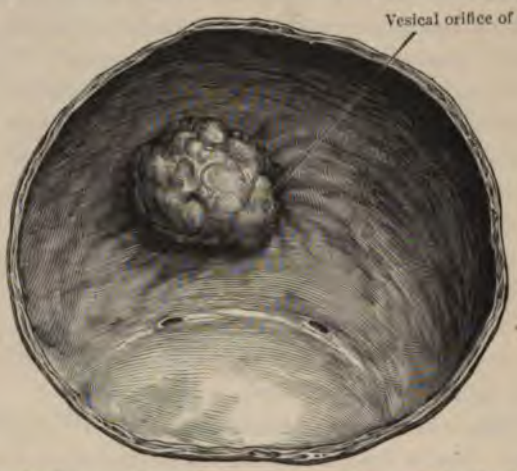

Fig. 162.—Median prostatic adenoma, sketched from within the bladder. From a man 60 years of age.

to the urethra as to cause complete retention of urine, with all its evil consequences.

Bryant * has described two cases in which, during the performance of lateral lithotomy, a median prostatic adenoma was accidentally included in the shanks of the forceps, in the act of grasping the stone, and torn off as the instrument was withdrawn. He refers to a similar case in Fergusson's practice. Reginald Harrison has also published an instructive paper on this subject.†

Carcinoma.—The prostate is rarely affected by cancer, and this is almost entirely confined to old men. As the disease advances it extend beyond the prostate and infiltrates the

* *Trans. Path.. Soc.*, vol. xxix. 164.
† *Med.-Chir. Trans.*, vol. lxv. 39.

tissues around the base of the bladder. The pelvic lymph glands become infected, and frequently dissemination occurs.

Silcock * has given a careful account of a case of prostatic cancer in which dissemination occurred. The patient was sixty-one years old. Recklinghausen † has published five valuable cases of prostatic cancer; the men were between seventy-two and seventy-seven years of age. It would appear that secondary deposits in bone is a very constant feature of prostatic cancer. This is interesting in relation with the peculiar

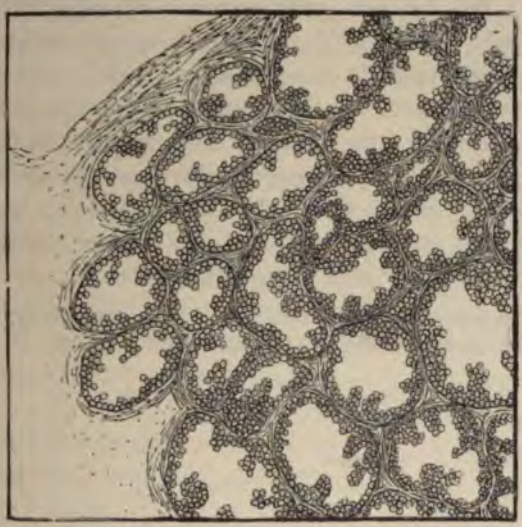

Fig. 163.—Microscopic characters of a prostatic adenoma.

deposits in the osseous system associated with some enlarged thyroid glands (see page 264).

Treatment.—Since McGill introduced a method of dealing with the obstruction to micturition due to an enlarged middle lobe of the prostate, by opening the bladder above the pubes and excising the obstructing lobe, surgeons have extended the operation and enucleated adenomata from the lateral portions of the prostate. Freyer ‡ has proved that the prostate can be removed entire through a suprapubic opening.

* *Trans. Path. Soc.*, vol. xxxv. 244.

† *Festschrift* to Virchow, on his 71st birthday, 1891.

‡ *Brit. Med. Journ.*, 1901, vol. ii. 125.

His work has been attended with such success that it will abolish unsatisfactory operations like bilateral castration and vasectomy performed with the hope of inducing atrophy of enlarged prostates. Radical treatment of *cancer* of the prostate is beyond surgical art.

Cancer of the Urethra.—This is an extremely rare situation for cancer. Nevertheless, there are some carefully recorded cases.* The disease is of the squamous-celled variety, and usually arises in that part of the urethra in relation with the bulb. The patients were between the ages of fifty and seventy-three. The trouble in each instance attracted attention as a hard mass in the perinæum which interfered with micturition, and attempts to pass a catheter provoked great pain and induced free bleeding. The obstruction increased until the urethra became impermeable, and fistulæ formed in the perinæum. In most of the cases perinæal section was performed, and the cut surface of the tumour had a greyish-white appearance and was extremely brittle.

* Griffiths, *Trans. Path. Soc.*, vol. xl. 177. Beck, *International Clinics*, vol. ii. 256. Witzenhausen, Bruns' *Beiträge*, bd. vii. 571.

CHAPTER XXXIV.

CARCINOMA OF THE EXTERNAL GENITAL ORGANS.

THE greater part of the external genital organs are directly continuous with and derived from the skin; it therefore comes about that they are liable to squamous-celled cancer. In some parts the skin glands are specialised and are the sources of glandular types of cancer, *e.g.* Tyson's glands of the penis and Bartholin's gland of the labium.

Cancer of the Scrotum (Sweep's Cancer).—This appears on the scrotum in the form of a wart or warts; they are often spoken of as soot-warts, for they not only occur on the scrotum of the chimney-sweep, but are met with in men who are brought much in contact with soot. In many cases the scrotal wart is harmless, but in a certain proportion of cases it grows slowly, or if multiple one becomes more prominent than its fellows and ulcerates. The ulceration, at first limited to the wart, extends to the surrounding skin and forms a cancerous ulcer, which will extensively involve the scrotum, spread thence to the skin around the anus and pubes, and even to the thigh. In some cases the ulceration, instead of spreading widely, involves the tissues deeply, so that the tunica vaginalis is exposed and sometimes implicated in the disease; but this is rare.

The inguinal glands become infected and attain a large size; then slowly involve the skin, break down, and ulcerate. This process often leads to the formation of deep excavations in the groin, and it not unfrequently happens that the femoral or the external iliac artery, or both, will be seen exposed and pulsating on the floor of one of these deep pits. It is not uncommon in such cases for the ulceration to open up one of these large vessels, and violent fatal hæmorrhage is the result.

It has been stated by several writers that in chimney-sweeps cancer may begin in the inguinal glands. There can be little

doubt that such views arise in imperfect observation. In some of these cases the lesion on the scrotum assumes the form of a small hemispherical pimple no larger than a split pea, so small indeed that I have known them to escape very vigilant eyes; and yet such a small lesion will cause the inguinal lymph glands to grow into a mass as big as two fists. Two such cases have come under my own notice.

A very remarkable feature connected with cancer in English chimney-sweeps is, that they are not more prone to it in other parts of their bodies than those persons who follow other occupations; yet the scrotum, which in other individuals is the part least disposed to cancer, is in sweeps so very liable to become the seat of this disease. No answer to this problem is at present forthcoming; neither has anyone succeeded in assigning a reason why it is so very much more frequent in English chimney-sweeps than in sweeps of other nations.

There is good reason to believe that tar and paraffin are liable to produce an affection of the scrotum similar to sweep's cancer. Such cases are, however, very rare. The literature has been summarised by Butlin.*

Treatment.—This consists in the free removal of the disease whenever it is practicable; the very best results follow the excision of a soot-wart in its earliest stages. When the disease is permitted to extend deeply into the tissues of the scrotum, so that it is necessary to excise one or both testicles with the scrotum, and perhaps a portion of the neighbouring skin, it is not probable that lasting benefit will follow the operation. In cases where soot-warts have been early and thoroughly removed there is good ground for the belief that a cure is sometimes brought about.

Cancer of the Testis.—Formerly it was the fashion to describe all malignant tumours of the testicle as cancer; of late years it has been ascertained that by far the greater number are sarcomata.

As to whether adenomata and cancers that caricature the secreting structure occur in the testicle, nothing definite is known. So far I have been unable to recognise such a specimen. There is a variety of adenoma that originates in the paradidymis;

* *Brit. Med. Journ.*, 1892, vol. i. 1341, and vol. ii. 68

it is very similar in structure to a renal adenoma, but it is in no way connected with the secreting tissue of the testicle.

Malignant tumours of the testis require careful investigation, conducted on a full supply of material, accompanied by complete clinical histories.

Cancer of the Penis.—This disease may attack the prepuce or the epithelial investment of the glans. The disease is excessively rare before the age of thirty years, and appears to be most common between the ages of fifty and seventy. There is reason to believe that phimosis, congenital or acquired, is a condition that favours the development of cancer of the penis. It is certainly true that phimosis, by leading to the retention of smegma, is indirectly a cause of penile warts not only in men but other mammals, especially horses and bulls. Mention has already been made of the fact that penile warts are particularly prone to be transformed into wart horns, and cases have been recorded in which men have had a wart horn on the penis for several years, and at length its base has become the starting-point of cancer. It must be remembered that cancer may begin as an ulcer on the penis, but the warty variety is by far the most frequent. When the disease begins as an ulcer, it is very liable to be mistaken for some manifestation of primary or tertiary syphilis. On the other hand, very great care must be taken not to mistake a breaking down gumma of the glans penis for cancer.

Cancer, in whatever form it commences, gradually involves and as surely destroys the penis, implicates the scrotum, and infects the inguinal lymph glands on each side; in many cases the lumbar glands also become infected. Secondary deposits seem to be rare. The duration of life in this disease is very uncertain. As a rule, its course is short—six months to a year; but in many cases it is much longer. When the urethra is involved this passage is liable to become narrowed, and not unfrequently urinary fistulæ add to the patient's misery.

The penis is also liable to a rare species of cancer constructed on the type of the specialised sebaceous glands named after Tyson. I once had an opportunity of studying such a tumour in a man fifty years of age; it sprang from the penis and was confined to the corona glandis. The penis was amputated and

the infected lymph glands enucleated from both groins, but the patient died nine months later with the signs of secondary deposits in the abdominal viscera, but no dissection was permitted. Sections were prepared from the tumour in such a way as to include the glans penis, its corona, and the tumour; in this way the relation of the cancer to Tyson's glands was clearly demonstrated.

Carcinoma of Cowper's Glands.—These structures are liable to inflame and become cystic, and there is also reason to believe that the gland may become cancerous. The most recent contribution to the subject is by Witsenhausen.*

Treatment.—Cancer of the penis is treated by partial or complete removal of this organ, according to the extent of the disease. Partial removal of the penis is a simple proceeding, and entails but little risk so long as the cut end of the urethra is stitched to the skin. When the disease is so extensive as to demand complete removal of the penis, the operation which gives best results consists in excising not only the corpus spongiosum and corpora cavernosa, but the penile crura as well, by detaching them from the pubic arch. The urethra is brought out and attached to the incision in the perineum. In all cases where it is justifiable to amputate or extirpate the penis for cancer the infected inguinal lymph glands should be thoroughly removed. The published results of this complete operation are very good, and my experience of it has been in every way satisfactory. The ultimate results of amputation of the penis are more favourable after partial than after complete removal of organ, simply because the disease is not so advanced when partial amputation is sufficient.

Cancer of the Vulva and Vagina.—The variety of cancer which attacks the external genital organs of the female is, with the exception of Bartholin's glands, squamous-celled.

Collectively, cancer of these parts is not uncommon, but when each part is individually considered, then it is comparatively rare, but the disease is more frequent in the labia than in all other parts of the genital passage taken together.

* Bruns' *Beiträge*, bd. vii. 582

The Labia Majora and Minora.—Carcinoma may begin on any part of the labia, but it generally attacks the opposed, or so-called mucous surfaces. In many cases this is preceded by leucoplakia, which resembles in many respects lingual leucoplakia, and I have satisfied myself that it is occasionally a sequel of syphilis.

In order to give some idea of the relative infrequency of vulval cancer, I find that at the Chelsea Hospital for Women, where the yearly average of operations on the female genital organs is 500, labial cancer comes under observation about twice in a thousand cases.

The disease runs a course very similar to squamous-celled cancer of the scrotum, and it is a singular fact that two cases of cancer of the labium have come under my notice in the wives of chimney-sweeps. When recognised in the early stages, prompt and free excision and removal of the infected inguinal lymph glands is followed by much the same success which attends operations upon cancer of the lip. My own experience is that the majority of cases come under observation at a stage when the disease is too far advanced for excision to be of any service.

The Clitoris.—Cancer of this organ is very rare indeed; only one case has come under my notice, and in this the disease began at the free extremity of the clitoris, in a woman forty-five years of age.

The treatment consists of free removal of the clitoris and its crura, and removal of infected inguinal lymph glands. If the operation is carried out before the disease has extended to the nymphæ, labia, or mons, the outlook for the patient is favourable.

The Vagina.—Carcinoma may attack any part of the mucous membrane lining this canal, but it is much more prone to begin at the vulvo-vaginal junction. In the majority of cases which have come under my observation the cancer has been in the immediate vicinity of the urethral orifice. In every instance the patients were past middle life, and one was seventy-three. The inguinal lymph glands are early infected. The cancer quickly implicates the vesico-vaginal septum and leads to fistula, and when it attacks the posterior wall it causes a

recto-vaginal fistula. In one case the urethral orifice became blocked with cancerous granulation, and retention of urine was a very distressing symptom.

In the early stages cancer of the vagina produces such little inconvenience that the patients do not seek advice until the disease is far advanced. Surgery can do little in cancer of the vagina, for even in the very early stages free removal may anticipate some of the evils of the disease by establishing a vesical or a rectal fistula.

Carcinoma of Bartholin's Glands. — It is well known that these glands are very liable to become cystic; they are prone, too, to septic infection. They are also occasionally the source of cancer. Schweizer has reported a case and collected the literature.*

* *Arch. für Gyn.*, bd. xliv. 322.

CHAPTER XXXV.

EPITHELIAL TUMOURS OF THE UTERUS.

EPITHELIAL tumours of the uterus arise in the glands of the endometrium, except squamous-celled cancer, which is limited to the vaginal portion of the cervix. It will be convenient, on anatomical as well as on clinical grounds, to consider them in two sections, namely, those which arise in the epithelium of the cervix, and those originating in the endometrium of the body of the uterus.

THE CERVICAL ENDOMETRIUM.

Adenomata.—The cervical canal is lined with columnar epithelium and furnished with numerous racemose glands. Adenomata, which are structurally repetitions of these glands, are very common at the neck of the uterus. There are three varieties: sessile, pedunculated, and racemose adenomata.

A sessile adenoma appears as a soft velvety areola around the os; it is in colour like a ripe strawberry, and thickly dotted with minute spots of a brighter pink. This pink tissue is composed of glandular acini lined with large, regular, columnar epithelium. The glandular tissue often extends beyond the margins of the os and invades the vaginal portion of the cervix. Sometimes it is so abundant that the apex of the cervix, instead of being a cone, assumes rather the shape of the under surface of a mushroom. The glandular mass is not confined to the margins of the os, but extends for a variable distance up the canal. When adenoma affects a lacerated cervix the whole of the exposed portion of the canal is involved. The surface of a sessile adenoma is covered with tenacious mucus secreted by the abnormal glands.

Pedunculated adenomata are rarely large: they may grow from any part of the cervical canal, but are most frequently found springing from the lower 2 cm. of the canal. As a rule they occur singly, but two or more may be present. They are

soft and velvety to the touch, and are dotted with minute pores. Histologically, they consist of an axis of fibrous and sometimes muscle tissue, covered with mucous membrane continuous with that lining the cervical canal. When these pedunculated adenomata remain within the canal, the epithelium covering them and the glands they contain are of the same character as those of the cervical mucous membrane. When the tumours increase in size and project into the vagina, the epithelium covering the protruding portions becomes stratified, and the glands disappear.

Carcinoma of the Neck of the Uterus.—This part of

Fig. 164.—Microscopic characters of the epithelium covering the vaginal aspect of the neck of the uterus.

the uterus is liable to squamous-celled and columnar-celled cancer, according to the situation in which it arises. When the disease begins on the vaginal aspect of the neck of the uterus, it is of the squamous-celled species ; if its origin is in the cervical endometrium, the cells will be columnar. The difference in the characters of the epithelium in these two situations is shown in Figs. 164 and 165.

A large amount of energy has been devoted to the microscopic examination of cancer of the neck of the uterus, with the hope of determining the relative frequency of squamous-celled and of the columnar-celled variety. So far as my own efforts are concerned, they were directed with the object of deciding, if possible, which variety gave the

best results to operation; but after a long and laborious investigation I came to the conclusion that it was hazardous to attempt a prediction simply on the cell features of the cancer.

Although the ultimate results of cancer arising in the cervical endometrium, or on the vaginal aspect of the cervix, are the

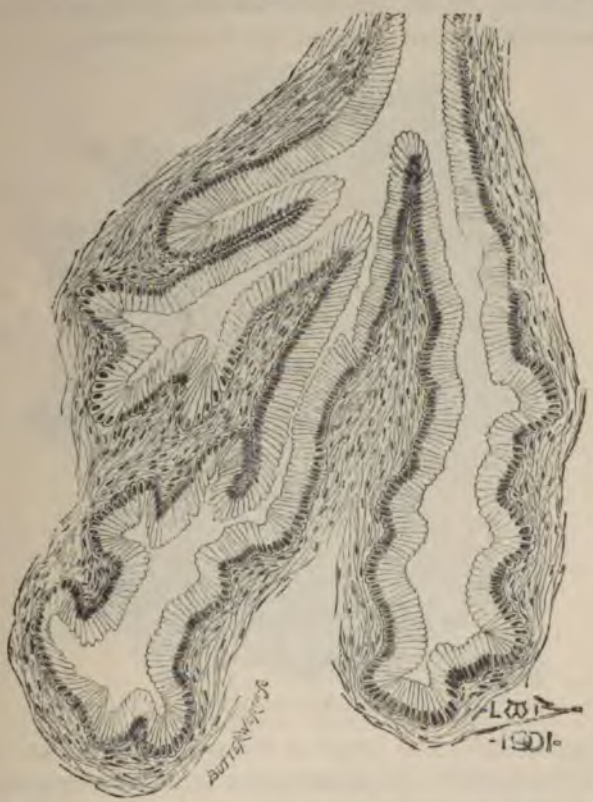

Fig. 165.—Microscopic characters of a gland from the cervical endometrium.

same, it will be advisable to discuss their pathologic features separately. In the majority of patients who come under observation, particularly in hospital practice, the disease has already destroyed, or eroded, the neck of the uterus to such an extent that it is impossible to determine whether it arose in the cervical canal or on the vaginal surface; nevertheless, patients do occasionally come under observation at a sufficiently

early stage to enable an exact localisation of the primary focus of the disease to be made. In this way it has been determined that squamous-celled cancer of the cervix begins in much the same way as on the lips or tongue. It may appear as a circular ulcer with raised and everted edges, or may erode the tissues deeply at the outset; exceptionally it forms luxuriant warty excrescences. The cancer infiltrates the cervix, extends to and implicates the vaginal wall, and involves the tissues of the meso-

Fig. 166.—Microscopic characters of cancer of the cervix.

metrium. Cancer also arises in the epithelium in any part of the cervical canal or its glands, but it appears to be more prone to arise in the lower than in the upper half of the canal. It begins either as a deeply-eroding ulcer, or as a soft, fungating, vascular, cauliflower-like outgrowth. Commonly the cancer, after infiltrating the adjacent tissues of the cervix, spreads into the mesometrium and implicates the vaginal wall. It ulcerates early, and destroys the cervix and spreads into the body of the uterus, and in the late stages this organ may become hollowed out by ulceration until nothing but a thin layer of muscle tissue covered by peritoneum remains.

The microscopic features of cancer arising in the cervical epithelium consist of round spaces filled with columnar epithelium. This is due to the fact that the invasion of the tissues is due to columns of epithelium, and in the microscopic sections these cell columns are represented cut at right angles (Fig. 166).

Cancer of the cervix leads to infection of the lumbar lymph glands. Dissemination is also frequent, and secondary deposits

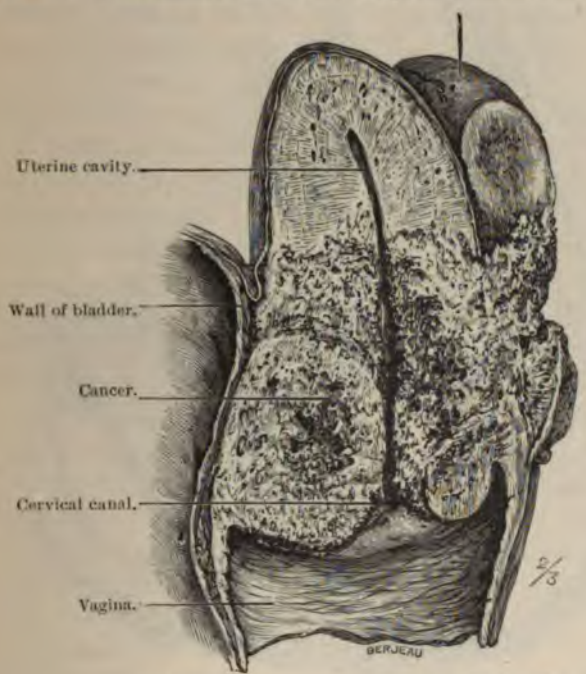

Fig. 167.—A cancerous uterus in sagittal section.

form in the lung, liver, and occasionally in the bones, but not with the same frequency as in cancer of the breast. Cancer of the cervix leads to perforation of the anterior and posterior vaginal septa, so that urinary and fæcal fistula are apt to complicate the late stages of the disease (Fig. 168).

When the broad ligaments are extensively infiltrated the ureters become involved; this leads to dilatation of the renal pelves. As cystitis is a common complication of carcinoma of the cervix, this, in conjunction with the interference with the ureters, serves to explain the almost constant presence of

suppurative pyelitis and nephritis found during *post-mortem* examinations of women with uterine cancer. A very large proportion of these patients exhibit marked uræmic symptoms in the later stages of their lives.

Among other complications of cancer of the cervix, especi-

Fig. 168.—Pelvis and its viscera in section. From a case of cancer of the uterine cervix which invaded the bladder.

ally when it extends to the body of the uterus, must be mentioned pyosalpinx and hydrosalpinx. In these cases the dilated tubes are rarely thicker than the thumb, but they are a source of danger, inasmuch as perforation occasionally occurs and sets up infective peritonitis. Exceptionally the cancer perforates the body of the uterus. When this happens peritonitis may ensue and quickly cause death; in some instances the carcinomatous material becomes distributed over the peritoneum, and small knots form upon the serous surfaces of the

intestine, liver, spleen, etc. This distribution of the cancer may lead to an effusion of blood-stained fluid into the belly, sometimes in considerable quantity, or to agglutination of coils of intestine, each cancerous nodule being the focus of a limited area of peritonitis. Occasionally actual perforation of the uterus is prevented by a piece of intestine becoming adherent to the uterus at the spot where the disease is approaching the surface: adhesion in this way may take place between the uterus and small intestine.

It is important to bear this in mind, because when a fæcal fistula complicates cancer of the uterus it is usually attributed to a communication with the rectum or sigmoid flexure, and these are the common situations; but in some cases the fistula is in the transverse colon, for when this section of the large bowel is omega-shaped the lower segment of the loop often comes in contact with the fundus of the uterus.

Cancer of the cervix uteri is very common between forty and fifty; many cases occur between thirty and forty. Before thirty the disease is rare, but I have observed undoubted cases in women of twenty-three, twenty-five, and twenty-six years of age. It belongs especially to the latter part of the child-bearing period of life; *it is almost exclusively confined to women who have been pregnant.* Whether it be due to delivery or to the traumatism of the cervix associated with coitus I cannot determine; in the only exception to the rule mentioned above which has come under my observation the patient was married.

A remarkable record bearing on this matter has been published by Czerwenka.* A woman thirty-five years of age had a double vagina and uterus bicornis bicollis. Coitus was practised in the left vagina. The left cervix was cancerous, the left uterus contained two fibroids, and the corresponding Fallopian tube contained pus and had its cœlomic ostium occluded.

The signs of cancer of the cervix are bleeding, offensive discharges, and sometimes pain. The first two signs are those which usually lead women to seek advice.

In the early stages the margins of the "os" will be found everted, and a fungous mass protrudes from the canal, which bleeds on the slightest touch. In the late stages, when the

* *Centralbl. f. Gyn.*, 1900, No. 7.

neck of the uterus is destroyed and replaced by an ulcerating cancerous mass, there is no difficulty in recognising the nature of the lesion. Cancer of the uterus terminates in a variety of ways :—

1. The uterine artery may be opened by ulceration, and fatal hæmorrhage ensue.

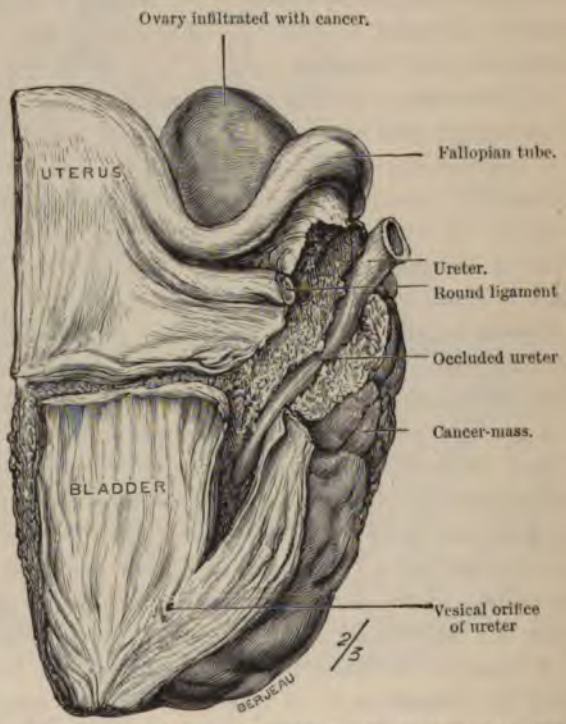

Fig. 169.—Cancer of the neck of the uterus implicating the bladder and ureter.

2. Repeated bleeding due to smaller arteries being eroded will often lead to exhaustion and death.

3. Implication of the bladder and one or both ureters causes cystitis, septic pyelitis, and uræmia (Fig. 169).

4. Septic changes in the uterus extend to the Fallopian tube, and cause pyosalpinx.

5. Peritonitis may be caused by rupture of a pus-containing Fallopian tube.

6. Intestinal obstruction may follow adhesion of a piece

of small or large intestine to the uterus, or direct extension of the cancer into the rectum.

7. Hydroperitoneum and hydrothorax may arise from the presence of secondary nodules of cancer on the peritoneum or pleura.

8. The cervical canal sometimes becomes occluded, and the cavity of the uterus becomes distended with pus (pyometra). The chief danger in this complication is due to the Fallopian tubes becoming secondarily distended with pus, and this occasionally leaks into the peritoneum with lethal results.

Cancer of the cervix is sometimes complicated with other primary lesions of the genital organs. For instance, it may co-exist with an ovarian cyst, and though the combination is rare, I have seen it on three occasions.

Carcinoma of the Cervix and Pregnancy.—It may be stated without fear of contradiction that the most appalling complication of pregnancy is cancer of the cervix. It is somewhat difficult to understand how a woman with cancer of the neck of the uterus can conceive, but it is quite certain that it happens, and that the complication is not uncommon. However, cases in which cancer in this situation obstructs delivery are unusual, and this is due to two circumstances :—

1. The cancer predisposes to abortion.
2. When it has advanced to such a stage as to fill the vagina with an obstructive mass, it has such an effect upon the health of the mother that it endangers the life of the fœtus.

The second condition is of importance, because in considering the advisability of Cæsarean section in these circumstances it is well to be satisfied that the fœtus is alive. However, in very exceptional cases it has been found necessary to resort to this operation in order to deliver a dead and putrid fœtus.

The careful study of the literature relating to this complication shows clearly enough that when a pregnant woman with early cancer of the uterus comes under observation in the early months her best hope lies in vaginal hysterectomy. In the later stages (fourth to the seventh month) very good consequences have followed amputation of the cervix, and this operation has been successfully performed without disturbing

the pregnancy. In the latest stages the best consequences have followed the induction of labour and the immediate performance of vaginal hysterectomy—for, surprising as it may seem, the uterus enlarged by the pregnancy can be safely extirpated through the vagina.

These methods of treatment only apply to cases where the cancer is in such a condition as to afford reasonable hope of a prolongation of life. When the disease is in an inoperable stage and the fœtus is dead, then after a little patient waiting abortion usually occurs. When there is reliable evidence that the fœtus is alive, then the pregnancy should be allowed to go to term; if the cancer affords an impassable barrier to the transit of the child, then Cæsarean section becomes a necessity.

CHAPTER XXXVI.

EPITHELIAL TUMOURS OF THE UTERUS (*concluded*).

ADENOMA AND CARCINOMA OF THE CORPOREAL ENDOMETRIUM.

Adenomata.—These occur as pedunculated tumours, and have an appearance very similar to rectal adenomata; it is



Fig. 170.—The tubular glands of the corporeal endometrium in transverse section.

possible that on this account they are sometimes described as mucous polypi. Microscopically these tumours consist of cystic spaces lined with columnar epithelium, the cavities being filled with mucus. Adenomata of the corporeal endometrium differ from those of the cervix in that the cystic spaces are larger and more numerous, and the epithelium lining the spaces is tall and columnar, as in Fig. 170.

Cancer of the Body of the Uterus.—This is much less frequent than cancer of the neck of the uterus, and it arises in the epithelium lining the cavity of the uterus and its tubular glands. There is very little accurate knowledge regarding its

early stages, and the writer has had only one opportunity of obtaining a cancerous uterus before it had extended to the muscular wall. The disease remains for a long time restricted to the body of the uterus, and may creep into the uterine sections of one or both Fallopian tubes; it rarely invades the cervix, and then only in the late stages of the disease. It is apt to perforate the wall of the uterus and infect the peritoneum (Fig. 171).

It is only in the last fifteen years that the importance of cancer of the body of the uterus has been clearly appreciated,

Fig. 171.—Cancerous uterus in sagittal section: a bud-like process of the cancer protruded through the uterus and infected the peritoneum, which contained thousands of secondary nodules.

and this was due to the fact that there were no means available for the proper examination of the interior of the organ, and as a result the descriptions of diseases of the endometrium were disfigured or obscured by a crowd of terms such as senile endometritis, malignant endometritis, villous endometritis, and so on. When the plan of mechanically dilating the cervical canal was introduced, so that the endometrium could be examined and fragments obtained for the laboratory, then light began to shine, and we obtained some accurate data.

As in other organs, cancer of the body of the uterus consists

of cell-columns, the cells being identical with the epithelial cells of the endometrium. The disease assumes two distinct forms: thus it may appear as an eroding ulcer penetrating the muscular wall of the uterus, and sometimes even perforating the serous coat. In the common form it gives rise to luxuriant masses of soft, succulent, and vascular polypoid-like masses projecting into the cavity of the uterus; and this is the variety which used to be termed villous endometritis.

As the diagnosis of cancer of the body of the uterus is largely determined by the assistance of the microscope, it is essential

Fig. 172.—Microscopic characters of the common kind of cancer of the body of the uterus.

for those who venture to give opinions on this point to be thoroughly familiar with the various abnormalities of the corporeal endometrium, and especially those which are known as glandular polypi.

Although in writings and in clinical work we treat very definitely of cancer of the cervical endometrium and cancer of the corporeal endometrium, it is well to understand that cases come to hand in which, after the uterus has been removed, it is extremely difficult on examining the organ to state positively whether the disease arose in the body of the organ or in the upper segment of the cervical canal.

The writer is also convinced that there are two species of cancer arising in the corporeal endometrium, and that these

species are not only distinct in their histologic features, but also in their gross characters and clinical aspects.

The commoner species resembles and, indeed, is very similar to that which attacks the cervical endometrium, except in the more perfect columnar type of the epithelium composing the cancer columns (Fig. 172). The rarer species is that which has been described as "malignant adenoma" by more than one writer, and this is due to the fact that the normal features of the uterine glands are less distorted than in the common

Fig. 173.—Uterus with "tubular" cancer, shown in coronal section: the patient was 41 years of age, and mother of one child.

kind of cancer. It is remarkable in forming large, yellowish-white masses in the endometrium and causing great enlargement of the uterus (Fig. 173).

Cancer of the corporeal endometrium is unusual before the forty-fifth year; it is most frequent at or subsequent to the menopause. The majority of the cases occur between the fiftieth and seventieth years. *A large proportion of the patients are nulliparæ.*

The patient's attention is usually attracted by fitful hæmorrhages after the menopause, followed by profuse and offensive discharges which are often blood-stained. The uterus on

examination may feel scarcely enlarged; sometimes, however, it is much bigger than usual. In some instances cancer is associated with fibroids.

In order to give some reliable notion of the age-distribution

Fig. 174.—Microscopic characters of the cancer in the preceding figure: the uncommon kind, or "tubular" cancer.

of cancer of the body of the uterus, I have arranged in a tabular form twelve consecutive cases which were under my care. The table not only shows the ages of the patients, but also their parity and the presence or otherwise of fibroids. The table is of interest, because it was formerly supposed that

cancer of the corporeal endometrium arose mainly in aged spinsters or those who lived in sterile wedlock. It shows that this is not so exclusively a feature of the disease as we formerly believed; and this view is strengthened by the comparison of my table with the experience of other observers.

TABLE TO SHOW THE AGE-DISTRIBUTION AND RELATION TO PREGNANCY OF CANCER OF THE BODY OF THE UTERUS.

No.	Age.	Pregnancy.	No.	Age.	Pregnancy.
1	56	0	7	54	1 Fib.
2	50	0 Fib.	8	53	6
3	42	0	9	41	1
4	36	0	10	54	0 Fib.
5	45	0	11	56	5
6	60	0 Fib.	12	46	3

Cancer of the Uterus and Fibroids.—When we remember the frequency of uterine fibroids and cancer, the co-existence of the two diseases in the same uterus is not a matter for surprise. In many cases the two conditions may be seen in close proximity and without interfering with each other, but when the cancer implicates the capsule of a fibroid, then the tumour ulcerates and sloughs with great rapidity. Judging from my own observations, I find that uterine fibroids are more frequently associated with cancer of the corporeal endometrium than with that of the cervix. This is a matter for consideration, because I have had several cases in which a woman known to have small fibroids in the uterus attains the menopause (usually about the fiftieth year under these conditions) and suffers no menstrual inconvenience for five or six years, and then suddenly begins to have irregular "issues of blood"; this is due in many instances to cancer of the body of the uterus, and is always such a suspicious circumstance that it demands the most careful examination.

The matter may be put in an aphoristic form: *When a woman with uterine "fibroids," having passed the menopause, begins to have irregular profuse uterine hæmorrhages, it is extremely probable that she has cancer of the body of the uterus.*

An instructive record bearing on the subject of uterine fibroids and cancer has been published by Blacker.* A woman, aged thirty-nine years, with a large uterine myoma, was submitted to bilateral oöphorectomy, and the uterus shrank into the pelvis. Eight years later carcinoma attacked the neck of the uterus and destroyed the patient.

Treatment.—The only satisfactory mode of treating cancer of the uterus is the rough method of dealing with cancer in other accessible organs—namely, complete removal. It is a melancholy fact that cancer of the cervix is extremely common, yet operative interference can only be carried out in a very small proportion of the cases with any prospect of success. So small is this proportion that in my practice it works out at only 10 per cent. The chief reason is this: As soon as the disease overruns the cervix, the proximity of the bladder, ureters, and rectum renders a wide removal of the implicated tissues impracticable. It was thought that the practice now prevalent of complete removal of the uterus for cancer of the cervix would improve the remote results; but in this we are sadly disappointed, and it is important to emphasise the fact that some of the most thorough and complete vaginal hysterectomies have been followed by the most rapid and extensive recurrences. This is due, in my opinion, to the same cause as the extensive recurrences which I mentioned as following very free surgical operations on the breast and submaxillary region—namely, cancer infection of the tissues injured in the course of the operation. Look at vaginal hysterectomy for cancer from any point of view, and the results can only be regarded as depressing. The operation mortality is trifling, 5 per cent.; the rate of recurrence heavy, about 60 per cent. within the first six months; the average duration of life after operation eighteen months, my longest survival being four years.

In cancer of the body of the uterus I have had better results than in hysterectomy for cancer of the cervix; and the best consequences of all have followed abdominal hysterectomy for cancer of the body of the uterus.

* *Trans. Obst. Soc.*, vol. xxxvii. 213.

CHAPTER XXXVII.

EPITHELIAL TUMOURS OF THE FALLOPIAN TUBE AND THE OVARY.

Adenoma.—Epithelial tumours of an innocent type occur primarily in the Fallopian tube. One of the best known examples is that recorded by Doran,* in which the tube was filled by dendritic masses covered with mucoid fluid. The cœlomic ostium of the tube was open, and fluid exuded from it into the pelvis. The excrescences grew from all parts of the mucous membrane in the dilated portion of the tube. Several

Fig. 175.—Adenoma of the Fallopian tube. (*After Doran.*)

pedunculated cysts with thin walls rise from amidst the excrescences and contain papillary outgrowths. The free surfaces of the outgrowths are covered with columnar epithelium. Some of the cells bear cilia. The stroma is made up of small fusiform connective tissue cells, and is poorly supplied with blood-vessels. The microscopic and naked-eye characters of the growth induced Doran to describe it as a papilloma (Fig. 175).

Some years ago I re-examined this specimen, and came to the conclusion that it is an adenoma developed on the type of the glandular recesses found in the Fallopian tube (Fig. 176).

Dr. W. Walter, of Manchester, was good enough to place in my hands for examination an even more convincing specimen of Fallopian adenoma than the one just considered. The specimen consisted of a large ovarian cyst with a distended

* *Trans. Path. Soc.*, vol. xxxi. 174.

Fallopian tube. On examining the tube, its cœlomic ostium was found largely dilated, and a luxuriant mass of vesicles, like a bunch of grapes, protruded from it, producing an appearance not unlike a cornucopia (Fig. 177).

On laying open the Fallopian tube the vesicles were found to involve the outer third of the tube, and to spring from the

Fig. 176.—Microscopic characters of a Fallopian adenoma.

mucous membrane. Sections prepared from the base and solid parts of the tube, when examined under the microscope, exhibited the structural characters of an adenoma (Fig. 178). The solid portion of the tumour was composed of delicate connective tissue, in which were embedded glandular acini, lined with a single layer of regular columnar epithelium. In some parts of the tumour, especially near the surface, cystic spaces containing sprouting masses of intracystic growth were

found. The specimen differed from Doran's case in that it contained a far larger proportion of stroma.

An interesting feature of the clinical history of these cases is the co-existence of hydroperitoneum. In the case described by Doran the fluid in the abdomen was removed by paracentesis on four occasions between March, 1878, and the removal of the tumour in April, 1879, on which occasion ten litres of fluid were evacuated. In addition, the patient suffered from fluid effusions in the right pleura, for which she was twice tapped. After the removal of the right tube, with the tumour contained

Fig. 177.—Adenoma of the Fallopian tube. (*Dr. Walter's case.*)

within it, the effusions ceased, and the patient was in good health in 1886.

The relation of hydroperitoneum to these adenomata associated with patency of the tubal ostium has been made by Doran the subject of careful and suggestive study, to which reference has already been made. As he states, "The ostium of the tube remained patent, and hydroperitoneum persisted until the diseased tube was removed. The evidence that the secretion escaped from the ostium was positive."

An additional case has been published by Doleris,* which occurred in a woman twenty-eight years of age. Both ovaries and tubes were removed. The right tube formed a cyst the size of a small nutmeg. Masses of papillomatous growths

* *Bull. de la Soc. Obstet. et Gyn.*, Paris, Jan., 1890.

sprang from the inner wall of the tube. The uterine end of the canal was very narrow. There was no fluid in the cœlom. A peculiar clinical feature in this case was the discharge of large quantities of sero-sanguineous fluid from the vagina. An attempt had been made to cure this by curetting the interior of the uterus. The effect of this operation was to produce right-sided parametritis. The discharges after the operation became continuous, and the fluid pale yellow and of a syrupy consistence which stiffened linen like starch.

Carcinoma.—The fact that the Fallopian tube may be

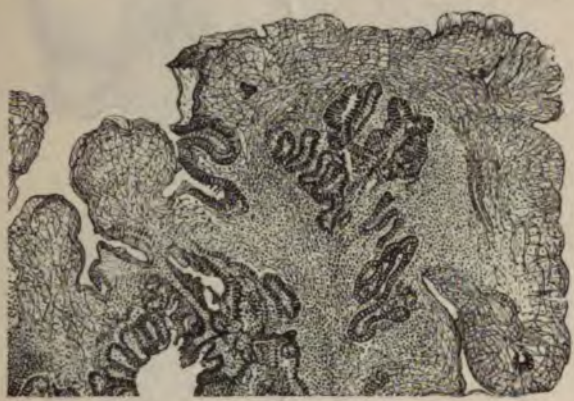

Fig. 178.—Microscopic characters of the tubal adenoma shown in Fig. 177.

the seat of an adenoma leads us to expect that it would occasionally be affected with primary carcinoma.

There is now trustworthy evidence available not only to assure us that this dreadful disease occurs in the Fallopian tube, but also to enable me to state its general clinical features for diagnostic purposes.

It generally occurs in women about the time of the menopause, and gives rise to discharges of fluid through the vagina; the fluid is generally blood-stained. The disease occurs in women who have had children as well as in those who are sterile. The outlook for the patient is not good, for the disease as a rule quickly returns after the affected tube is removed.

In the example represented in Fig. 179 the specimen was somewhat exceptional, for the patient had a large submucous fibroid, and the Fallopian tube ran across the crown of the

tumour and had a total length of 22 cm., so that there was a long unimplicated section of attenuated and elongated tube between the cancer and the uterus. The specimen had another interest, for a portion of the cancer had made its way through the cœlomic ostium and infected the adjacent peritoneum. Microscopically the structure of the tumour corresponded with primary cancer of the corporeal endometrium.

Fig. 179.—(A) Ampulla of a Fallopian tube occupied by a primary cancer; (B) the ampulla of the tube shown in section. From a sterile married woman 57 years of age. The growth had made its way through the cœlomic ostium of the tube and infected the adjacent peritoneum.

It must be carefully borne in mind in examining suspected cases that cancer of the uterus often extends into and implicates the mucous membrane of one or both Fallopian tubes (Fig. 180). It is also a fact worth remembering that when the tubes are thus invaded the microscopic features of the cancer become changed; it loses the peculiar tubular characters of the glands of the endometrium, and assumes the fissure-like features which the tubal mucous membrane presents at its uterine segment.

Secondary deposits of cancer in the Fallopian tubes are very unusual and of no clinical import.

For an able critical summary and references to the literature of cancer of the Fallopian tube the student should consult Doran, *Obstetrical Journal of the British Empire*, 1902.

Carcinoma of the Ovary.—In regard to this disease very little reliable evidence is forthcoming. Many cases have been described in which the ovary has become transformed into a large tumour which, under the microscope, presented an alveolar disposition of cells; but such specimens have for

Fig. 180.—A cancerous uterus in coronal section. It was difficult to decide whether the cancer began in the upper part of the cervix or the lower part of the body of the uterus. A process of the growth is creeping into the right Fallopian tube.

the most part occurred in children, whereas cancer in every other gland is a disease of adult life. This fact alone should make us pause before deciding simply on the alveolar constitution of a tumour that it is cancer. Nevertheless, malignant tumours are occasionally seen in the ovaries of individuals past middle life in which epithelium plays a very characteristic part.

Much confusion has arisen from the fact that ovarian follicles entangled amidst sarcomatous tissue mimic the structural

peculiarities of carcinoma. Nevertheless, tumours of the ovary are occasionally encountered in which the chief changes are centred in the follicles (Fig. 181). As the membrana granulosa is composed of epithelium, tumours of this character come strictly under the definition of a carcinoma. Such tumours conform in their clinical characters to cancer in general, for they grow rapidly and infect the peritoneum. When removed, quick

Fig. 181.—Histologic characters of primary ovarian carcinoma. The changes in the follicles are well shown. (*Zweifel.*)

recurrence is the rule, and speedy death. In the majority of cases the peritoneum is infected before the patients come under observation, hence operations are rarely undertaken. Primary cancer of the ovary requires careful investigation with a full supply of material.

Secondary Cancer.—The ovaries are very common situations for secondary cancer, especially when the primary tumour occupies the breast or the pylorus, and in a large proportion of cases the deposits occupy both glands (see Fig. 147).

CHAPTER XXXVIII.

GROUP III.—DERMOIDS.

Dermoids are tumours furnished with skin or mucous membrane occurring in situations where these structures are not found under normal conditions. They only possess tissues which naturally belong to skin or mucous membrane.

Dermoids may be arranged in four genera :—

I. Sequestration dermoids.
II. Tubulo-dermoids.
III. Hairy moles.
IV. Ovarian dermoids.

Each genus occurs in definite situations and presents structural peculiarities. Sequestration dermoids are the simplest: the most complex arise in the ovary.

SEQUESTRATION DERMOIDS.

Dermoids belonging to this genus arise in detached or sequestrated portions of skin, chiefly in situations where, during embryonic life, coalescence takes place between cutaneous surfaces. A sequestration dermoid occasionally takes the form of a skin-lined recess, but more commonly it assumes the form of a globular tumour with a central cavity lined with skin, furnished with dermal elements. The skin-lining is usually similar to the surrounding skin.

Dermoids of the Trunk.—These occur strictly in the regions where the lateral halves of the body coalesce. This line of union, commencing immediately below the occipital protuberance, extends along the middle of the back to the coccyx; it then passes through the perineum (scrotum and penis in the male) and upwards through the umbilicus, thorax, neck, and chin, to terminate at the margin of the lower lip.

Dermoids are rare along the dorsal part of this line and are apt to be mistaken for spina bifida sacs, especially when situated

in the lumbo-sacral region. The patient (Fig. 182) was a man twenty-two years of age. The tumour was congenital, and had been regarded as a spina bifida sac. It had never caused him inconvenience until a few days before his admission into the hospital, when it inflamed, burst, and discharged a quantity of foul-smelling sebaceous material mixed with hairs. The cavity was freely opened and cleared of decomposing material. The skin lining the interior of the dermoid was beset with

Fig. 182.—Dermoid in the lumbo-sacral region of a man 22 years of age.

pores of large size, corresponding to the orifices of sweat glands; when the patient perspired, drops of sweat could be seen oozing from these pores. This skin also contained nerves, for the man could localise the prick of a pin on the interior of the dermoid, as easily as one made upon the skin surrounding the tumour. When the tumour was removed, the spinous processes underlying it were found to be unusually short and surrounded by fat.

Rarely dermoids are associated with spina bifida. Gilbert Barling observed such a combination in a child two years old affected with spina bifida occulta; the skin covering the

defective spines presented the hair-field usual in these cases. In the tissues immediately over the stunted spinous processes a dermoid was found containing sebaceous material and hair.

It is very rare to find dermoids within the spinal canal. An interesting instance of this has been recorded by Hale White.* It grew in the thoracic region of the spine, and produced paraplegia. Laminectomy was performed on the patient, a man twenty-six years of age, but it was not successful.

Fig. 183.—Section of three thoracic vertebræ with a small dermoid situated over two stunted spinous processes.

Faulty coalescence of the cutaneous covering of the back often occurs over the lower sacral vertebræ, and gives rise to small congenital sinuses known as "post-anal dimples" and "coccygeal sinuses." These recesses are lined with skin furnished with hairs, sebaceous and sweat glands. Sometimes they measure 10 mm. in depth. As a rule they are single, and often accompany lumbo-sacral spinal bifida. Though most commonly seen over the coccygeal, or the last two sacral vertebræ, I have seen them as high as the fourth lumbar vertebra and always exactly in the middle line.

These dimples are interesting, for—as will be shown afterwards—in many situations where sequestration dermoids occur, similar cutaneous recesses are also seen. An examination of such a sinus serves to show that if its external orifice became occluded, without the deeper parts becoming obliterated, we should have the germ of a dermoid, for the numerous glands in the walls would be active, and their secretion, with the shed epithelial scales and hairs, would soon cause it to enlarge and assume such proportions as to render it recognisable as a tumour.

The coccygeal sinuses are sometimes troublesome, as hair and dirt accumulate in them and lead to suppuration. Clinically a suppurating coccygeal sinus simulates an anal fistula, but a little care prevents the surgeon from falling into error.

* *Trans. Clin. Soc.*, vol. xxxiii. 140.

A good physiological type of such a sinus is furnished by the interdigital pouch of the sheep. This pouch (Fig. 184) lies between the digits, and all the dissection required to expose it is to separate the digits with a sharp knife, keeping close to the phalanges of one or other side. In adult sheep it is always full of shed wool and grit. Sometimes its orifice is occluded and it becomes a retention cyst; suppuration follows, much to the sheep's discomfort.

Fig. 184.—Median aspect of a sheep's digit, showing the interdigital pouch.

The walls of this pouch are full of very large glands. In order to get satisfactory sections it is necessary to obtain the digits from a still-born lamb, for as soon as lambs run about grit gets into the pouch and spoils the edge of the knife.

Dermoids of the Scrotum and Labium.—There are many good reasons for believing that the majority of dermoids reported as arising in the testicle were really scrotal in origin. This was clearly the case in a specimen described by Bilton Pollard * as a dermoid of the testicle. The dermoid was situated on the left side of the scrotum, between the testicles, and adhered to the back of the left one outside the tunica vaginalis. It contained putty-like material in which there were a few grey hairs. The cyst was lined with stratified epithelium; papillæ and sebaceous glands were detected.

In records of future cases it will be necessary to pay close attention to the relation the dermoid bears to the testis, tunica vaginalis, and scrotum.

Dermoids of the **labium** are very rare: on one occasion I saw one removed as big as an orange from the right labium of a woman 40 years of age. It contained the usual pultaceous material and shed hair. The dermoid had burrowed beneath

* *Trans. Path. Soc.*, vol. xxxvii. 342.

the deep fascia of the thigh, and came into relation with the tendon of the adductor longus.

Dermoids of the Testis.—It is usually stated in text-books that dermoids of the testis are common. This is not in accord with facts. Very few reliable records are forthcoming in surgical literature, and in the few available descriptions the details are insufficient to enable one to determine whether the dermoids were scrotal or testicular.

D'Arcy Power * has described an undoubted example, and so has Jackson Clarke.† In each of these cases the tumour was situated inside the tunica albuginea.

Dermoids have been described in connection with the inguinal canal and spermatic cord. The records cannot be relied upon; hair and other cutaneous structures were absent, and the walls of the cysts were not submitted to microscopic scrutiny. The mere presence of pultaceous matter in a sac is not proof of a dermoid.

Dermoids of the Thorax.—Judging from the few available records, dermoids of the thorax are very uncommon. They occur in two situations—viz. on the anterior aspect of the sternum and in the thoracic cavity. Dermoids on the front of the sternum are situated in the middle line near the junction of the manubrium with the gladiolus (Fig. 185); it is not uncommon to find a small cutaneous recess in this situation exactly in the middle line and resembling the coccygeal sinus.

Examples of dermoids in this situation have been carefully described by Bramann,‡ Cahen,§ and Clutton.‖

The occurrence of dermoids, sometimes of large dimensions, on the anterior face of the sternum is a fact of great importance, as it affords some evidence in regard to the mode of origin of dermoids which are occasionally found inside the thorax.

Interthoracic dermoids have been observed and carefully described by Albers,¶ Hale White,** Douglas-Powell and Godlee;††

* *Trans. Path. Soc.*, vol. xxxviii. 224.
† *Trans. Path. Soc.*, vol. xlvii. 148.
‡ Langenbeck's *Arch.*, bd. xl.
§ *Zeitschrift für Chir.*, bd. xxxi. 370.
‖ *Trans. Path. Soc.*, vol. xxxviii. 393.
¶ *Atlas der Path. Anat.*, 1846, Tab. xxxiv.
** *Trans. Path. Soc.*, vol. xli. 283.
†† *Medico-Chir. Trans.*, vol. lxxii. 317.

and Pflanz * has recently collected the literature. In the majority of cases the tumour occupies the superior mediastinum, and generally makes its way downwards and to one side, compressing the lung. In Hale White's patient the tumour rested on the anterior face of the pericardium. Many of the cases have been reported as "dermoids of the lung," but all the recent

Fig. 185.—Dermoid situated over the junction of the manubrium and gladiolus of the sternum; there was also a dermoid near the left cornu of the hyoid bone. The youth was 19 years of age. (*After Bramann.*)

writers agree that the involvment of the lung is secondary. Some of the patients have been clinical puzzles until "hair-spitting" occurred, due to the dermoid opening into the air passages.

An unusual situation for a dermoid is the episternal notch (Fig. 186), and it is easy to understand that one in this situation could burrow into the superior mediastinum.

At first glance it would seem difficult to account for the

* *Zeit. für Heilkunde*, 1896, bd. xvii.

presence of a large dermoid within the thorax, but a review of the mode of development of the sternum throws much clear light on the subject. The two lateral halves of the sternum are, in the early embryo, widely separated from each other; gradually they coalesce in the middle line. Every anatomist is aware that this median coalescence is extremely liable to be faulty, and conditions occur like those which, happening in connection with the medullary folds, produce spina bifida. In this line of coalescence, so far as sternal dermoids are concerned, we may get skin-lined recesses resembling the coccygeal dimples. These sternal recesses, or dimples, occur near the junction of the manubrium with the gladiolus, and may be more than a centimetre deep. Should a piece of skin become sequestrated during coalescence of the thoracic walls, it may, during the development of the sternum, be dislocated forwards to the outer surface, or backwards towards the mediastinum, conditions in every way parallel to the variations in the position of cranial dermoids. So long as a dermoid on the deep surface of the sternum remains small it will cause no trouble, but it is easy to understand that a large tumour would, if projecting into the thorax, encroach on the pleura; even then it would not produce much disturbance so long as air did not gain access to it; but if by pressure the wall of the cyst becomes so thin as to allow air to enter its cavity, or an actual communication forms between the cyst and a bronchus, or the air-sacs of the lung, then suppuration with all its disastrous consequences will ensue.

Fig. 186.—Dermoid in the episternal notch. It contained hair and pultaceous matter, and was superficial to the deep cervical fascia.

CHAPTER XXXIX.

SEQUESTRATION DERMOIDS (*continued*).

Facial Dermoids.—Dermoids occur on the face in certain definite positions, such as the inner and outer angles of the orbit; the upper eyelid; in the naso-facial sulcus; on the

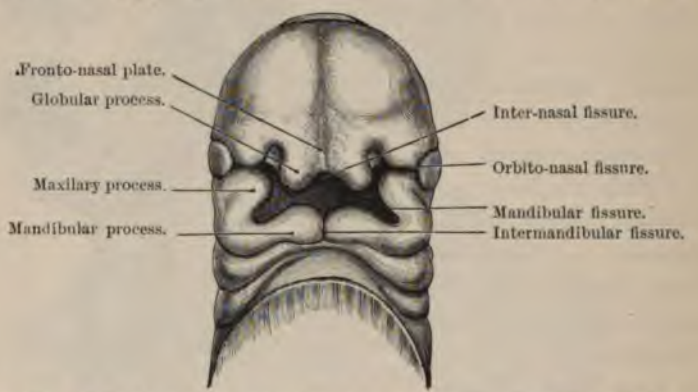

Fig. 187.—Head of an early embryo to show the fronto-nasal plate, globular processes, and associated fissures. (*Modified from His.*)

cheek slightly posterior to the angle of the mouth; in the middle line of the chin, and on the nose.

In order to appreciate the origin of dermoids in these situations it is necessary to bear in mind the relation of the facial fissures in the embryo, which in the adult are represented by the orbits, lacrymal ducts, mouth, and certain furrows in the lips and cheek.

In the early embryo the face is represented by an opening from which five fissures radiate (Fig. 187). The upper pair are the orbito-nasal; the two lower fissures are termed mandibular, and the fifth the intermandibular fissure. The median fold projecting into the opening from above is the fronto-nasal process, which ultimately forms the nose. As it develops, a rounded prominence, known as the globular process, forms at

each angle and gives rise to a portion of the ala of the nostril and the corresponding premaxilla. These globular processes fuse together in the middle line to form the central piece, or philtrum, of the upper lip. The elongation of the fronto-nasal process necessarily lengthens the orbito-nasal fissures. Eventually the sides of the fronto-nasal plate coalesce superficially with the maxillary processes in such a way as to leave a cleft on each side, which becomes the orbit; the line of union being permanently indicated in the adult by the naso-facial sulcus or groove, and indicated still more deeply by the lacrymal duct,

Fig. 188.—The face with black lines to indicate the situation of the embryonic fissures.

which is a persistent portion of the original orbito-nasal fissure. The union of the fronto-nasal plate with the maxillary processes completes the nose, cheeks, and upper lip.

The above account indicates in a general way the relation of these fissures to each other; but it will be necessary in considering dermoids arising in them to mention certain details connected with each. But here it may be stated that the defects associated with any of them are of three kinds:—1, the fissure may persist; 2, it may close imperfectly and leave a recess or puckering of the skin; 3, portions of the surface epithelium may be sequestrated and give rise to dermoids.

These conditions may be illustrated by the mandibular fissure. In the embryo this fissure or cleft is relatively more

extensive than the opening of the mouth which in the adult ultimately represents it. In fishes the whole of the mandibular fissure persists as the gape; but in mammals the dorsal portions of the clefts are obliterated by the union of their margins, leaving the central portion as the mouth. Persistence of the whole length of the fissure is a rare defect, and is known as **macrostoma**, while excessive closure of the fissure produces

Fig. 189.—Right side of the head of a fœtus, showing a large mandibular tubercle and an accessory tragus.

microstoma. Imperfect union of those sections that normally coalesce gives rise to slighter imperfections, of which some examples will now be described.

Occasionally we find on one or both cheeks of children, at a spot varying from 2 to 4 cm. behind the angle of the mouth, a small nodule rarely exceeding a rape-seed in size. Sometimes there is a depression or sinus in the cheek surmounted by the nodule. Occasionally the buccal mucous membrane presents a shallow recess, sometimes a sinus, and occasionally a white

cicatrix at a spot corresponding to the nodule on the cutaneous surface of the cheek.

These **mandibular tubercles** and **recesses** are frequently associated with malformations of the corresponding auricles, as well as other facial defects, such as coloboma of the eyelid and pilose cutaneous patches on the conjunctiva. The largest specimen which has yet come under my observation occurred in a still-born fœtus (Fig. 189). On the right cheek, 2 cm. behind the angle of the mouth, was a nodule the size of a rape-

Fig. 190.—Head of a dog showing the mandibular tubercle.

seed, and immediately behind this a pedunculated body. The tubercle on the cheek consisted of dense connective tissue traversed by blood-vessels and covered with skin beset with lanugo, and richly supplied with sweat and sebaceous glands of large size.

It may here be pointed out that in many mammals, especially dogs, small cutaneous nodules furnished with vibrissæ may often be detected in a line with the angle of the mouth (Fig. 190). These nodules occupy positions identical with the mandibular tubercles of children.

There is very little relationship between pathology and

CHAPTER XL.

SEQUESTRATION DERMOIDS (*concluded*).

Dermoids of the Orbito-Nasal Fissure.—Dermoids appear in this fissure in three situations.

1. At the outer angle of the orbit.
2. The inner angle of the orbit.
3. In the naso-facial sulcus.

Of the three situations, by far the most frequent is the outer angle of the orbit, where they form rounded tumours rarely

Fig. 192.—Dermoid at the outer angle of the orbit.

exceeding the dimensions of a cherry; they lie in close relation with the pericranium covering the frontal bone, which is often deeply hollowed to accommodate them. Dermoids in this region vary somewhat in regard to their position; sometimes they are quite close to the external angular process of the frontal bone, or they may be 2 cm. or more posterior to it (Fig. 192); exceptionally they are on a level with, or even lie beneath, the eyebrow.

Dermoids at the inner angle are far less frequent (Fig. 193). In this situation the tumour may extend beyond the bone and lie in intimate relation with the dura mater. It is very necessary to remember this in attempting the extirpation of the dermoid. In some cases the tumour may have a peduncle continuous with the dura mater. Under such conditions the dermoid may transmit the cerebral pulsation; it is then apt to be mistaken for a meningocele. This is a less serious error than mistaking

Fig. 193.—Dermoid in the inner angle of the orbit.

a meningocele for a dermoid and following up the error by attempting its extirpation.

Dermoids occur not only at the orbital angles, but sometimes also in the tissue of the upper eyelid, unconnected either with bone or periosteum. These smaller dermoids probably arise in the fissure between the fronto-nasal plate and the cutaneous fold from which the eyelid is formed. The fissure between the two parts which form an eyelid sometimes persists. To this defect the term coloboma of the eyelid is applied.

Dermoids arising in the orbital angles are the simplest of all dermoids, and though the skin lining them is usually rich in the ordinary cutaneous elements, such as hair, sebaceous and sweat glands, complex structures, such as teeth and bone, so far as my knowledge extends, have not been observed in them. I have satisfied myself that the skin in these dermoids is sensitive and that it possesses tactile sensibility.

Dermoids in the lower section of the *orbito-nasal* fissure are

Fig. 194.—Dermoid in the naso-facial sulcus containing a tooth. (*After Paul.*) *

Fig. 195.—A translucent dermoid at the bridge of the nose. The man was 30 years of age.

rare. They usually protrude in the naso-facial sulcus, and occasionally possess a tooth (Fig. 194).

Nasal Dermoids.—It is necessary to point out that in addition to the naso-facial sulcus, dermoids occur in two other situations on the nose. A not uncommon position is the bridge of the nose (Fig. 195). This part of the face is not traversed by a fissure, and the mode by which such a dermoid arises is in all respects identical with that which gives rise to cranial dermoids.

In the skull of an early embryo, the fronto-nasal plate which ultimately forms the nose consists of a lamina of hyaline carti-

* *Trans. Path. Soc.*, vol. xlv. 148; also Ashby and Wright, "Diseases of Children," 1899.

lage covered externally by skin and internally by mucous membrane. After the third month sections made through the nasal capsule, immediately anterior to the ethmoid, show that the skin is being dissociated from the underlying cartilage by bony tissue, which eventually becomes the nasal bones. Ultimately the cartilage disappears as a result of the pressure exercised by these bones. It is reasonable to believe that in the gradual separation of the skin from the cartilage of the fronto-nasal plate by the intrusion of the nasal bones, small portions of skin or epithelium become sequestrated and eventually develop

Fig. 196.—Dermoid recess in the nose of an adult.

Fig. 197.—Dermoid recess at the tip of the nose of a child. (The hair is represented too coarse.)

into dermoids. This explanation is more fully set forth in the section on dermoids of the scalp and dura mater.

Dermoids near the tip of the nose are the consequence of faulty fusion of the inter-nasal fissure, and usually take the form of narrow skin-lined recesses furnished with hair, which is often long enough to sprout beyond the recess (Figs. 196 and 197).

Hair-lined recesses in the mid-line of the nose at some point between the lower border of the nasal bone and the tip of the nose are very common, but they rarely call for treatment. They occur far more frequently in men than in women. In their mode of origin and characters they agree with the hair-lined sinuses known as post-anal dimples.

A much rarer anomaly than a dermoid is excessive coalescence of the nasal segment of the orbito-nasal fissure (Fig. 198).

Dermoids of the Scalp and Dura Mater.—The common situations for dermoids of the scalp are over the anterior fontanelle (bregma) and occipital protuberance. In these situations they are occasionally confounded with sebaceous cysts or with meningoceles. Dermoids of the scalp often have a thin pedunculated attachment to the dura mater, the pedicle traversing a hole in the underlying bone, unless the cyst is over a fontanelle.

Fig. 198.—Child with a deformed nose due to excessive coalescence of the nasal section of the orbito-nasal fissure. The case was under the care of Mr. Nicoll.

The specimen represented in Fig. 199 was long preserved in the museum as an example of a sebaceous cyst or wen; its connection with the dura mater induced me to examine it, and I ascertained that the cyst contained skin and hair. The term "wen" used to be applied indifferently to sebaceous cysts and dermoids of the scalp. Sir Astley Cooper, in his well-known essay on "Encysted Tumours," * even included orbital dermoids among wens. In describing them, he writes:—"The largest size I have known them acquire has been that of a common-sized cocoanut, and this grew upon the head of a man named Lake, who kept the house called the 'Six Bells' at Dartford. It sprang from the vertex, and gave him a most

* "Surgical Essays," vol. ii. 213. 1818.

grotesque appearance, for when his hat was put on, it was placed upon the tumour and scarcely reached his head. The cyst is in the collection at St. Thomas's Hospital, also a cast of his head taken just prior to the operation" (Fig. 200).

The cyst, which is probably the largest dermoid of the scalp on record, contains a number of round balls, some having a diameter of 1 cm. These consist of epithelial cells mixed with fat. Sibthorpe * removed a similar tumour from the head of a Hindu, and Marsh † excised one from an Englishman twenty-five years of age. In each instance the cyst was as big as a cocoanut.

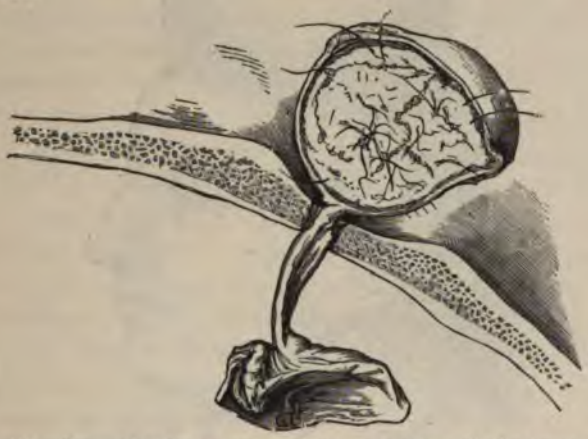

Fig. 199.—Dermoid of the scalp connected by a pedicle with the dura mater. (*Museum, Middlesex Hospital.*)

Arnott ‡ published the details of an instructive case of a dermoid situated over the anterior fontanelle in an infant a few days old. The tumour exactly resembled a meningocele, "rising and falling with regular pulsation, and swelling when the child coughed"; the resemblance was so strong that it was regarded as a meningocele. A few weeks later the child died from broncho-pneumonia, and the cyst was found to be a dermoid. The specimen is preserved at St. Thomas's Hospital.

Giraldés § records a case even more remarkable than this. A child, three months old, had an ovoid tumour, of the size of

* *Brit. Med. Journal*, 1888, vol. i. 350.
† *Brit. Med. Journal*, 1900, vol. i. 443.
‡ *Trans. Path. Soc.*, vol. xxv. 228.
§ "Maladies Chir. des Enfants," 342.

a pigeon's egg, over the anterior fontanelle. The tumour was covered with fine white hair, and did not pulsate with respiration. It was thought to be a meningocele, and in order to establish a diagnosis it was punctured with a fine trocar, and fluid resembling that found in meningoceles was withdrawn. Notwithstanding numerous subsequent punctures, the tumour

Fig. 200.—Head of the man Lake with a large dermoid over the bregma. (*From a cast in the Museum, St. Thomas's Hospital.*)

maintained its original volume. Some months later it was removed, Giraldés being still under the impression that it was a meningocele; but it was found to be a typical dermoid.

Dermoids in the neighbourhood of the occipital protuberance (inion) may lie on the inner aspect of the occipital bone, and are nearly always in relation with the tentorium cerebelli. Examples have been described by Turner,* Ogle,† Pearson

* *St. Barth. Hosp. Rep.*, vol. ii. 62.
† *Brit. and For. Med.-Chir. Review*, 1865.

Irvine,* and Lannelongue.† They occurred in children, and in Ogle's case there was defective development of the squamous portion of the occipital bone. In Lannelongue's patient, a girl seven years old, the dermoid had attained the size of an orange; it produced marked symptoms, such as paralysis, amaurosis, and coma, ending in death.

Although at first sight a dermoid connected with the dura mater and projecting into the brain seems to violate all embryological rules, nevertheless, when we view this membrane from a morphological standpoint, the strangeness vanishes and a satisfactory explanation is forthcoming.

Morphologically considered, the bony framework of the skull is an additional element to the primitive cranium, which is represented by the dura mater, and as I have elsewhere ‡ endeavoured to show, the term extracranial should strictly apply to all tissues outside the dura mater. In surgical practice we find it convenient to regard the bones as the boundary of the skull, but morphologically this is inaccurate; the skull-bones are secondary cranial elements. Early in embryonic life the dura mater and skin are in contact; gradually the base and portions of the side-walls of the membranous cranium chondrify, thus separating the skin from the dura mater. In the vault of the skull, bone develops between the dura mater and its cutaneous cap, but the skin and dura mater remain in contact along the various sutures even for a year or more after birth. This relation of the dura mater and skin persists longest in the region of the anterior fontanelle (bregma) and the neighbourhood of the inion. Should the skin be imperfectly separated, or a portion remain persistently adherent to the dura mater, it would act precisely as a tumour germ and give rise to a dermoid. Such a tumour may retain its original attachment to the dura mater, and its pedicle become surrounded by bone; the dermoid would lie outside the bone, but be lodged in a depression on its surface, with an aperture transmitting its pedicle. On the other hand, the tumour may become separated from the skin

* *Trans. Path. Soc.*, vol. xxx. 195.

† "Affections Congénitales," 1891, p. 49; also Walther, *Presse Médicale*, Avril 6, 1895.

‡ *Journal of Anat. and Phys.*, vol. xxii. 28: "A Critical Study in Cranial Morphology."

by bone; it would then project on the inner surface, or between the layers of the dura mater. If this view of the origin of dermoids of the scalp be admitted, we must then modify our teaching, and say that the depressions in which dermoids of the cranium are lodged arise as imperfections in the developmental process, and are not due to absorption induced by pressure; further, the fibrous connection of such dermoids with the underlying dura mater is primary, not accidental.

The relation of dermoids to the tentorium requires further consideration. A study of the development of the tentorium cerebelli will demonstrate that it is composed of two folds of dura mater, and it arises as an infolding or crease in this membrane, caused by the rapid backward extension of the developing cerebrum. The opposed surfaces of the tentorial lamellæ, like the outer surface of the dura mater in relation with the cerebrum, were originally in contact with the skin, and as the posterior margins of the bay or recess formed by the crease in the dura mater come together, a portion of the skin may become nipped or even sequestrated between the layers of the tentorium; this, preserving its vitality, and in some cases its cutaneous connections, may ultimately give rise to an intracranial dermoid.

IMPLANTATION CYSTS.

These small cysts should not be included among tumours, but their consideration is imperative in connection with sequestration dermoids, for they furnish valuable evidence that dermoids of this genus arise from "rests," the result of faulty coalescence.

These cysts are caused by the accidental implantation of portions of skin, epithelium, or hair bulbs in the underlying connective tissues. The transplanted tissue acts in many instances as a graft, and forms a small cyst. Implantation cysts have received a variety of names, such as dermal cysts, traumatic dermoids, sebaceous cysts of the fingers, etc.

They are common on the fingers, the cornea, and the iris, but they may arise on any part of the skin. They have been observed by many surgeons, and careful accounts have been written especially by Polaillon,* Le Fort,† and Garre.‡

* *Dic. Ency. des. Sci. Méd.*, 1884, art. "Doigt."

† *Rev. de Chir.*, 1889.

‡ Bruns' *Beiträge*, bd. xi. 524.

Implantation cysts vary much in size; some are scarcely as big as a split pea, others may be as large as a ripe cherry. In many the microscopic characters "appear as if a piece of the skin covering the pulp of the finger had been inverted" (Shattock). In others the implanted epidermis seems to have been shed in layers, so that on section the interior of the cyst is occupied by epithelial laminæ. When these cysts occur on the scalp, the interior contains hair.

Implantation cysts are caused in a variety of ways, such as punctures by awls, forks, needles, thorns, glass, etc.; also accidental wounds by knives, incisions by scalpels, bites and lacerations.

These cases are of interest, for they serve to throw light on some cysts, containing hair and wool, preserved in the museum of the Royal College of Surgeons. Two of the cysts are from sheep, and contain wool embedded in fatty matter. Unfortunately, the catalogue affords no information as to the region of the body whence they were removed. The third and fourth specimens were removed from the shoulder of a cow that had six legs. The cysts contain light hair, fatty and calcareous matter. These four specimens are Hunterian. The fifth specimen was removed from beneath the integuments of the shoulder of an ox. It contained slender black hairs, resembling those on the skin of the animal, mixed with fat. I once obtained a good example of an implantation cyst from the axilla of an ox. The cyst was as large as a billiard ball, and in structure resembled a piece of inverted skin. Fortunately, these cysts can be explained on the same lines as dermoid cysts of the fingers in man. The sticks used by cattle-drovers are armed at the end with a sharp iron spike, 2.5 cm. (1″) long, with which they "prod" the beasts, often very severely. It may be assumed that punctures produced with such an instrument may lead to the deposition of dermal grafts beneath the skin, which may give rise to dermoids in the same way as punctured wounds in the skin of men and women. Punctured wounds in sheep and oxen may also be caused by projecting nails, iron spikes, tenter-hooks, and the like.

The opinion that dermoids may arise in the subcutaneous tissues by implantation receives the strongest possible con-

firmation from what we know of similar cysts of the iris and cornea associated with mechanical injury.

Iritic Cysts.—Cysts of the iris are of comparative rarity, generally appearing as transparent vesicles situated on its anterior surface. As a rule they are sessile, but occasionally possess a pedicle. The contents may be opaque, but in exceptional cases they have been filled with sebaceous material, such as fills the cavities of dermoids.

Hulke * (1869) collected some valuable facts in relation to such cysts, and states that in fifteen out of nineteen cases, as well as in two reported by himself, there was distinct history of antecedent mechanical injury. He suggested that some of these cysts originated from portions of Descemet's membrane, which may have been torn from the cornea and implanted on the iris.

Numerous instances are known in which eyelashes, sometimes as many as six, have been implanted on the iris by foreign bodies penetrating the cornea, such as knives, needles, foils, and swords. Similar cysts have been produced in the eyes of rabbits by the artificial introduction of eyelashes and epithelium into the anterior chamber.

Corneal Cysts.—In addition to the evidence furnished by implantation cysts of the iris we know that similar cysts occur in the cornea. Treacher Collins † has investigated this matter, and has published some valuable researches in which he has succeeded in demonstrating that after gunshot injuries of the eyeball, blows from tip-cats, and incisions made for the extraction of cataracts, cysts, usually of small size, are liable to form in the cornea near the seat of injury. In some of the specimens the cyst may be very large and conspicuous; when examined microscopically, their inner walls are found lined with layers of cells identical with those covering the anterior surface of the conjunctiva. The structure of these cysts, taken in conjunction with the antecedent injuries, thoroughly supports the view that they arise from conjunctival epithelium transplanted into the deep tissues of the cornea.

* "On Cases of Cysts of the Iris," *R. Lond. Ophth. Hosp. Rep.*, vol. vi.; also Hosch, "Ex. Studien über Iriscysten," Virchow's *Arch.*, bd. xcix. s. 449.

† "The Anatomy and Pathology of the Eye," London, 1896.

CHAPTER XLI.

TUBULO DERMOIDS; LINGUAL DERMOIDS; MEDIAN CERVICAL FISTULÆ; ACCESSORY THYROID GLANDS; RECTAL DERMOIDS.

THERE exist in the human embryo certain canals and passages many of which normally disappear before birth. Among these **obsolete canals** there are three that require especial consideration in connection with dermoids—viz. the thyro-lingual duct, the post-anal gut, and the branchial clefts. The remainder will be considered in the section devoted to cysts.

The Thyro-glossal Duct.—The thyroid gland of man consists of two lobes united by a narrower portion or isthmus. His maintains that the three parts of this gland arise separately. The lateral lobes originate independently of the isthmus; the latter is derived from a median tubular outgrowth from the ventral wall of the embryonic pharynx, known as the thyro-glossal duct. This duct bifurcates at its lower end and gives rise to the thyroid isthmus, which fuses with the lateral thyroid rudiments, and assists in forming the lobes of the gland. Originally the duct extends as far upwards (forwards in the embryo) as the dorsum of the tongue, but as the body of the hyoid bone develops, the duct becomes divided into an upper segment, the lingual duct, and a lower portion, the thyroid duct: in the ordinary course of development these ducts disappear, but in some cases they persist and attain a fair size. Thus the central part of the thyroid may be regarded as the remnant of a secreting gland provided with a duct which conveyed the products of the gland into the pharynx.

There are at least three abnormalities which appear to be associated with vagaries of the thyro-glossal duct, viz. (1) lingual dermoids, (2) median cervical fistulæ, (3) accessory thyroids.

1. **Lingual Dermoids.**—Dermoids arising in the tongue have been many times observed and reported as sebaceous cysts. Barker,* however, published a clear account of their nature,

* *Trans. Clin. Soc.*, vol. xvi. 215.

and showed them to be true dermoids. Subsequent research has proved that those dermoids which occupy a central position in the tongue between the genio-hyo-glossi muscles arise in the lingual duct. When fully developed this duct extends from the foramen cæcum to the posterior surface of the basi-hyoid. Occasionally the duct is so large that a probe may be introduced into it from the foramen cæcum. The duct lies exactly between the genio-hyo-glossi muscles, and is not unfrequently replaced by a solid fibrous cord. It is easy to understand that if a persistent duct should have its upper end obstructed or obliterated, the continual shedding of the epithelium which lines it and the accumulation of sebum from the glands would convert it into a cyst, which in due course would assume such a size as to come within the range of clinical observation.

The walls of lingual dermoids are composed of fibrous tissue, lined internally with squamous epithelium beset with hair and sometimes with glands. The contents of these cysts are epithelial cells, hair, sebum, and cholesterine. Should the cyst burst, then it would suppurate and become very disagreeable.

Lingual dermoids are occasionally sufficiently large to attract attention in infants, but most of the examples come under notice in adolescents.

Dr. Wellington Gray * reported an example (Fig. 201) in which the dermoid protruded from the man's mouth, and was as large as a medium-sized cocoanut. It completely filled the space between the jaws, the upper incisor teeth projected horizontally forwards, whilst those of the lower jaw were not only loosened but their direction was reversed. The tumour caused a swelling in the neck as low as the thyroid cartilage. The patient's voice was an indistinct mumble, and only fluid food could be taken. The tumour was successfully removed: it contained forty ounces of pultaceous matter, consisting of epithelium, fat, and cholesterine. The walls were lined with epithelium.

In addition to the common variety of dermoid, the tongue is occasionally occupied by tumours which in structure resemble the thyroid gland. They occur in the neighbourhood

* *Trans. Clin. Soc.*, vol. xxiv. 68.

of the foramen cæcum, between the genio-hyo-glossi muscles. Bernays has given a careful description of such a tumour which he removed from the tongue of a girl seventeen years of age. In the account of the case Bernays * clearly associates the tumour with the lingual duct.

2. **Median Cervical Fistulæ.**—These openings occur singly, and open at some point in the middle line of the neck between the hyoid bone and the top of the sternum. The common

Fig. 201.—Large lingual dermoid, protruding from the mouth. (*Gray.*)

situation is a little below the level of the cricoid cartilage. Median cervical fistulæ differ from those arising in connection with branchial clefts in the fact that they are never congenital; they may occur soon after birth or make their appearance as late as the fourteenth year.

Raymond Johnson † has clearly pointed out that median cervical fistulæ are often preceded by a swelling in the middle

* *St. Louis Medical and Surgical Journal*, vol. iv. 201. See also Wolf, Langenbeck's *Arch.*, bd. xxxix. 224; Warren, *International Journal of Med. Science*, October, 1892, vol. civ. 277; and McIlraith, *Brit. Med. Journal*, 1896, vol. ii.

† *Trans. Path. Soc.*, vol. xli. 325.

line of the neck which either ruptures or is opened by the surgeon; this leaves a sinus which never closes.

The fact that these median cervical fistulæ are preceded by a swelling is a fact of great interest. Cusset * described the case of a little girl five years old, in the middle line of whose neck there was a swelling below the hyoid bone; this opened and discharged a glairy fluid, and left a sinus that passed upwards to the base of the tongue; but Johnson seems to be

Fig. 202.—Median cervical fistula in a man aged 23 years. The fistula appeared when he was three years old.

the first to emphasise the fact that *a swelling in the neck precedes the sinus.*

The following is a common example of a median cervical fistula. The patient, twenty-three years of age, presented in the lower third of the neck a depression, the floor of which was puckered and scar-like (Fig. 202). At the upper part of this bay or recess there was a rounded opening from which clear mucus exuded. An ordinary probe introduced into this hole easily passed upwards in the middle line directly beneath the

* "Kystes et Fistules d'Origine Branchiale." Paris, 1877.

skin, to stop at the middle of the lower border of the basi-hyal. The opening in the neck had existed as long as he could remember, but his parents told him that it appeared when he was about three years old. Ordinarily the fistula caused no inconvenience, but during the past two years it seemed subject

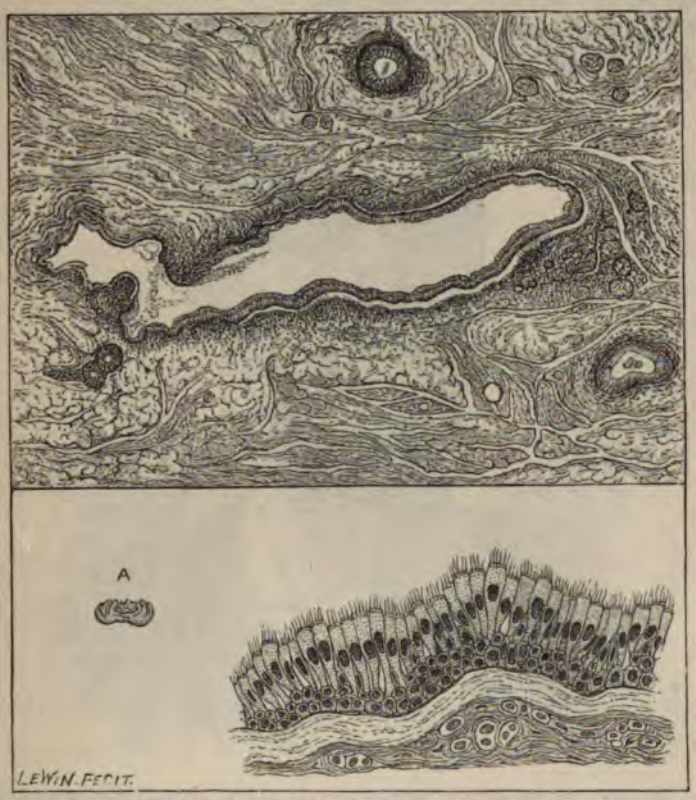

Fig. 203.—Section of a persistent thyroid duct.
A represents the duct of natural size. The lowest drawing shows the epithelium more highly magnified.

to catarrh, and the excessive flow of mucus caused him much inconvenience, so it was dissected out.

The duct was lined with columnar ciliated epithelium. The tissue forming the walls of the duct resembled atrophied thyroid tissue; here and there (Fig. 203) isolated channels could be seen in section lined with columnar epithelium.

Occasionally a persistent thyroid duct is so large as to form

a conspicuous vertical ridge in the middle of the neck in association with a median cervical fistula (Fig. 204).

Thus a median cervical fistula is in striking contrast to branchial fistulæ, which are always lateral in position and in close relation with the anterior border of the sterno-mastoid muscle, and are always congenital.

Our knowledge of the nature of these fistulæ was not very

Fig. 204.—Median cervical fistula associated with a persistent thyroid duct.

satisfactory until the publication of an able paper by Marshall,* detailing the anatomy of the parts in the neighbourhood of the hyoid bone of a child five years old, who had a median sinus in the neck. The patient was admitted into a hospital for the purpose of having the duct excised; it contracted diphtheria and died before the operation could be performed.

In the median line of the neck, 2.5 cm. (1″) above the

* *Journal of Anat. and Phys.*, vol. xxvi. 94.

sternum, there was a sinus which, during life, discharged a small quantity of mucous fluid. From this opening a hard cord could be felt extending up to the hyoid bone. On dissecting the front of the neck this cord was found to be tubular and patent up to within 1 cm. of its termination; the upper end was firmly attached to the hyoid bone, the lower end dilated into a thin-walled sac opening on to the surface of the skin. The sac and tube lay between the skin and the anterior layer

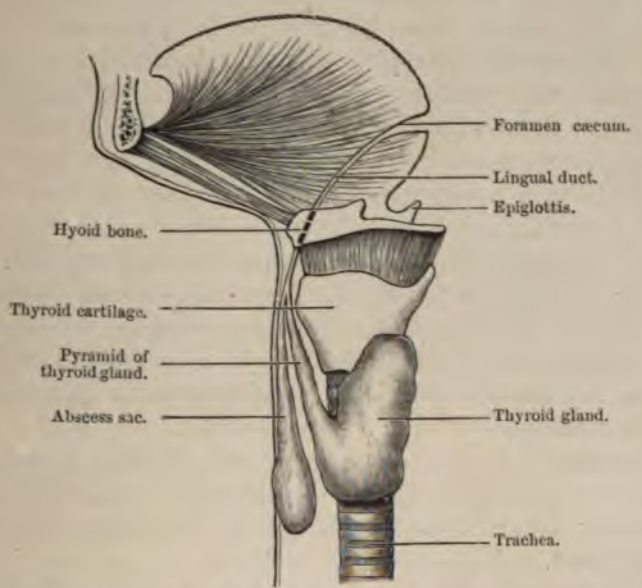

Fig. 205.—Diagram to show the relation of parts in a case of median cervical fistula (*After C. F. Marshall.*)

of the deep cervical fascia; at no place was there any connection with the thyroid gland.

On dividing the hyoid bone the tube could be traced as an ill-defined fibrous cord on to its dorsal surface, to which it was closely attached, and through the substance of the tongue to the foramen cæcum. About 2 cm. from the foramen it again became patent, and continued so up to the surface of the tongue. The canal was thus open at both ends, but impervious in the middle.

On further dissection a lobus pyramidalis was found

connected with the left side of the thyroid isthmus, its upper end being united to the median fibrous cord at the same place as the above-mentioned canal. In other words, the fibrous cord behind the hyoid bone was continuous both with the pyramidal lobe of the thyroid and with the tube leading to the superficial sinus (Fig. 205).

The relations of the parts indicate the probable mode by which these median fistulæ arise; they are probably retention cysts formed in a persistent thyroid duct, and the pressure of the cyst ultimately causes the skin to yield and form a sinus.

3. **Accessory Thyroids.**—The consideration of accessory thyroids naturally follows on the description of median cervical fistulæ, for there is good reason to believe that the thyroid duct is the source of some of these bodies. They have long been known,* and in recent years have been carefully studied. They occur most frequently in the neighbourhood of the hyoid bone and in the hollow formed by the two lobes of the thyroid gland. As the thyro-glossal duct is directly associated with the formation of the thyroid body, and as median accessory thyroids are found directly in its track from the hyoid to the thyroid isthmus, it is not unreasonable to regard these little bodies as remnants of this remarkable tube.

Accessory thyroids occasionally arise in connection with the germs of the lateral lobes of the thyroid: these are most commonly found in the neighbourhood of the greater cornua of the hyoid.

Accessory thyroids are in the main innocent structures, but occasionally they give rise to troublesome tumours. It is well known that when the thyroid body becomes goitrous, and accessory thyroids co-exist, the latter will enlarge and become, in fact, goitrous. Apart from this, accessory thyroids will enlarge on their own account and give rise to tumours that closely simulate unilateral enlargement of the thyroid, and occasionally give rise to bronchoceles of moderate dimensions.

Dermoids of the Rectum.—In order to appreciate the nature of dermoids arising in the immediate neighbourhood of the rectum, it will be necessary to consider a few points

* Albers' "Atlas der Path. Anat.," Abth. ii., Taf. xxv., xxvi., and xxxix.; also Virchow, "Die Krankhaften Geschwülste," bd. iii. s. 13.

connected with the embryology of this portion of the alimentary canal. In the early embryo, the central canal of the spinal cord and the alimentary canal are continuous around the caudal extremity of the notochord. This passage, which brings the developing cord and gut into such intimate union, is known as the neurenteric canal. When the proctodæum invaginates to form part of the cloacal chamber it meets the gut at a point some distance anterior to the spot where the neurenteric canal opens into it; hence there is for a time a segment of intestine extending behind the anus, and termed in consequence the "post-anal gut." Afterwards this post-anal section of the embryonic intestine disappears, leaving merely a trace of its existence in the small structure at the tip of the coccyx known as the coccygeal body. There is good reason to regard the post-anal gut as the source of that variety of congenital sacro-coccygeal tumour which was named by Braune * and several writers who followed him "congenital cystic sarcoma." These will be referred to as tumours of the **post-anal gut.** In addition, it will be necessary to consider dermoids situated between the rectum and the hollow of the sacrum—**post-rectal dermoids**—and certain pedunculated tumours situated within the rectum—**rectal dermoids.**

Tumours which arise in the post-anal gut exhibit a definite structure; they are composed of closed vesicles lined with glandular epithelium, and contain glue-like fluid. Many of these tumours are composed of cysts and duct-like passages lined with cubical epithelium, held together by richly cellular connective tissue. In many situations the epithelium is columnar, set upon flatter cubical cells. The cysts are filled with ropy mucus, and vary in size from a nutshell to the smallest space visible to the naked eye; many contain intracystic processes. These tumours present such very definite characters that they are sure to attract attention, and their large size makes them very conspicuous.

Middeldorpf † was the first to associate clearly a congenital sacro-coccygeal tumour with the post-anal gut. His specimen was removed from the neighbourhood of the anus of a girl a

* *Die Doppelbildungen*, 1862.
† Virchow's *Arch.*, bd. ci. 37.

year old. The tumour contained connective tissue, mucous membrane with characteristic follicles, submucous tissue, longitudinal and circular layers of muscle fibres. I had come to the same conclusion in regard to the probable origin of these tumours before the publication of Middeldorpf's paper; his case is the most conclusive on record.

Post-rectal dermoids are very rare, and do not form such large projecting masses as the preceding species. In many instances they are not noticed until after infant life, and their clinical tendencies are of a different character. It is also

Fig. 206.—Rectal dermoid. (*After Danzel.*)

somewhat remarkable that dermoids, although they are met with in many parts of the body, contain teeth only in certain situations; the post-rectal region comes into this category.

Such dermoids also occur as surgical surprises, especially when they attain very large dimensions and extend upwards behind the pelvic peritoneum of men and women. Ord * recorded a remarkable case which occurred in a man twenty-eight years old; the dermoid weighed fourteen pounds. Page † successfully removed a dermoid, weighing three pounds, which occupied the hollow of the sacrum in a woman of forty-seven years; it lay behind the rectum.

Skutsch ‡ has recorded two examples of post-rectal der-

* *Med.-Chir. Trans.*, vol. lxiii. 1.
† *Brit. Med. Journal*, 1891, vol. i. 406.
‡ *Zeitsch. für Geb. und Gyn.*, bd. xl. 353.

moids, and collected the chief German cases. One of the records is interesting from the fact that the patient was pregnant, and he was able to empty and partially enucleate the dermoid through an incision in the perineum without disturbing the pregnancy.

Post-rectal dermoids sometimes open spontaneously in the perineum ; the fistula is usually situated in the middle line of the perineum near the tip of the coccyx. The student should compare pharyngeal and post-rectal dermoids ; they are probably teratomata (see Chap. XLIX).

Rectal Dermoids.—Several examples of dermoid tumours have been described growing from the mucous membrane of the rectum ; a curious feature in these cases is that the tumours are furnished with long locks of hair, which protrude from the anus and annoy the patients. Like post-rectal dermoids, they sometimes contain teeth.

Danzel * observed such a tumour in a woman twenty-five years of age. It was as large as an apple, and was said to contain brain substance enclosed in a bony capsule ; a tooth projected from it (Fig. 206). This woman was troubled with long hairs which protruded at the anus, and she used to pull them out with her hands.

* Langenbeck's *Arch.*, bd. xvii. s. 442. See also Clutton, *Trans. Path. Soc.*, vol. xxxvii. 252 ; and Port, *ibid.*, vol. xxxi. 307.

CHAPTER XLII.

TUBULO-DERMOIDS (*concluded*).

BRANCHIAL FISTULÆ AND CYSTS.

SINCE 1825, when Rathké found evidence in the embryos of pigs, horses, and chicks of the branchial clefts so characteristic of fishes, many eminent anatomists have confirmed his observations. Rathké was also fortunate enough to detect the fissures in an early human embryo (Fig. 207).

Fig. 207. — Early human embryo, showing the gill-clefts.

It appears that in 1789 Hunczowski * described two cases of congenital fistulous openings in the side of the neck. In 1829 Dzondi described similar openings under the name of tracheal fistulæ; and Ascherson, three years later, showed that such fistulæ communicated with the pharynx and not with the trachea.

Heusinger,† in 1864, collected a number of recorded cases, and was the first clearly to associate these congenital cervical openings with the branchial clefts detected by Rathké.

The human embryo has four branchial clefts. Of these, the first becomes the tympano-Eustachian passage, and the three posterior clefts usually suffer obliteration. Frequently, one or more of the clefts persist wholly or in part and are then known as "congenital cervical fistulæ." These fistulæ appear as fine canals, capable of admitting a bristle, and some a fine probe. The orifice usually opens in the neck, but when complete, into the pharynx also. There is reason to believe that they may open into the pharynx, but end externally as *culs-de-sac*. One, two, or three fistulæ may be present in the same individual; they have a great tendency to be bilateral, to affect several members of the same family, and to be trans-

* Fischer, *Deutsche Zeitsch. für Chir.*, bd. ii.
† Virchow's *Arch*, bd. xxix. 358.

mitted to several generations. The canals, which may vary in length from 2 to 5 cm., are lined by mucous membrane, sometimes with ciliated epithelium, or by skin containing sebaceous glands. The lining membrane of the canal usually secretes a thin mucous fluid, which may become increased during catarrhal conditions of the respiratory passages. Occasionally the canal inflames and an abscess results, which may give rise to considerable pain and difficulty in deglutition. The external orifice of a branchial fistula may be indicated by a tag of skin, containing a piece of yellow elastic cartilage. These cutaneous processes, or cervical auricles, as they are called, are of sufficient interest to require separate consideration.

Neglecting for the present the first cleft—the tympano-Eustachian passage—it may be convenient to consider the situations usually occupied by these fistulæ when they occur in man.

The **external orifices** of the fistulæ are apt to vary, but they usually open in the positions shown in Fig. 208. The first becomes the tympano-Eustachian passage; the second opens close behind the angle of the jaw anterior to the line of the sterno-mastoid muscle; in a few cases it may be on a level with, and slightly posterior to, the lobule of the pinna. The third is situated on a level with the thyro-hyoid space close to the anterior border of the sterno-mastoid; this position is very constant. The fourth usually opens near the sterno-clavicular articulation; it may open 3 or 4 cm. higher in the neck, but always in relation with the anterior border of the sterno-mastoid muscle.

The **internal orifices** of these fistulæ may be indicated in the following way. The second opens into the recess containing the tonsil; the third and fourth are in relation with the sinus pyriformis. To reach this sinus, a fistula corresponding to the third cleft must pass over the loop formed by the superior laryngeal nerve. Hueter's * observation is interesting in this connection: "In a young fellow who wished to become a trumpeter I dissected out one of these fistulous tracks, following it between the two carotids to the pharyngeal cavity."

* "Grundriss der Chirurgie," vol. ii. 328, 1st edition.

Abnormal persistence of branchial clefts occurs in four forms :—

1. Complete fistula.
2. The external half persists.
3. The internal half persists.
4. The external and internal orifices are obliterated, but an intermediate section persists.

The first form, complete fistulæ, as far as my own observa-

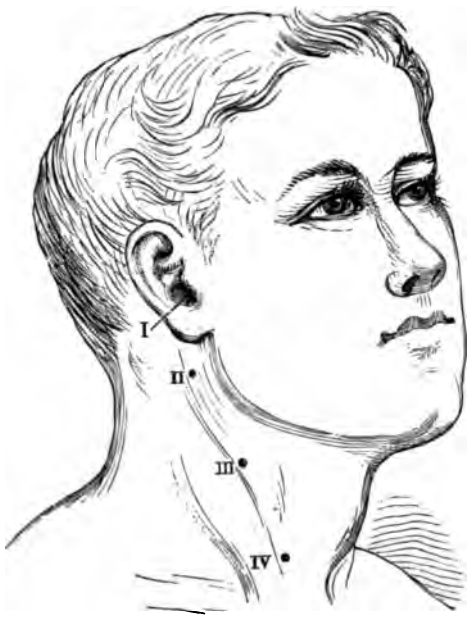

Fig. 208.—Diagram to indicate the orifices of persistent branchial fistulæ.

tions extend, occurs most frequently in connection with the second cleft. In one case, a youth aged fifteen years, the communication with the pharynx was so complete that when he swallowed milk some of the fluid occasionally passed through the fistula and appeared at the cutaneous orifice. In another case, that of a little girl aged ten, saliva issued at the cervical orifice when the child had been talking freely and excited the parotid gland.

The second set of cases, those with external openings, but

blind internally, are the most common examples, and need no further comment.

The third class are rarely recognised; this is not remarkable when we remember that they open into the pharynx, but end externally as *culs-de-sac*. Heusinger was of opinion that some pharyngeal diverticula are of this nature, and Sir James Paget

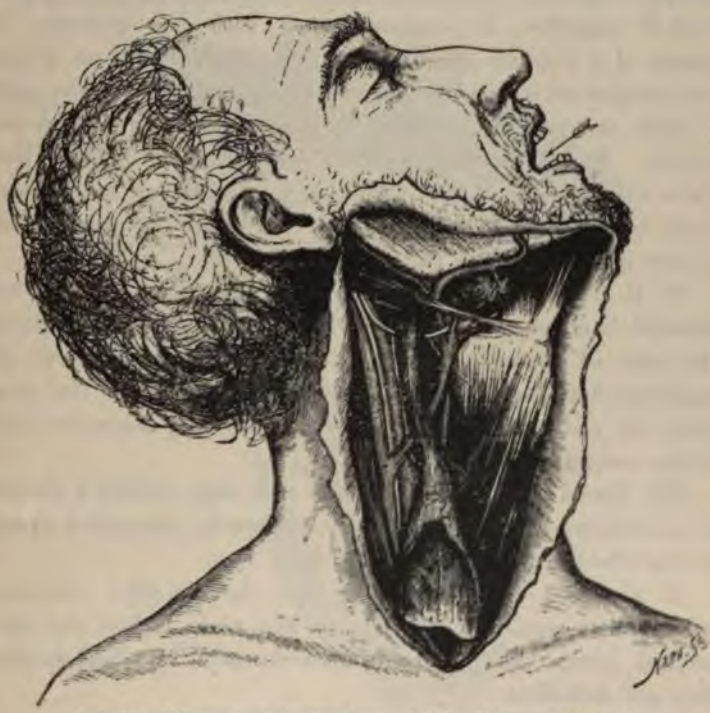

Fig. 209—Pharyngeal diverticulum. (*After Morrison Watson.*)

refers to the probability that some rare instances of diverticula from the pharynx may be regarded as dilatations of portions of branchial fistulæ, closed externally, but remaining open within. The most remarkable case of this nature that has been placed on record is the specimen that occurred in the body of an adult male dissected and described by Morrison Watson * (Fig. 209).

A tube, terminating inferiorly in a *cul-de-sac* containing a

* *Journal of Anatomy and Physiology*, vol. ix. 134.

large quantity of grumous material, was found extending from the pharynx, immediately behind the tonsils, to the inter-clavicular notch. This tube possessed muscular walls, and in the deep part of its course passed between the fork of the carotids and over the loop of the superior laryngeal nerve; its lower part was parallel with the anterior border of the sterno-mastoid muscle; it rested on the sterno-hyoid and sterno-thyroid muscles. It communicated with the pharynx by means of a slit-like opening, not more than 3 mm. in length, the margins of which were so closely in contact that the entry of solid particles into it from the mouth must have been prevented. The diverticulum itself increased in calibre from above downwards, so that whilst at the upper end a crow-quill could with difficulty be introduced, at the lower a pencil could readily be passed along the lumen of the tube.

It is further noteworthy that the pharyngeal orifice was situated between the lower jaw and the stylo-hyoid ligament. Its point of departure from the pharynx corresponds to the supratonsillar fossa. The muscle fibres were, for the most part, red and striated, and the mucous lining resembled that of the œsophagus.

The fourth class, those closed at each end, leaving a portion of unobliterated canal in the neck, cannot be recognised except by the effects to which they give rise.

It has long been suspected that the so-called sebaceous cysts which occasionally occur in the neck, below the deep cervical fascia, take origin in unobliterated branchial spaces; they are dermoids.

A retention cyst, arising in a partially obliterated branchial cleft, need not necessarily contain sebaceous matter; it may be filled with mucus. This apparent contradiction is capable of easy explanation. The internal segment of a branchial fistula is lined by mucous membrane continuous with that of the pharynx, whilst its external segment is a continuation of the surface epithelium of the neck. It is on this account that some branchial fistulæ possess ciliated epithelium, others squamous, and so forth. If a cystic dilatation arise in connection with the inner segment, a cavity with mucous contents would be the result, whilst in a similar cyst arising from the

external segment epidermal scales, sebaceous matter, and cholesterine would be expected. As far as my own observations go, mucous cysts originating in this manner attain larger dimensions than the dermoid varieties. Cysts arising in persistent branchial spaces must not be confounded with lymphatic cysts (p. 163).

Examples of persistent branchial clefts have been observed

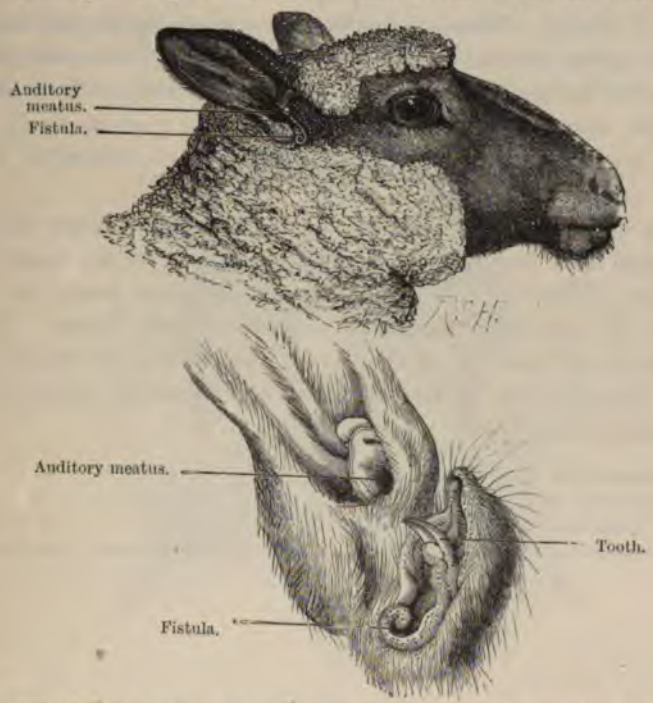

Fig. 210.—Head of a sheep with a branchial fistula, cervical auricle, and tooth In the lower figure the auricle and tooth are shown of natural size.

in horses and sheep. Heusinger * has described examples in horses; they open immediately below the pinna, and are noticed more frequently in carriage than in draught horses, as the secretion from the fistula soils the surrounding skin and attracts the attention of the grooms.

A persistent branchial cleft is occasionally observed in sheep (Fig. 210), surmounted by a prominent cervical auricle beset on its posterior surface by a number of processes resembling the

* *Deutsche Zeitschrift für Thiermedicin*, bd. ii. 1, 1867

buccal papillæ of sheep. Protected by this auricle there was a slender, ill-formed, incisor tooth mounted on a pedicle of bone, surrounded by mucous membrane.* It is preserved in the museum of the Royal College of Surgeons. Kostanecki † has since published an account of a similar specimen. (See also Gurlt.‡)

Teeth are occasionally associated with the second branchial cleft of horses. These specimens throw some light upon teeth found on the petrosal bones of oxen, of which some examples are preserved in the Veterinary Museum at Alfort. It is also possible that some of the curious cases of cervical teeth in man, usually described as errant wisdom teeth, belong to the same category.

Rowley § has described and figured a small tumour which he found in a frog, *Rana temporaria*, posterior to the angle of the jaw. This on microscopic examination was found to be made of concentric laminæ of epidermis and dermis. The structure and position of the tumour led Rowley to regard it as a dermoid due to the inclusion of epithelium during the occlusion of a gill-cleft in larval life.

* *Trans. Path. Soc.*, vol. xlii. 477.

† Virchow's *Arch.*, bd. cxxiii. 401.

‡ "Thierische Missgeburten," 1877. Taf. xv.

§ *Transactions of the Leicester Literary and Philosophical Society*, April, 1896.

CHAPTER XLIII.

CERVICAL AURICLES; DERMOIDS AND FISTULÆ OF THE AURICLE.

Cervical Auricles.—In describing branchial fistulæ in the preceding section it was mentioned that the cutaneous orifices are in some cases surmounted by tags of skin. These tags,

Fig. 211.—Cervical auricles in a child.

or processes, sometimes occur unassociated with fistulæ, but always in situations where fistulæ, when present, open on the skin. Usually they are short, in some cases mere nodules, but in others form prominences 2 to 3 cm. in height. These processes have been described under a variety of names, and classed among tumours, but at the present time they are commonly known as **cervical auricles.**

Like branchial fistulæ, they are always congenital, and sometimes affect several members of a family. The mother may have a cervical auricle, and one of her children a branchial

fistula, whilst another child may have an auricle associated with a fistula; they are often symmetrical (Fig. 211). A cervical auricle consists of an axis of yellow elastic cartilage, which sometimes extends deeply into the tissues of the neck; muscle-fibres from the platysma are attached to the cartilage, and the whole is surmounted with skin containing hairs and sebaceous glands. A small arterial twig runs into the auricle

Fig. 212.—Head and neck of a goat with cervical auricles.

and ramifies in the fibrous tissue and fat in which the cartilage is embedded.

Thus, structurally, cervical auricles are identical with the normal auricle or pinna, and they agree with the pinna morphologically, inasmuch as they are developed like it from that portion of a branchial bar which is directly in relation with the corresponding cleft.

In sharks the gill-slits open separately on the surface of the body; from the branchial bar, anterior to each slit, a fold of skin is formed which closes upon the slit like a lid, and is named from this resemblance the operculum. In mammalian

embryos a slight prominence or tubercle is for a time visible anterior to each of these clefts. In most cases the tubercles disappear from the posterior bars, but those in relation with the anterior cleft enlarge and are joined by accessory tubercles to form the pinna. Thus embryology has taught me to regard the pinna as consisting mainly of an operculum which has become modified for acoustic purposes, for we may regard the tubercles formed in relation with the branchial clefts of man as representative of the opercula of certain *Ichthyopsida*. As the pinna is mainly derived from opercular tubercles, and cer-

Fig. 213.—Horned sheep with cervical auricles.

vical tubercles, in all probability, represent persistent opercular tubercles, it is reasonable to term them cervical auricles.

The homology of at least a part of the pinna and cervical auricles with the opercula of fish has been made clearer by Schwalbe's * discovery of auricular tubercles in the embryo of the turtle (*Emys lutaria taurica*); in the adult condition chelonians have no vestige of an auricle.

Cervical auricles occur in mammals other than man. Heusinger, in 1876, mentioned the frequency with which pendulous tags of skin occur in the necks of pigs, goats, and sheep, yet very little has been done to extend his observations.

The anatomy of these auricles (which are especially

* "Ueber Auricularhöcker bei Reptilien." *Anat. Anzeiger*, vi. Jahrgang 1891, Nr. 2.

common in Egyptian goats) is similar to that of cervical auricles in man: there is an axis of yellow elastic cartilage embedded in fibrous tissue and fat, the whole being covered with hairy skin. In size they are very variable, and in the goat from which the drawing (Fig. 212) was made the auricles were unusually large. Cervical auricles are not common in sheep (Fig. 213); they are occasionally associated with a persistent second branchial fissure (Fig. 210).

In Great Britain cervical auricles are rare in pigs, but Pro-

Fig. 214.—Head of a pig with cervical auricles (the Bell-pig of Australia).

fessor Anderson Stuart has drawn attention to the existence in Australia of a breed of pigs known as the Bell-pig, on account of the presence of pendulous folds of skin in the neck (Fig. 214). It may here be mentioned that in Germany these auricles in sheep and pigs are known as *Glöckchen or Berlocken*.

Before concluding the subject of cervical auricles reference must be made to the presence of these appendages on the necks of satyrs. Mr. Shattock drew my attention to the fact that in the statues of many satyrs we find in the neck, in the situation where cervical auricles are usually found, prominences which

in their variety of form resemble the cervical auricles of goats and men. In the ægipans (goat-footed satyrs) the auricles in the neck are pointed like their ears, and are sessile, but in the fauns they are usually pendulous. In the statues of many satyrs, both fauns and ægipans, no auricles are represented,

Fig. 215.—Faun and goat with cervical auricles.

and they are less constant in modern than in ancient statues of fauns, and in some they are unilateral.

It is an interesting subject for speculation whether the sculptors obtained their notion of the cervical auricles from human models or from goats. The pendulous forms were probably copied from goats. This is well illustrated in the faun from the Capitol (Fig. 215), for we see at his side a goat with unmistakable auricles, and a goat's skin is thrown over the faun's shoulders. The bestial element in the composition of these mythical satyrs is evident in more ways than one.

The ægipans are goat-legged, and their tails, as well as those of their fabled sensual relatives the fauns, are excellent copies of goats' tails.

A study of many satyrs induces me to believe that some of the auricles are copies from human models. A good instance of this is a marble head in the Glyptothek at Munich, described as "The Head of a Laughing Faun." In this specimen the auricle is unilateral and identical in shape with those in the necks of children.

AURICULAR DERMOIDS AND FISTULÆ.

We may assume that the auricle or pinna consists mainly of an enormously developed operculum which has become

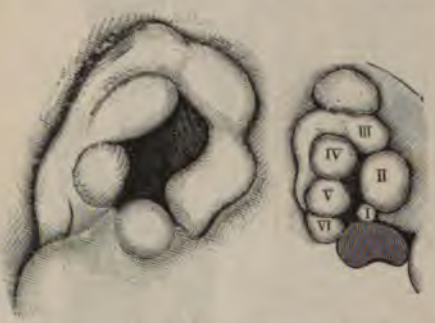

Fig. 216.—Two drawings representing the development of the auricle (see text below). (*Modified from His.*)

utilised for acoustic purposes. It has already been pointed out that in the embryo each branchial cleft is surmounted by a swelling or tubercle corresponding to the operculum of the shark. In mammals, and as Schwalbe has shown, in reptiles, the first cleft, which ultimately becomes modified into the tympano-Eustachian passage, is surrounded by additional tubercles, some of which belong to the mandibular, and others to the hyoid bar (Fig. 216). It is by the subsequent growth and coalescence of these tubercles that the auricle is formed. These tubercles have received the following names from His * :—I., tuberculum tragicum ; II., tuberculum anterius ; III., tuberculum intermedium ; IV., tuberculum anthelicis ; V., tuberculum antitragicum ; and VI., lobulus.

* *Anat. Men. Embryonen*, 1885, Heft iii.

The subsequent fate of these tubercles may be briefly given. The tuberculum tragicum unites across the cleft with the tuberculum antitragicum, the space formerly separating them being simply indicated by the incisura intertragica. The tuberculum intermedium is the source of the helix, whilst the tuberculum anthelicis furnishes the anthelix; the nodule VI., cut off by the fusion of tragus and antitragus, becomes the lobule.

Imperfections in the development and union of these tubercles will serve to explain several congenital defects to

Fig. 217.—Congenital fistula in the helix. (*After Paget.*)

which the auricle is liable. Of these, three are of especial interest:—(1) Auricular fistulæ; (2) dermoids; (3) accessory tragus.

1. **Auricular Fistulæ.**—Heusinger seems to have been the first to describe a congenital fistula in the helix. For the first complete account of these fistulæ in England we are indebted to Sir James Paget.* The fistula usually appears as a small opening leading into a canal ending blindly in the substance of the helix. The auricle may be of good shape, but often it is deformed (Fig. 217). Usually a small quantity of

* *Med.-Chir. Trans.*, vol. lxi. 41, 1878.

greasy material exudes from the orifice of the sinus, which varies from 2 to 6 mm. in depth. These fistulæ sometimes exist in individuals who also have branchial fistulæ; or one member of a family will have a congenital fistula in the auricle, and another a congenital fistula in the neck; they are hereditary.

It is far rarer to find congenital fistulæ in the lobule. Very few examples have been observed. A little girl known to me was born with a perforation in the lobule of the left auricle exactly in the spot for wearing an earring, and to this day she wears a ring in this lobule and refuses to have the other pierced.

The facts now at our disposal enable us to understand how such fistulæ arise, for it seems reasonable to conclude that if

Fig. 218.—Auricle with a reduplicated tragus.

Fig. 219.—Auricle of a fœtus with an unusually large Woolner's tip furnished with a tuft of lanugo.

the various lobules which conspire to form an auricle unite imperfectly, the intervening spaces would persist as sinuses or fistulæ.

2. **Auricular Dermoids.**—From what has just been stated regarding the probable mode of origin of auricular fistulæ, it will be obvious that if unobliterated skin-lined spaces are left between the tubercles uniting to form the auricle, and the skin lining such spaces possesses glands (sequestrated tracts of skin are unusually rich in sebaceous glands), we have in such a space a potential dermoid.

The auricle is not an uncommon situation for cysts often described as sebaceous; they are usually small, but sometimes attain the dimensions of a cherry, or even larger. When these supposed sebaceous cysts are examined microscopically they sometimes turn out to be dermoids. It is a curious fact that

unless small dermoids in unusual situations are very cautiously examined, they run a great chance of being put aside as sebaceous cysts.

Auricular dermoids of fair size sometimes occupy the groove between the pinna and the mastoid process; if allowed to grow they will form a deep hollow in the underlying bone.

3. **Accessory Tragus.**—One of the commonest malformations of the pinna is reduplication of the tragus: the accessory tragus is extremely variable in shape; often it assumes the form of a low conical projection in front of or above the tragus (Fig. 218); sometimes it is pedunculated and hangs as a small cutaneous tag slightly in front of the tragus, beset with pale delicate hair. It is curious that an accessory tragus, a Woolner's tip (Fig. 219), or a mandibular tubercle (Fig. 189), is usually covered with long lanugo.

Occasionally an accessory tragus is associated with a circular cicatrice-like depression in the cheek immediately in front of the pinna. It is a fact of some interest that malformations of the tragus, and the presence of an accessory tragus, are often associated with defects in the mandibular fissure, such as macrostoma, mandibular fistula, and tubercle (Fig. 223).

CHAPTER XLIV.

MOLES.

MOLES are pigmented and, usually, hairy patches growing on the skin. They are congenital, or appear during the first few weeks after birth. These patches vary greatly in size; many are no bigger than split peas, whilst others cover an extensive area on the face, the trunk, or the limbs.

The common variety consists of a slightly raised brown patch; it is sometimes quite black, and is, as a rule, covered abundantly with hair, which is commonly short, like that upon the skin covering the trunk of a dog. Occasionally, however, it is as long as that naturally found upon the scalp. The hairs are furnished with sebaceous glands, and sweat glands are often present. The amount of pigment varies; occasionally it is so abundant as to produce an inky blackness. Moles are very vascular, but the most striking feature of their histology is the fact that the tissue immediately underlying them is arranged in alveoli, and is identical with the structure found in "alveolar sarcoma."

Moles bleed freely when their surfaces are abraded or incised. They are also liable to ulcerate spontaneously; the ulcerated surface bleeds freely. The most important change to which they are liable is to become later in life the starting-point of melanomata, some of which are very infective, and quickly destroy life. (See p. 80.)

When very large moles occur on the trunk the hairy part is sometimes very sensitive, almost hyperæsthetic. In large moles pendulous skin folds are sometimes present; these folds are large in the young, but, as a rule, they shrink and become quite small in the adult. As many as fifty moles may be present on one individual. When a mole is extensive, and occurs in an exposed situation (Fig. 220), it is a serious disfigurement. The relation of moles and plexiform neuromata is described on p. 143.

Small hairy moles do not, as a rule, cause much inconvenience even when they occur on the face, in which situation they are known as "beauty spots." A small hairy mole on a fair cheek is regarded often as an additional charm rather than a disfigurement, if we can trust the taste of story-tellers and poets.

In the "Arabian Nights" the allusions are many; thus the

Fig. 220.—Extensive hairy mole upon the face of a boy a year old.

youth in the Eldest Lady's tale says: "Persian poets have a thousand conceits in praise of the mole." Some of these allusions are certainly exquisite. Here is an example:

> "A nut-brown mole sits throned upon a cheek
> Of rosiest red beneath an eye of jet."

English writers often refer to moles. Marlowe, in his powerful tragedy *Dr. Faustus,* when he causes Alexander and his paramour (Act iv. sc. i.) to appear before Charles, Emperor of Germany, makes the emperor say:

"I have heard it said,
That this fair lady, when she lived on earth,
Had on her neck a little wart or mole."

There are numerous references to moles scattered in Shakespeare's plays. In *Cymbeline* all who have read the play will remember the subtile use Iachimo makes of the fact that she had

"On her left breast
A mole cinque-spotted, like the crimson drops
I' the bottom of a cowslip."

In the *Comedy of Errors*, Dromio of Syracuse, in his comical account of the kitchen wench, tells his master that she knew what private marks he had about him, such as "the mole in my neck, the great wart on my left arm," etc. (Act iii. sc. ii.)

Moles on the Conjunctiva.—The mucous membrane lining the ocular surface of the eyelids, and covering the cornea and adjacent portions of the eyeball, occasionally presents patches of skin, which, in appearance and structure, are identical with hairy moles.

These dermoid patches, or conjunctival moles, occur most frequently at the margins of the cornea, and usually in the line of the palpebral fissure—that is, directly in the equator of the cornea; but they are by no means confined to these situations. Usually they are limited to the conjunctiva covering the sclerotic, or trespass but little on the cornea. Sometimes, however, they involve a considerable extent of the corneal surface (Fig. 221).

Wardrop * described a conjunctival mole in a man fifty years of age; it was congenital. Twelve long hairs grew from its middle, passed between the eyelids, and hung over the cheek. These hairs did not appear until the sixteenth year, at which time the beard began to grow.

Occasionally a mole will be found on each side of the cornea in the line of the palpebral fissure. A very rare variety is limited to the caruncle. A good example is depicted in Fig. 222, associated with an eccentric pupil. This is simply an excessive development of the delicate hairs that normally beset the caruncle.

* "Morbid Anatomy of the Human Eye," 1834.

These moles are occasionally associated with malformations of the eyelids, especially the one known as coloboma of the upper eyelid, of which an example is given in Fig. 223. When this association occurs, the defect in the lid corresponds to the cutaneous patch on the conjunctiva. This combination

Fig. 221.—Conjunctival mole—common variety.

is of some importance, as it is used as evidence in support of an explanation that has been put forward in regard to these moles, based upon the development of the eyelids.

In the embryo the tissue covering the outer surface of the eyeball, which ultimately becomes the conjunctiva, is directly continuous and in structure identical with the skin at the margin of the orbit. Very early cutaneous folds arise, gradually

Fig. 222.—Mole on the caruncle, associated with an eccentric pupil. (*After Demours.**)

grow over the surface of the eyeball, and come into apposition at a spot corresponding to the future palpebral fissure. These folds ultimately become the eyelids. The surfaces of the folds, which are continuous with the covering of the eyeball, become converted into mucous membrane, and are termed conjunctiva. In every normal eye the conjunctiva bears evidence of its transformation from skin, inasmuch as the

* "Maladies des Yeux," 1818, pl. lxiv., fig. 1.

caruncle at its inner angle is furnished with delicate hairs. It is reasonable to suppose that, as the occlusion of the proper covering of the eyeball by the eyelids is the cause of the conversion of the conjunctiva into mucous membrane, if from any cause a part, or even the whole of it, were left uncovered, the

Fig. 223.—Conjunctival mole associated with coloboma of the eyelid, a mandibular tubercle, and accessory tragus. (*Cowell's case.**)

exposed part would persist as skin. This is precisely what occurs. When the eyelid is in the condition of coloboma (Fig. 223)--a defect due, in all probability, to the imperfect union of the embryonic eyelid to the skin covering the fronto-nasal plate—a piece of conjunctiva persists as skin, and forms a mole occupying the gap in the lid. Moles occur on the conjunctiva unassociated with coloboma, but in nearly every instance they are situated on the cornea in the line of the palpebral fissure. This circumstance would indicate that during development the conjunctiva was imperfectly covered by the developing lids. It should be remembered that in many eyes, exactly in

* *Trans. Ophthal. Soc.*, vol. xi. 214.

the situation in which moles are most frequently found, slight elevations or **pingueculæ** of the conjunctiva occur. These, when examined microscopically, will be found to contain epithelial elements.

In a few very exceptional cases the eyes have been found com-

Fig. 224.—Conjunctival mole in a sheep.

pletely covered with skin without any traces of eyelids. Such a condition is known as **cryptophthalmos,** and the explanation offered concerning it is, that in these cases the eyelids have failed to appear, and in consequence the conjunctiva has persisted as skin.

Conjunctival moles have been observed in horses, sheep, oxen, and dogs, and are furnished with hair or wool according to the nature of the tegumentary covering characteristic of the mammal in which they occur (Fig. 224).

CHAPTER XLV

OVARIAN DERMOIDS.

THE human ovary, in common with that of other mammals, presents three parts, each giving rise to cysts possessing distinctive features. The three cyst regions are: (1) oöphoron, (2) the paroöphoron, (3) the parovarium.

The **oöphoron** is the egg-bearing portion of the ovary, and is the source of three varieties of tumours: simple cysts, adenomata, and dermoids, all of which arise in the ovarian follicles. It is necessary to consider these three varieties of cysts under the heading of dermoids, because conglomerate tumours not unfrequently come to hand consisting of simple cysts, adenomata, and dermoids.

Simple Cysts.—These may be unilocular or multilocular. A small oöphoronic cyst is an enlarged ovarian follicle, and its walls are furnished with a well-developed membrana granulosa. In a very early stage it is easy to demonstrate the relation of such a cyst to the oöphoron. As the cyst enlarges it causes rapid absorption of the paroöphoron, and the region in which it arose is then not so easily demonstrable.

It is only by patiently waiting for opportunities of securing cysts in very early stages that it is possible to elucidate their mode of origin. Much of the confusion which obscures the pathology of this question is due to the fact that most investigators have devoted their attention mainly to large cysts.

In cysts containing three or four litres of fluid the walls will be found to consist of fibrous tissue; and epithelium is rarely detected. It is impossible to state definitely the size of a cyst in which the epithelium disappears. The absence of epithelium is due to atrophic changes, the consequence of the continual pressure exerted by the accumulating fluid. Precisely similar changes may be studied in the mucous membrane of greatly distended gall-bladders. In large multilocular cysts, although the big loculi may be destitute of epithelium, the

smaller cavities will retain their epithelium, which may be columnar, cubical, or stratified.

An extremely simple means of determining an oöphoronic tumour is to note the relation of the Fallopian tube; it lies curled up on the cyst, and when the parts are stretched the tube and tumour are separated by the mesosalpinx.

Adenoma.—This is not only an important but an extremely interesting tumour. As a rule, it has a dense fibrous capsule, and its surface is frequently lobulated. Such a tumour attains

Fig. 225.—Cyst of the Oöphoron. Natural size.
A, Incipient cyst; B, paroöphoron; F, Fallopian tube; P, parovarium.

great dimensions, and is composed of innumerable cysts, which vary in size from a cavity no bigger than a pea to one holding a litre or more of fluid. Critical dissections of such cysts enable us to recognise three varieties of loculi. In typical specimens a honeycomb-like mass will be found projecting into some of the larger cavities and occupying usually one-third of its circumference, so that a section of the cavity resembles a signet-ring—such are called primary, whilst the cavities occupying the honeycomb portion are secondary cysts, and are, as a matter of fact, mucus retention cysts. The third set of loculi are of small size, and histologically are indistinguishable from distended ovarian follicles (Fig. 226).

When ovarian adenomata of this character are quite fresh, if the smaller loculi be punctured with a knife and the fluid watched as it flows through the opening, a small opaque body, about the size of a rape-seed, will often be detected escaping. These bodies have been described as ova.

The primary cysts in their early stages are lined with

Fig. 226.—Portion of a large ovarian adenoma, showing the varieties of loculi. *c*, Primary ; *d*, secondary loculi.

rich columnar epithelium, and often contain mucous glands (Fig. 227). The fluid contained in the loculi of ovarian adenomata is identical in its physical and chemical characters with mucus. Occasionally it is as thick and tenacious as jelly. The tissue lining the cavities is in many specimens indistinguishable from mucous membrane.

The epithelium lining the loculi of ovarian adenomata sometimes attains extraordinary proportions. The largest

columnar cells I have ever seen occurred in these tumours, excelling those remarkable cells in the glandular spaces of rectal polypi occasionally found in children. The translucency of the cells is due to the mucus they contain. The source of these large cells is undoubtedly the epithelium lining the ovarian follicle. It is of great importance to appreciate the high development of the follicular epithelium, as its meta-

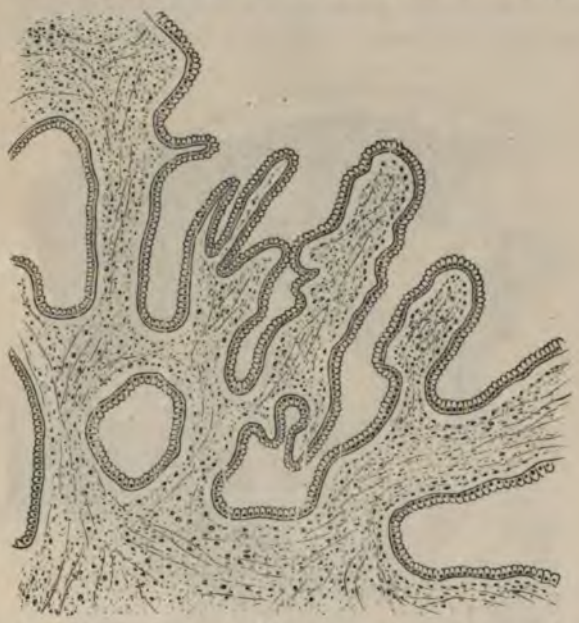

Fig. 227.—Section of the wall of a loculus from an ovarian adenoma, showing the glandular disposition of the epithelium.

morphosis has a very important bearing on the nature of ovarian dermoids.

In some specimens of ovarian adenomata the secondary loculi give rise to projections on the periphery of the tumour; when numerous and close together, these projections cause the tumour to resemble a colossal bunch of grapes. It is no uncommon thing for a loculus of an ovarian adenoma to burst into the belly. When this happens the mucus which escapes is tolerated, but not absorbed, by the peritoneum. When the rent in the loculus is not repaired the glands in its walls continue to secrete, and the mucus accumulates in the belly,

simulating hydroperitoneum. On one occasion I removed three gallons of inspissated mucus of this kind from a woman's belly which had been secreted by an ovarian adenoma no bigger than a cocoanut. The belly was so tightly stuffed with this jelly-like material that it had produced a hernial protrusion at the umbilicus and the left femoral ring, the sac in each case being crammed with thick mucus. The patient, who was fifty-four years of age, made an uneventful recovery.*

Malignancy of Ovarian Adenomata.—It is often very difficult

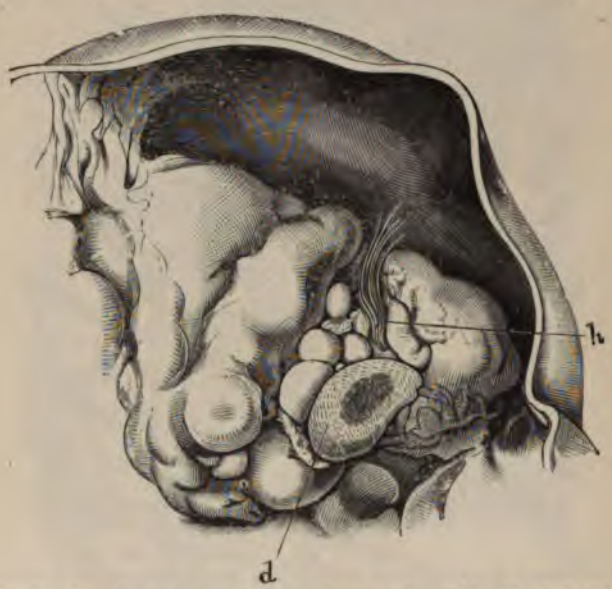

Fig. 228.—Ovarian adenoma, presenting a cutaneous clump (*d*) with a tuft of hair (*h*). (*Museum, St. Thomas's Hospital.*)

in the course of an operation to decide whether a tumour of the ovary is an adenoma or a carcinoma; for this reason I have for some years removed ovarian tumours of all kinds through a very long incision without tapping or breaking them. In some cases in which the cyst or a loculus of a multilocular cyst had burst into the peritoneum before operation and appeared thoroughly innocent, within a few months the patient has died with scattered masses of growth on the peritoneum.

* *Trans. Obstet. Soc.*, vol. xli. 98.

Many cases have been recorded in which the cicatrix in the belly wall after the removal of an ovarian adenoma "has

Fig. 229.—Ovarian dermoid. The lower part of the tumour contained teeth-germs in early stages of development. H, Tuft of hair.

become the seat of cancer." Unfortunately those who have recorded such cases have in nearly all instances failed to fortify their statements by descriptions of the histology of the so-called

cancer. The recurrence in the scar may be due to the implantation of epithelium at the time of operation.

Dermoids.—A very large proportion of oöphoronic cysts contain skin or mucous membrane, or both these structures, and some of the many organs peculiar to them, such as hair;

Fig. 230.—Composite drawing of the microscopic appearance of the dermoid sketched in Fig. 229. Showing an epithelial pearl in section; glandular tissue; developing hairs; a developing tooth; and sweat-glands.

sebaceous, mucous, and sweat glands; dermal bone, horn, nail, nipples and mammæ; teeth also occur in great numbers: such are called **dermoids.** They may be multilocular or unilocular, and attain a weight of 20 or even 40 kilogrammes. Sometimes a cyst will be lined throughout with typical mucous membrane covered with regular columnar epithelium, and will contain mucous glands.

The contents of a dermoid usually consist of a pultaceous mixture of shed epithelium, fat, and loose hair. In many complex multilocular dermoids some of the loculi contain mucous membrane and are filled with mucus; others possess hairs; and a few may be quite barren. There is in the museum of St. Thomas's Hospital a specimen, placed in the collection as a typical example of an ovarian adenoma (multilocular ovarian glandular cyst): sprouting from a cutaneous patch in one of the larger loculi is a tiny tuft of lanugo-like hair (Fig. 228).

It is impossible to determine in many cases, from a mere naked-eye examination, whether an oöphoronic tumour should be regarded as an adenoma or a dermoid. In practice the presence of a tuft of hair or a tooth is a useful and ready way of settling the question. Failing this, a careful microscopical examination is necessary. For instance, the tumour represented (nearly natural size) in Fig. 229 consists of two parts; one a thin-walled cyst (filled with sebaceous material when fresh) lined with piliferous skin. The lower and larger portion resembled, on superficial examination, an adenoma, and was nearly solid. A small tuft of lanugo-like hair, at the spot marked H in the drawing, induced me to make a careful histologic examination of the adjacent tissue. The sections revealed an extraordinary diversity of tissues and organs, such as sebaceous and sweat-glands, hair-germs, skin, teeth-germs with typical enamel-organs and dentine papillæ, epithelial pearls, and shapeless masses of epithelium (Fig. 230).

Shattock * has pointed out that skin is distinguished from mucous membrane by the presence of the stratum granulosum, or eleidin-holding layer, and offers this as a means for distinguishing between a skin-lined (dermoid) cyst and one lined with mucous membrane (mucosal cyst). This answers well for sequestration dermoids, but some of the most typical skin-lined ovarian dermoids have no stratum granulosum.

Cysts occur in the oöphoron at all periods of life, even in very young children, and I have collected records of over one hundred cases in girls under fifteen years of age in which ovariotomy was a necessity from the size of the tumour. In one

* *Trans. Path. Soc.*, vol. xlviii. 254.

remarkable case an ovarian tumour from a girl of fifteen years weighed 44 kilos; the girl weighed 27 kilos (Keen).

Small cysts in the oöphoron are very common at birth, and are often bilateral; but, so far as I am aware, after a careful and prolonged investigation of the matter, no authentic

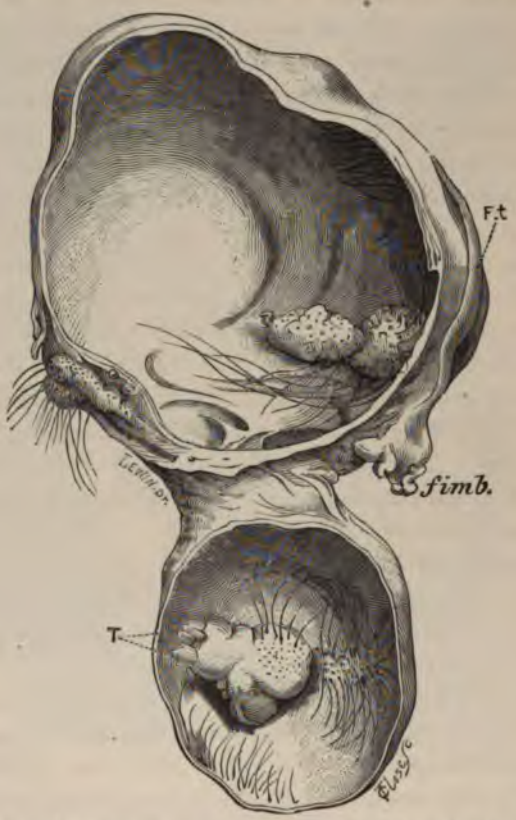

Fig. 231.—Ovary of a pregnant woman containing two independent dermoids. The opposite ovary was also converted into a dermoid. F.t, Fallopian tube; *fimb.*, fimbriæ; T, teeth.

example of an ovarian dermoid has been observed in a child before the end of the first year of life.

Adenomata and dermoids are very apt to affect both ovaries simultaneously; very rarely two independent dermoids may arise in one ovary (Fig. 231); and it is a fact that both ovaries may be so distorted and destroyed by dermoids that the true

ovarian tissue is unrecognisable to the naked eye; yet these organs are able not only to dominate menstruation, but to discharge their egg-bearing functions successfully.*

The Rate of Growth of Ovarian Adenomata and Dermoids.—Concerning the rate of growth of these tumours very little is known. Therefore the following observations may be of interest:—

1. *Ovarian Adenoma.*—In May, 1901, I removed from a woman forty-five years of age a typical left ovarian adenoma of the size of a football; it was full of the usual colloid stuff. The right ovary was very carefully examined and found to be

Fig. 232.—Enormous ovarian cyst in a girl seventeen years of age; it contained 78 litres of fluid. (*After Dayot.*)

normal. In February, 1903, I removed an ovarian adenoma of the size of a football which had originated in the right ovary.

Thus a complex glandular tumour of the size of a football may grow from an ovary apparently normal in twenty-one months.

2. *Ovarian Dermoid.*—The following case is recorded by Flaischlen:—In May, 1887, Ruge ovariotomised a woman, removing a cyst as large as a child's head which had arisen in the left ovary. The right ovary was inspected and found to be natural.

In June, 1888, a tumour the size of a fist was detected on the right side of the pelvis. In December, 1890, laparotomy

* Cullingworth, *St. Thomas's Hosp. Rep.*, vol. xvii. See also Thornton, *Trans. Obstet. Soc.*, vol. xxviii. 41; Page, *Lancet*, 1893, vol. ii. 250.

was again performed, and a dermoid, containing hair and teeth, removed.

In this case the evidence is decisive that *a dermoid may arise in the ovary and attain dangerous proportions in an adult woman within the space of three years.*

That a tumour containing hair and erupted teeth should be produced in the course of three years is not inconsistent with the rate at which these organs are formed under normal conditions. For instance, the period between the fertilisation of an ovum and the eruption of the milk incisors in man is about fifteen months; in exceptional instances children are born with incisors above the gum. In such cases the process occupies less than nine months.

CHAPTER XLVI.

OVARIAN DERMOIDS (*continued*).

THE cutaneous organs found in ovarian dermoids present such extraordinary variation as to demand separate consideration.

Skin.—This, in some specimens, is very thick, but it rarely possesses papillæ, and these when present are not furnished with touch corpuscles. Pigment is occasionally observed in the deep layer which would correspond to the rete mucosum. An epidermis may be demonstrated; sometimes it is very thick, and the superficial layers are shed into the cavity of the dermoid in broad flakes. The usual arrangement of the epithelium resembles that which is found on the buccal mucous membrane rather than on skin in general. The subcutaneous tissue of dermoids is often particularly rich in delicate fat.

In a few instances the epidermis has been found transformed into **nail**. An ill-formed nail has been detected at the extremity of a piece of bone resembling a phalanx by several observers.

Hair.—This varies in length, colour, and amount. A single tuft coiled into a ball and mixed with sebaceous matter is not unfrequent, and may attain a length of 50 cm. Mundé * has described and figured a specimen in which a tuft of hair in an ovarian dermoid was 1.5 metres long. Frequently only a few hairs are found scattered on the cyst wall, or the hair may be rolled into balls and lie free in the cyst. Occasionally the shed hair will "felt." The colour is equally capricious, and, as a rule, differs from that on the exterior of the individual. The hair in such cysts changes in colour with age, and in elderly persons becomes quite white and is eventually shed, so that these cysts become actually bald. In an ovarian dermoid from a mare † the hair resembled that on the animal's mane or tail. In a similar tumour from a ewe wool existed.

* *American Journal of Obstet.*, vol. xxiv. 854.

† *Trans. Obstet. Soc. Lond.*, vol. xxxi. 234 and 253

Sebaceous Glands.—The extraordinary abundance and large size of these glands is a conspicuous feature of typical ovarian dermoids. They are occasionally transformed into "wens," and, exceptionally, **horns** sprout from them.

Sweat Glands.—These are not nearly so common as the sebaceous variety, and usually occur in irregular isolated

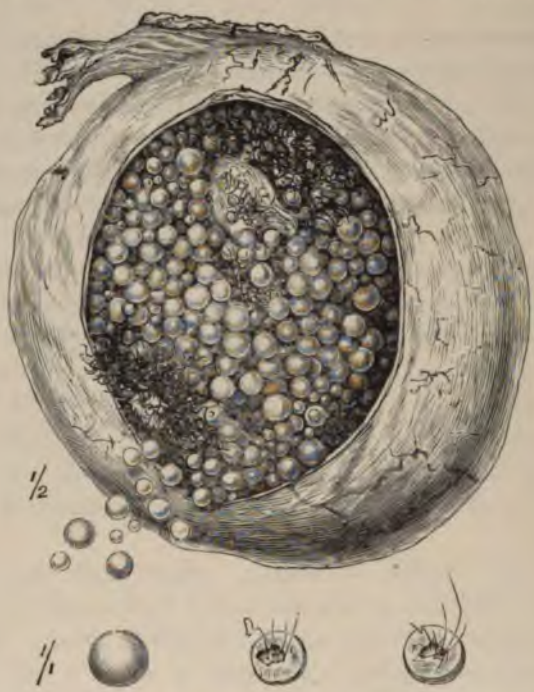

Fig. 233.—Ovarian dermoid containing 3,930 epithelial balls.

clusters. I have as yet failed to detect the characteristic twist of the duct so constant in normal sweat glands.

Pultaceous Material.—The cavities of ovarian dermoids are often filled with a semi-fluid mixture of epithelium, sebum, fat, shed hairs, and often cholesterine. In small cysts the sebum is sometimes so pure as to be quite white in colour.

The fat may be liquid at the temperature of the body, but solidifies after its removal. In some dermoids it occurs in lumps of the density and colour of cacao-butter. This variation probably depends on the proportion of stearine in the fat.

Epithelial Balls.—In some rare cases the shed epidermis forms rounded pill-like bodies which I ventured to call epithelial balls. As a rule, three, four, or even twenty, and perhaps fifty, may be present. In one remarkable specimen which I examined, the number amounted to 3,930. Each contained, as shown in Fig. 233, one or more hairs as a nucleus, around which the epithelial masses cohered to form balls. Dr. Bonney * has reported a similar case, collected the literature, and attempted to demonstrate by experiment the probable mode by which these balls are formed. These pill-like bodies have been found in dermoids of the scalp (see p. 353) and in a dermoid of the neck.†

Ovarian Mammæ.—It is not uncommon to find in the interior of an ovarian dermoid one or more tags of skin resembling a **nipple** associated with teeth and hair. Not unfrequently these nipple-like processes of skin are attached to more or less rounded projections of tissue, which recall in a striking manner the shrunken mammæ of a woman who has given suck to many children. The nipple-like processes of skin are imperforate, and beset with large sebaceous glands. In other cases the mammæ may be plump and well formed, but consist of fat covered with skin. Even in such a case no ducts or gland-tissue occupy the substance of the mass. The nipple may be surrounded by an areola. Such are called **pseudo-mammæ.**

Complete mammæ are sometimes found with glandular acini, ducts, and a perforated nipple. The specimen in Fig. 234 was an example of this, and furnished a viscid fluid which exhibited the microscopical characters of milk and contained colostrum globules. The glandular tissue was embedded in rich yellow fat.

Shattock ‡ described a mammiferous dermoid in which the mamma possessed an imperforate nipple, but a cyst filled with colostrum occupied its base.

The most complete ovarian mamma from a histological point of view is one described by Velits §: the nipple was surrounded by a rosy areola with clusters of Montgomery's

* *Trans. Obstet. Soc.*, vol. xliv. 354.
† Rolleston, *Trans. Path. Soc.*, vol. xlix. 292.
‡ *Trans. Path. Soc.*, vol. xxxix. 442.
§ Virchow's *Arch.*, bd. cvii. s. 505.

tubercles and small tufts of blond hair. Its structure was characteristic of a mamma (Fig. 235).

Thyroid Gland.—In 1893 I removed a large dermoid from a woman fifty years of age, and detected in it a firm,

Fig. 234.—Mammiferous dermoid. The gland has two tube-like nipples, one of which has been divided. (*Half the natural size.*)

rounded, encapsuled body as big as a walnut. Its cut surface so resembled a thyroid gland that I examined it microscopically. The body was composed of closed vesicles filled with colloid material and lined with the sub-columnar epithelium so characteristic of the normal thyroid gland. Kroemer * detected a thyroid gland as big as a pea in an ovarian dermoid.

* *Arch. für Gyn.*, bd. lvii., 1898.

Teeth.—A large proportion of ovarian dermoids contain teeth. In number they vary considerably; sometimes two or three are found, in others twenty, and as many as 400 have been counted. It is unusual to find more than twelve teeth in a cyst. They may be embedded in loose, ill-formed bone, or project from a flat bony plate like nails driven through a piece of thin wood.

Teeth are not scattered irregularly through the tumour unless present in very great number, but are collected in one or

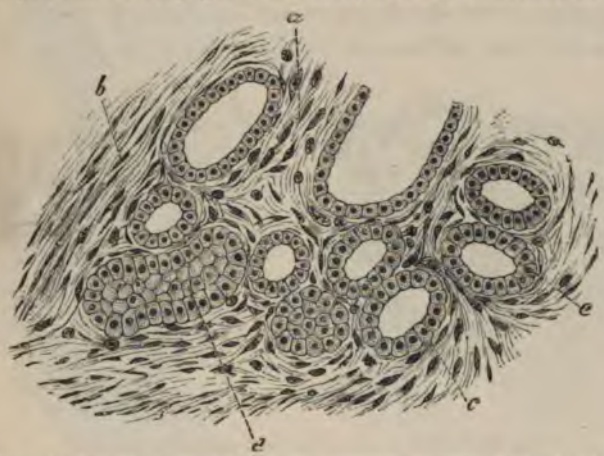

Fig. 235.—Histologic characters of the ovarian mamma described by Velits. *a*, Pigmented connective tissue; *b*, plain muscle fibre; *c*, *d*, and *e*, gland-acini and ducts.

more groups. They vary in shape, and resemble incisors, canines, and supernumerary teeth (Fig. 236).

In the majority of cases the root is single; when the crown is simple the root is long; multicuspidate teeth have short roots. Ovarian teeth with more than one root are rare.

Sometimes the roots are embedded in soft tissue; often the teeth remain hidden in crypts or complete cysts. When the crown projects boldly it may be surrounded with pink tissue resembling the gums.

Ovarian teeth are composed of enamel and dentine; cementum is by no means constant. The enamel is lodged on the crown in lumps or hummocks, with deep ravines extending to the dentine. The enamel prisms run in all directions. The pulp is very irregular; some of the teeth, especially those

resembling incisors and canines, may lack a central chamber. In multicuspidate teeth the pulp chamber is of fair size. In some the pulp is converted into osteo-dentine (Fig. 237); in others it is full of fat globules. The presence of nerves in the pulps of ovarian teeth was asserted by Salter, and tissue resembling nerve-fibrils may be detected in pulp suitably prepared. Ovarian teeth develop on the same principle as normal teeth (Figs. 230 and 238).

For several years I made a series of observations in order to determine if the development and eruption of ovarian teeth were in any way influenced by age, and to ascertain if, like

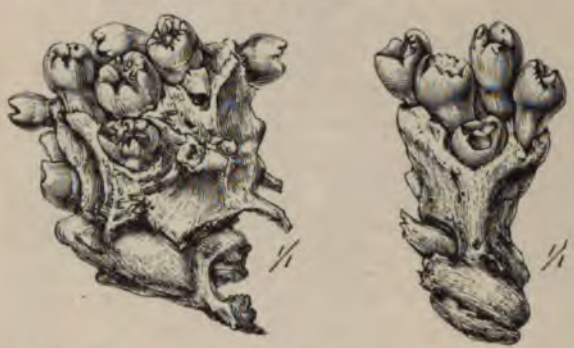

Fig. 236.—Cluster of ovarian teeth embedded in bone.

the hair of dermoids, they were shed in old age. The evidence proved that the development of ovarian teeth is uninfluenced by age; for example, a dermoid the size of a tennis ball, from a girl six years of age, contained many teeth, six of which were fully erupted, whereas an ovarian dermoid from a woman in middle life contained germs of teeth in great abundance, but none had reached the stage of calcification.

Teeth occur more frequently in ovarian dermoids than would be gathered from the current descriptions. Unless the teeth are actually erupted the surgeon may fail to notice them unless he makes, or orders to be made, a careful dissection of the dermoid. On several occasions I have astonished my assistants by directing a dermoid in which no dental structures were obvious to be destroyed by prolonged boiling: when the residue was examined many (sometimes twenty or thirty) teeth were found.

Epithelial Pearls.—The common form of epithelial pearl consists of concentric laminæ of horny epithelium. The central portions in some specimens are structureless and transparent like horn; in others the cells are large and distinct. Some-

Fig. 237.—Microscopic characters of a multicuspidate and bicuspidate ovarian tooth.
In A the pulp chamber contains osteo-dentine; in B the pulp chamber is exceedingly small, and occupied with osteo-dentine; cementum is absent from the roots.

Fig. 238.—Germ of an ovarian tooth. E, Enamel organ; P, papilla.

times the epithelium forms onion-like layers without any tendency to cornification.

The common mode by which pearls are formed is by the retention and subsequent moulding of shed epithelium in the recesses of sebaceous glands, in mucous crypts, or in the folds of epithelial surfaces. Some are probably formed on the principle of enamel organs.

Bone.—This tissue is often present in ovarian dermoids in shapeless masses resembling the alveoli of jaws, or as irregular plates of extremely dense bone, "similar to the facial bones of an osseous fish" (Doran). In these ill-formed pieces of bone those writers who believed that dermoids were due to parthenogenesis saw jaws, skulls, pelves, limbs, etc., and other skeletal elements, as their fancies led them. Rarely the fibrous capsule of a dermoid becomes calcified in flakes until a hard shell is formed (Fig. 239).

Fig. 239.—Ovarian dermoid containing hair and teeth. (*Museum, Middlesex Hospital.*) The fibrous capsule has calcified.

Nerve-tissue.—Our knowledge in relation to nerve tissue in ovarian dermoids is not very satisfactory. Several observers have detected the presence of tissue which in its histological characters was indistinguishable from "cerebral matter." * In several cases the brain substance was enclosed in a firm capsule in structure like dura mater lined with a delicate pia mater.† A similar example has come under my own notice.

The whole question of nerve-tissue in dermoids requires careful study, aided by the improved methods of staining now employed in neurological histology.

* Gray, *Med.-Chir. Trans.*, vol. xxxvi. 434.
† Neumann, Virchow's *Arch.*, bd. civ. 462.

NATURE OF THE OVARIAN FOLLICLE AND MUTABILITY OF SKIN AND MUCOUS MEMBRANE.

Oöphoronic cysts of the three varieties discussed in the first part of this chapter arise in ovarian follicles. The remainder of this chapter will be devoted to the consideration of the nature of the ovarian follicle and to the relationship of skin and mucous membrane ; it will also be necessary to discuss, though not at great length, the mutability of epithelium.

The Nature of the Ovarian Follicle.—The phylogeny of the ovarian follicle is intimately bound up with the history of the peritoneum. The pleuro-peritoneal cavity in most vertebrates arises as a schizocœle, due to the splitting of the lateral walls of the embryo into splanchno-pleure and somato-pleure. This mode of origin is secondary, for in simpler forms the cœlom (pleuro-peritoneal cavity) is derived from abstrictions of the archenteron. Thus the cœlom is a derivative of the primitive gut, and its surface is covered with epithelium. The cells of the genital ridge, which form ova and line the follicles, are of the same nature as those which give rise to mucous glands in the intestine. Morphologically, an ovarian follicle is a modified mucous gland.

Mutability of Skin and Mucous Membrane.—Skin covers the exterior of the body, and possesses in addition to the horny layer a rete mucosum containing pigment. In many animals it furnishes protective structures such as scales, horns, scutes, quills, bristles, feathers, hair, etc., all of which are modifications of the epidermis, or its papillary processes. Glands derived from the surface epithelium may furnish mucus, poisonous fluids, and milk. Subject as skin is to external modifying influences (environment), we need not express surprise at the variety of structure and modification exhibited by it. Mucous membrane in its most typical form exists in the intestine. It has a single layer of columnar epithelium, which may be ciliated (amphioxus, petromyzon, ammocœtes). The epithelium dips into the underlying tissue to form mucous glands.

Instead of intestinal mucous membrane, let us select a piece from the buccal cavity. Here we find it lined with layers of flattened epithelium surmounting papillæ ; some of these

papillæ are calcified and form teeth. Many rodents have hairy patches on the buccal aspect of the cheek. In dogs the mucous membrane of the mouth contains pigment; this is occasionally the case with the lingual mucous membrane in man; and the vagina sometimes contains tracts of blue pigment in monkeys. Sebaceous glands are not peculiar to skin; they are large and numerous in the mucous membrane of the nymphæ, and occasionally in the lips. Mucous glands occur in the skin of batrachians, worms, and as slime glands in fish.

In snails, oysters, mussels, etc., the mantle secretes a shell; in reptiles, and such specialised vertebrates as birds, the glands in the mucous membrane of the oviduct perform a similar function; calcareous formations resembling shells are constantly formed by the glands in the prostate of man.

A single layer of epithelium avails little in the argument, for worms have a single layer of columnar epithelium to their skin. Amphioxus is similarly provided in the gastrula stage, the cells being ciliated. It has been urged that the lining membrane of the mouth is practically skin, inasmuch as it is derived from the epiblast, and it has been said that, to render the argument valid, hair should be found on the mucous membrane lining the stomach or intestine. Such is, in fact, the case in the remarkable bird the Darter (*Plotus anhinga*); its pyloric orifice is guarded by a tuft of hair.*

It is well to bear in mind that skin in at least one situation —the conjunctiva—has become modified into mucous membrane and not rarely reverts to its original form (p. 390).

It used to be taught that epithelium was very stable, but we know that the columnar variety is very mutable. When exposed to external influences and pressure it quickly stratifies. Examples have been mentioned (p. 172). The columnar cells of the intestine become stratified at the margin of a colotomy wound, or on the exposed surface of a pile, and the change from columnar to stratified epithelium occurs normally on the dorsal wall of the cat's trachea, in consequence of the overriding of the extremities of cartilaginous semi-rings under the influence of the trachealis muscle.†

* "The Collected Works of Garrod," p. 334.

† Haycraft and Carlier, *Quart. Jour. Micros. Sci.*, vol. xxx. 519, 1890.

CHAPTER XLVII.

THE AXIAL ROTATION OF OVARIAN TUMOURS: EPITHELIAL INFECTION AND SUPPURATION OF OVARIAN CYSTS.

In 1860 Rokitansky drew attention to the fact that ovarian and uterine tumours sometimes rotate and twist their pedicles, or drag upon them in such a manner as to compress the vessels traversing the pedicles, and so interfere with the proper nutrition of the tumour. Occasionally the torsion, and, in some, the torsion and tension on the pedicle, led to complete detachment of the tumour. He also drew attention to the fact that certain abdominal viscera are apt to undergo axial rotation. Of recent years much attention has been devoted to this subject, and accumulated observations have served to show that almost every variety of abdominal tumour and all the viscera, except the liver, have been found liable to this accident.

That a tumour hanging freely in the belly should, by mere alteration of the position of the body, or by motion imparted to it by a tumult of the bowels, spin round and twist its pedicle is as comprehensible as the fact that a good weathercock moves in varying directions under the influence of the wind. It is, however, puzzling to find the spleen, distended Fallopian tubes, undescended testes, the pregnant uterus, the kidneys, the cæcum, and the stomach liable to similar rotation.

Ovarian tumours of all kinds are very liable to axial rotation. Concerning its cause, very little is known. Various explanations have been advanced. It has been attributed to the alternate distension and evacuation of the bladder (Klob), or to the passage of fæces through the rectum (Lawson Tait); to sudden movements, such as a fall, slip, or unusual exertion (Thornton). An important fact to remember is the frequency with which this accident occurs when ovarian cysts complicate pregnancy, and especially when an ovarian cyst complicates a myomatous uterus large enough to fill the pelvis.

When both ovaries are converted into cysts the risk of twisting is nearly the same as when pregnancy and an ovarian cyst are associated. When both ovaries are cystic and

pregnancy ensues the risk of axial rotation is more than doubled. The torsion may occur early in pregnancy or be delayed till delivery or miscarriage. In one instance at least, in a case of bilateral ovarian dermoids, both tumours had twisted their pedicles (Doran).

The occurrence of acute torsion immediately after delivery is due to the rapid diminution in the size of the uterus and to the movement which this organ, as it sinks into the pelvis, imparts to the tumour.

Rotation of a cyst in the early stages of pregnancy is probably due to the gradual enlargement of the uterus displacing the tumour upwards; and as the pressure is exerted upon one side of the cyst, it would be in a favourable position to impart a rotatory motion to a non-adherent cyst. The *amount* of rotation varies greatly. In some cases the cyst has only turned through half a circle; in others as many as twelve complete twists have been counted. The direction of the rotation may be from right to left, or *vice versâ*, but cysts exhibit a strong tendency to rotate towards the middle line rather than from it. Tumours of the right and left side are equally liable to rotate. Small tumours rotate more freely than large ones, and a long and slender pedicle favours its occurrence. The force with which some of the large cysts rotate is very great, for in some instances the uterus is involved in the twist.

The *effect* of torsion on the circulation depends on the tightness of the twist, and this varies with the thickness of the pedicle. The vessels in a long thin pedicle would suffer obstruction quicker than those in a short and thick one. When a pedicle is torsioned the thin-walled veins become compressed, whilst the more resilient arteries continue to convey blood to the cyst. The result is severe venous engorgement, and this leads to extravasation of blood into the cyst wall; in many cases the veins rupture, and hæmorrhage takes place into the cavity of the cyst. The hæmorrhage may be so profuse as to cause profound anæmia, and even death.

When the venous circulation is completely arrested in consequence of torsion, the appearance of the cyst is very striking and characteristic. On opening the abdomen during life, instead of the cyst presenting the familiar white glistening

appearance, it has a deep, dark, lustreless hue, which is most intense near its attachment to the pedicle. In milder degrees of torsion the change in colour only affects the base of the tumour. The pedicle on the distal side of the twist presents the same dark hue, but on the uterine side it is, as a rule, of natural tint. The contrast of colour in the two parts of the pedicle is very striking. The walls of the cyst are thick and succulent; the blood contained in the cavity, or in the loculi if multilocular, may be of a chocolate or of a dark-red colour.

When such a cyst is removed from the body and the blood allowed to drain away, or is washed away by a gentle stream of water, the tissues will resume their natural colour. This should be remembered, because some writers have attributed this dark colour to gangrene of the cyst. This is erroneous; gangrene of an ovarian cyst is a rare event, and can only take place when air is admitted from without, as during the operation of tapping, or when intestinal fluids obtain access to it.

The usual effects of acute torsion of the pedicle are passive congestion, thrombosis, extravasation of blood into the tissues of the tumour, and necrosis.

Necrosis is localised death, in contrast to death of the organism as a whole, or "somatic death."

Moist gangrene is necrosis followed by decomposition and putrefaction of the dead tissues. When soft parts necrose in situations where they are accessible to putrefactive organisms, such as the exterior of the body, the lungs, or the intestinal tract, decomposition rapidly ensues, especially if the parts contain much blood. In the case of ovarian tumours with twisted pedicles, not in communication with the outer air directly or indirectly, micro-organisms can rarely gain access to them and cause decomposition.

It is therefore erroneous to describe as gangrene the changes observed in cysts with torsioned pedicles. This is further illustrated by the circumstance that small ovarian tumours may be completely twisted from their pedicles and subsequently shrink. Were the changes in the cyst gangrenous in character, general infection of the peritoneum and death would be the inevitable consequences.

Burdon Sanderson, in his article on the Pathology of

Inflammation,* refers to the peculiar plan of emasculating animals known as **bistournage.** In this method no instrument is used; the testicle is freed from its association with the dartos, then twisted on the spermatic cord as on an axis four or five times, the whole manipulation being performed with prodigious rapidity. If the animal is killed afterwards and the arteries injected, it is found that no blood enters the spermatic artery beyond the twisted part of the cord. Consequently, while the surrounding parts receive their natural supply of blood from the pudic artery and preserve their vitality, the testicle itself is irretrievably condemned to death. We have in the above method practically a crucial experiment, which demonstrates that when a testicle is deprived of blood in consequence of axial rotation it necroses and finally atrophies.

A perusal of the records of cases described as gangrenous cysts indicates that the reporters have regarded the deep livid hue of such cysts as evidence of gangrene, and that others have confounded suppurating with gangrenous cysts.

Rotation of an ovarian cyst when it gives rise to such severe changes as have just been considered may be described as **acute torsion.** It frequently happens that during the performance of ovariotomy a thick pedicle is found twisted through half or even a complete circle, without producing an appreciable effect upon the tumour. In others, torsion takes place so gradually, yet so completely, that the pedicle is twisted like a rope, and not unfrequently the pedicle breaks and the tumour becomes detached from its uterine connections. To this variety the term **slow** or **chronic torsion** may be applied. Its effects are not less interesting than those which follow acute twisting. When rotation occurs slowly, the walls of the cyst inflame and adhesions are established between the cyst and the omentum, or the parietal peritoneum; such adhesions become vascular and maintain the vitality of the cyst wall after circulation is arrested through the pedicle. Cysts have been observed in all stages of transplantation.

Acute torsion is more frequent in tumours of median size; it also occurs in small cysts; but it is the small tumours, especially dermoids, in which slow torsion takes place.

* Holmes and Hulke's "System of Surgery," vol. i. 84.

The symptoms of acute torsion of an ovarian cyst are often so characteristic as to lead to a correct diagnosis. When a woman complains of sudden and violent pain in the abdomen, accompanied with vomiting, and she is known to have an ovarian tumour, or she presents herself for the first time to the surgeon, and these signs are associated with an abdominal swelling the physical signs of which are indicative of an ovarian tumour, axial rotation should be suspected. Should the patient possess a gravid uterus as well as an ovarian cyst, it is even more probable that rotation has occurred; or if she has an ovarian tumour and has been recently delivered, this is an additional reason for suspecting that the symptoms arise from a twisted pedicle.

Clinical observations demonstrate that the predominant signs of acute axial rotation of abdominal tumours and viscera are those common to a strangulated hernia minus stercoraceous vomiting.

Even the presence of fæcal vomiting does not always negative the existence of acute axial rotation of an ovarian tumour, for a loop of bowel may be involved in the twist and produce intestinal obstruction.

Otto von Franque * has observed an ovarian cyst, the size of a dove's egg, in a new-born child with a tightly twisted pedicle.

Epithelial Infection.—This is an important phenomenon, which reaches its highest manifestation in connection with ovarian dermoids. It is a matter of great interest, because it completely disposes of the view that dermoids may exhibit malignant characters and give rise to secondary deposits.

In 1866 Moore † described the following remarkable case:—A married woman, twenty-eight years of age, had suffered from an abdominal tumour for ten years. It suppurated, and the pus escaped through a fistulous opening at the umbilicus. She died a few days after her admission into the Middlesex Hospital. At the *post-mortem* examination a huge ovarian dermoid, universally adherent, was found, containing large quantities of hair and a great number of teeth.

* *Zeitsch. f. Geb.*, xliii. 257.

† *Trans. Path. Soc. Lond.*, vol. xviii. 190.

"Among the peritoneal adhesions were many small cysts, some of which were attached by slender pedicles to the main cyst; whilst others were entirely unconnected with it, but, like it, contained soft, cheesy, yellow epithelium mixed with hairs. One was in the great omentum. Two, which were in, or near, the right broad ligament, and of the sizes of a nutmeg and a walnut, had ossified or chalky walls. Many small ones were in situations where they might have been supposed to be diseased absorbent glands, as in the pelvis or mesentery. . . . The largest of the loose cysts lay among the adhesions of the small intestines. It was completely separated by the bowels from the principal cyst, and it was rather larger and longer than a hen's egg."

Kolaczek * reported a case in which Martini removed from a single woman, forty years of age, an ordinary ovarian dermoid as large as a man's head. Its surface was perfectly smooth. After the escape of some free fluid the peritoneum was seen to be dotted with small yellow knots; many of them were furnished with a small tuft of light hair 1 cm. in length, which projected into the peritoneal cavity (cœlom).

In 1883 Fraenkel † published a case which throws quite a new light on these conditions:—

A woman, thirty-five years of age, with a tumour in her belly, fell from a vehicle; the tumble caused enlargement of the tumour and peritonitis. Nine months later she submitted to operation. The belly contained dirty fluid mixed with hairs, which had escaped from a ruptured dermoid in the left ovary. The peritoneum was beset with small dermoids hanging by long thin pedicles. Somewhat larger ones were found in the neighbourhood of the liver, diaphragm, and mesocolon; isolated hairs were found implanted on the omentum and sprouting into the cœlom.

Grawitz ‡ has recorded a similar observation. A woman, forty years of age, had a dermoid in each ovary; the abdominal viccera were universally adherent, and secondary dermoids existed among the adhesions; some were so small as to be barely

* Virchow's *Arch.* bd. lxxv. 399.

† *Wien. Med. Wochenschr.*, 1883, 865.

‡ Virchow's *Arch.* bd. c. 262.

visible to the eye, others were of the size of eggs. Similar dermoids were detected between the liver and the diaphragm.

An impartial consideration of these cases, supported by the evidence of accidental implantation of conjunctival epithelium and eyelashes in the anterior chamber of the eye, which have been actually observed to grow and form cysts, indicates clearly enough that peritoneal infection in the cases detailed above results from the diffusion of the epithelial

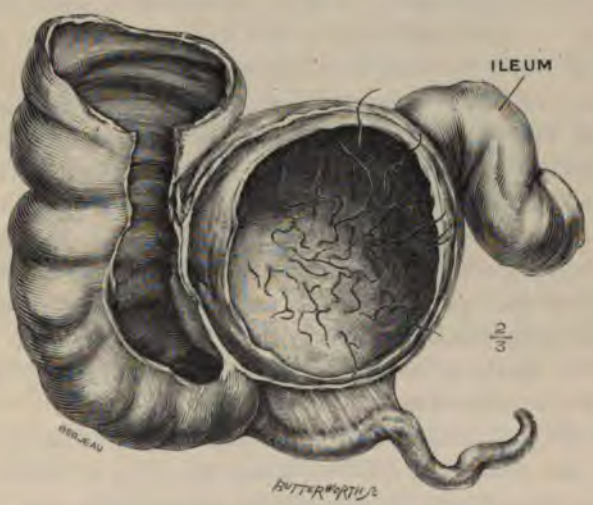

Fig. 240.—Cæcum and adjacent portion of the ileum of a man: a dermoid occupies the angle between the ileum and the cæcum. (The specimen is in the possession of Mr. A. Hall, Sheffield.)

elements of ovarian dermoids over the peritoneum in consequence of rupture.

In the former editions of this work it was stated that dermoids had, in women, never been found growing primarily from any abdominal viscus save the ovary. Mr. Arthur Hall has found one connected with the cæcum (Fig. 240). The position of the tumour is remarkable, for it lies in the angle formed by the junction of the ileum and the cæcum, and, as is well shown in the drawing, it lies between the layers of the peritoneal fold, extending from the termination of the ileum to the mesentery of the vermiform appendix. It contained the usual pultaceous matter and hairs. On microscopic examination a

lining of stratified epithelium was detected, but no stratum granulosum.

Morphology fails to assist us in speculating on its mode of origin. I have critically examined several hundred dermoids from human beings, and from all the recognised situations; I have hunted records in many languages for facts regarding dermoids; but I have never seen nor read a description of anything similar.

Suppuration in Ovarian Dermoids.—When air or intestinal fluids gain access to these tumours, then septic infection with all its attendant evils is the result, and unless the pus finds an outlet the individual dies. The pus in a suppurating dermoid sometimes bursts into the bowel, bladder, vagina, or through the abdominal wall at or near the umbilicus. When the cyst communicates with the bladder it will sometimes entail very great misery, because fragments of bone, teeth, locks of hair, and sloughs become impacted in the urethra. Cystitis is an almost constant accompaniment. Ovarian teeth in the bladder have formed the nuclei of phosphatic calculi.

Hair from ovarian dermoids entering the bladder is voided with the urine, a condition of things described by French surgeons as *pilimiction*.

In the preceding chapter each constituent of ovarian dermoids was considered in some detail, and it is a circumstance of great importance for the student to recognise that all the curious structures found in them are products peculiar to skin or mucous membrane. Organs such as liver, kidney, and intestine; or limbs and bones of definite shape, such as the femur, humerus, vertebræ, or skull bones, are never found. This fact serves sharply to distinguish dermoids from teratomata, which are derived from suppressed embryos.

Confusion has occasionally been introduced when a careless observer has mistaken a lithopædion, the result of a tubal pregnancy, for a dermoid. On the other hand, ovarian dermoids have been mistaken for the products of what used to be vaguely called "extra-uterine gestation."

CHAPTER XLVIII.

TERATOMATA.

A TERATOMA is an irregular conglomerate mass containing the tissues and fragments of viscera belonging to a suppressed fœtus attached to an otherwise normal individual.

It is a significant fact that teratomata are exclusively found in connection with the vertebral column and skull.

Strictly, the consideration of teratomata belongs to that department of pathology known as Teratology; but as certain species are so apt to be confounded with dermoids, it is necessary to give an account of them here.

In order to appreciate the nature of these singular malformations it will be necessary to consider the subject of conjoined twins, supernumerary limbs, and acardiac fœtuses. In the animal and vegetable kingdom it occasionally happens that a single ovum gives origin to two embryos, which may be quite separate from each other (twins) or they may be united, a condition known as **conjoined twins** (Fig. 241).

When two embryos are conjoined, and one goes on to complete development, whilst only certain parts of its companion continue to grow, the result is a **parasitic fœtus.** The mature individual supporting it is called the **autosite.**

In other examples the suppressed fœtus consists of an irregular-shaped tumour growing, perhaps, from the posterior surface of the sacrum, or within the abdomen or thorax, which on dissection contains a few vertebræ, or processes of skin resembling digits, associated with a piece of intestine or an imperfect liver. This is a **teratoma.**

In order to demonstrate the relation between parasitic fœtuses and teratomata, it will be useful to refer to dichotomy. In animals and vegetables there is a strong tendency for parts ending in free extremities to bifurcate or dichotomise. When this affects digits the result is supernumerary fingers and toes. Should it extend to the axis of the limb, supernumerary legs,

wings, or fins are produced. Dichotomy is not confined to the limbs, but affects also the axis of the trunk. When the whole embryonic axis dichotomises, twins are produced. Should cleavage be partial, and affect the caudal end of the trunk, it

Fig. 241.—The conjoined twin sisters Radica and Doodica at the age of 3½ years; born in 1889 at Noapara, a village in the province of Orissa, India. In 1899 they were re-exhibited in London in excellent health. Doodica died in 1902 (see p. 430).

is spoken of as posterior dichotomy. When it involves the anterior end it is called anterior dichotomy. With complete dichotomy, in which both embryos go on to full development, either as separate or conjoined twins, we are not further concerned, and the conditions arising from the imperfect growth of one embryo whilst its companion continues to develop must

be deferred until we have discussed the results of partial dichotomy.

Posterior Dichotomy.—When cleavage involves the caudal section of the trunk axis to any serious extent it necessarily follows that the pelvis as well as the vertebral column will be reduplicated; it is also obvious that the reduplication of the pelvis involves a corresponding increase in the number of the pelvic organs, including the limbs. Thus it follows that supernumerary hind limbs may arise from dichotomy affecting the

Fig. 242.—Posterior view of J. B. dos Santos at the age of 6 months. (*After Acton.*)

embryonic limb, or from cleavage of the caudal end of the trunk. The two modes also hold good for reduplication of the fore-limbs. The limbs may project from the ventral aspect of the pelvis, or be, as it were, dislocated on to the dorsal surface. Occasionally they occupy a position midway between these two extremes and lie more or less parallel with the normal hind limbs.

In some individuals one pair of supernumerary limbs fuse throughout their length (Fig. 242), and in others one limb is suppressed (Fig. 243), but it is a noteworthy fact in its bearing on the cleavage theory that in all specimens of supernumerary limbs due to posterior cleavage there is an accessory but usually

imperforate anus. In the well-known case of Jean Battiste dos Santos of Portugal, well described in 1846 by W. Acton,* and nineteen years later by Ernest Hart † in London, and by Handyside ‡ in Edinburgh, there was not only an additional (imperforate) anus, but the man had two functional penes. It is also an interesting fact that malformed individuals of this kind, whether male or female, are capable of producing healthy, well-formed offspring, the most striking example being the Siamese twins, Chang and Eng Bunker. They married sisters. Chang had ten children, Eng twelve. One boy and one girl

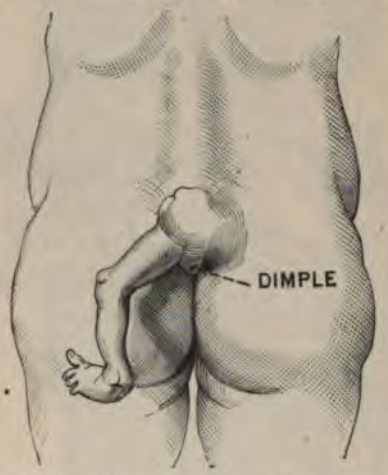

Fig. 243.—Sacral teratoma with a supernumerary leg.

of Chang's were deaf and dumb, but there was no other blemish of any kind in the families of the twins.§

Reduplication of the pelvic limbs and anus occurs frequently in sheep, calves, and birds.

When the parasitic fœtus is so suppressed as to form only a shapeless or deformed lump, such as would be the case in Fig. 243 if the limb were absent, then the mass would be called a teratoma.

It is a fact that the autosite has no power of initiating independent movements in the limbs of the parasite, nevertheless

* *Med.-Chir. Trans.*, vol. xxix. 103.
† *Lancet*, 1865, vol. ii. 124.
‡ *Ed. Med. and Surg. Journal*, 1866, vol. xi. part ii. 833.
§ *Brit. Med. Jour.*, 1902, vol. i. 465.

he can localise the prick of a pin on the parasite and feel uncomfortable when it is cold. Further, in the parasite represented in Fig. 246, micturition used to occur independently and without the knowledge of the autosite until he felt urine trickling over him.

Anterior Dichotomy. — Cleavage may affect the facial portion only and produce reduplication of the jaws, or it may

Fig. 244.—Anterior dichotomy.
(*From a photograph supplied by Dr. William Budd, of Bristol, July 20th*, 1856, *to Sir James Paget.*)

involve the head and produce a two-headed individual. Should it extend to the thoracic region of the spine, then an animal with two heads and reduplicated fore-limbs is the result. When partial dichotomy attacks the head the median parts of the reduplicated face are so conjoined and malformed that they are sometimes found hanging in the pharynx, being attached to its roof by a pedicle. Such tumours are called **basicranial teratomata**: the majority of tumours called pharyngeal dermoids are of this nature.

Among remarkable instances of anterior dichotomy, Ritta-Christina * and the blended Tocci brothers † have been carefully described. This form of dichotomy has been studied in fish, tortoise, calves, birds, and snakes.

The details of the remarkable child represented in Fig. 244 were supplied to Sir James Paget by Dr. William Budd, of Bristol, in 1856. With the exception of the extraordinary excrescence, he writes, "the child presents no deviation from the normal type, but is as comely a little thing as you would wish to see. Every movement and every act of the natural face is simultaneously repeated in the second face in the most

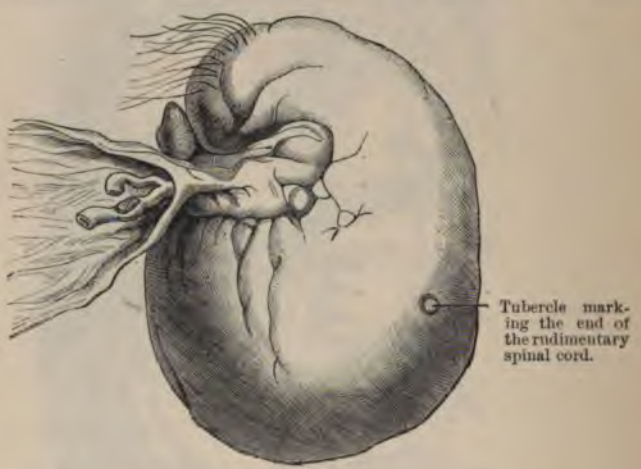

Fig. 245.—Acardiac fœtus.

perfectly consensual manner. When the natural face sucks the second mouth sucks." Crying and yawning occurred at the same time in the two faces.

I have ventured to publish this case because, so far as my knowledge of teratology extends, no similar case in the human subject is known. The fact "that every movement and every act of the natural face is simultaneously repeated in the second face in the most perfectly consensual manner" is quite in accord with what has been observed in calves the subject of "partial anterior dichotomy."

* Isidore Geoffroy Saint-Hilaire, "L'Anomalies de l'Organisation," t. iii. 119.
† Harris, *Amer. Journal of Obstet.*, vol. xxv. 460.

Thus far we have been concerned with reduplicated parts that reach such a standard of development that their identification is a matter neither of difficulty nor of doubt. It will now be necessary to consider the meaning of those attached parts named parasitic fœtuses and the irregular masses called teratomata.

Fig. 246.—Laloo, a Hindoo, with an acardiac parasite attached to his thorax.

It happens, and not unfrequently, that in cases of twins one of them is of natural shape and viable, but the other is very imperfectly developed, and as it lacks a heart (or if this organ be present it is rudimentary and functionless) is said to be **acardiac**. The degree of development varies greatly: in some the fœtus may be complete save head and neck. In rarer cases the fœtus may be merely represented by an irregular-shaped mass consisting of œdematous integument surrounding

a portion of the skeleton, usually an innominate bone with some of the bony elements of a lower limb.

In some specimens no particular skeletal element is recognisable, but a portion of intestine or rudiments of the genito-urinary organs can be detected. To such examples of acardiacus the adjective **amorphous** is applied, and to French teratologists they are known as "anidian monsters." An acardiac such as Fig. 245 has been described as a dermoid of the umbilical cord.* In very exceptional cases the acardiac may be so thoroughly amorphous that it is impossible to decide its nature until it has been submitted to a microscopic examination.†

Acardiacs are not necessarily separate from the well-developed twin, but may be attached to it in a variety of ways.

In the common form the shapeless mass is connected with the dorsal aspect of the sacrum, and simulates a spina bifida sac, or the form of congenital sacro-coccygeal tumour which arises in the post-anal gut. These sacral teratomata often move when irritated, and this is a valuable diagnostic sign. In rarer cases teratomata have been observed in the thoracic and abdominal cavities connected with the vertebral column. They are also met with in the head, particularly in relation with the jaws.

The explanation of acardiac fœtuses, whether free or parasitic, seems to be this :—Two embryos arise from a single ovum ; in some instances the cleavage is complete, but the heart of one embryo is defective. The circulation of the two embryos is continuous at the placenta, and the heart of the normal embryo is able to maintain in a measure the blood-current in its companion, and thus save it from complete suppression. Sir Astley Cooper ‡ demonstrated this compensatory mechanism in the case of an acardiacus placed in his hands by Dr. Hodgkin. An inspection of the drawing of the placenta from this case (Fig. 247) shows that the umbilical vessels in the two sections of the compound placenta were directly continuous.

In the case of a parasitic acardiac—*e.g.* Laloo—the circula-

* Budin, *Progrès Médical*, Dec. 31, 1887.

† Lea, *Trans. Obstet. Soc.*, vol. xli. 219.

‡ *Guy's Hospital Reports*, vol. i. 218, 1836. See also Keith, *Trans. Obstet. Soc.*, vol. xlii. 99.

tion must be directly maintained by the heart of the autosite, as an independent heart has not, so far as I am aware, been detected in the parasite. The blood current is always extremely slow in the acardiac, and thermometric observations demonstrate that its temperature is several degrees lower than that of the autosite.

Thus a study of the circumstances surrounding the development of twins and duplex monsters brings us to the conclusion that teratomata may arise either from partial dichotomy of

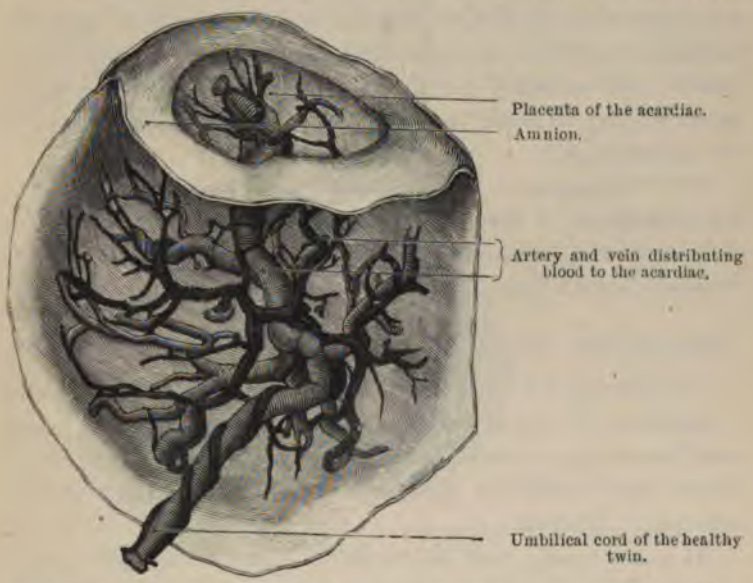

Fig. 247.—Placenta from a case of twins, one of which was an acardiac. (*After Astley Cooper.*)

the trunk axis of the embryo or from complete dichotomy. In the latter case, while one twin has gone on to full development, the growth of the other has been arrested, and in some cases the suppression has been so great that the companion fœtus is represented by a deformed or shapeless mass consisting of integument covering ill-formed pieces of the skeleton and portions of viscera. The best evidence that parasitic fœtuses and teratomata arise from cleavage is this: We always find like parts attached to like parts; head to head, pelvis to pelvis, thorax to thorax—to this I do not know an exception.

In a few cases of parasitic fœtuses we are able to offer a probable opinion as to whether the reduplicated parts are due to partial dichotomy of the trunk or are the result of complete cleavage, in which one of the fœtuses becomes an acardiac. In very many, indeed in the majority of teratomata, it is absolutely impossible to decide in favour of one method or the other.

Treatment.—Parasitic acardiacs are in almost all cases so extremely valuable as sources of gain in fairs, shows, and large cities that the parents, or the unscrupulous individuals who get possession of these children, will not permit operative interference. When the parasitic acardiac is of the amorphous variety and attached to the dorsal surface of the sacrum, attempts may be made to remove it. The child rarely survives the interference.

The xiphiopagous twins, Radica and Doodica (Fig. 241), are remarkable in this respect, for Doodica became the victim of tuberculous peritonitis and Doyen divided the uniting band. Doodica died six hours after the operation, but Radica survived.*

DERMOIDS AND TERATOMATA OF THE PHARYNX AND PALATE.

Considering the very distinctive features of a dermoid and a teratoma, it would scarcely be imagined that a tumour could come under observation in connection with the pharynx where there would be difficulty in deciding whether it was dermoid or teratoid.

It is noteworthy that the regions in relation with the cephalic as well as the caudal termination of the notochord are common positions for teratomata, and a great deal of the confusion which formerly encompassed the nature of those masses, generically classed as congenital sacro-coccygeal tumours, in a measure surrounds congenital tumours of the pharynx and palate. The matter is rendered more difficult by the fact of the complex details of development associated with the formation of the palate.

Dermoids of the palate and naso-pharynx usually take the form of pedunculated skin-covered tumours. The central part of the tumour consists of a solid core of connective tissue, hyaline cartilage, and a variable amount of striped muscle-

* *Brit. Med. Jour.*, 1902, vol. i. 465.

tissue. The skin is usually beset with hair. A dermoid of this kind is always congenital, rarely large, and in many cases it is difficult to decide whether the tumour grows from the palate or from the base of the skull and projects through a gap in the bony palate. Sometimes the attachment is so slender that the dermoid undergoes spontaneous detachment; in the case reported by Lambl * the child swallowed the tumour and voided it next day by the anus. Occasionally the tumour is sessile, and may even project into the floor of the pituitary fossa and compress the optic nerves and tracts.

Windle † has collected the literature relating to dermoid and teratoid tumours of the pharynx under the title of *Epig-*

Fig. 248.—Pedunculated skin-clad pilose tumour from the pharyngeal aspect of the soft palate. (*Arnold.*)

nathus, and has summarised the various views in regard to the nature of this condition. It is noteworthy that a pedunculated skin-clad and pilose tumour, such as Fig. 248, is only found in the naso-pharynx and rectum; in each situation they sometimes possess one or more teeth.

In describing teratomata care was particularly taken to emphasise the fact that many cases of duplicity of parts depended on dichotomy. Cleavage may be so slight at the cephalic end of the embryo as only to involve the face or even the jaws. Of this I have described several specimens, which make it clear that an identical state of things takes place in

* Virchow's *Arch.* bd. cxi. 176.

† *Journal of Anat. and Phys.*, vol. xxxiii. 277.

tubular structure is richly provided with glands. Occasionally the communication of the appendix with the cæcum is obstructed, and the glands continuing to secrete, the accumulating fluid distends the appendix into a sausage-shaped cyst.

The uterus is another example. After a difficult labour the walls of the cervical canal are not unfrequently damaged, and in the process of repair the canal may become obstructed. This leads to retention of the products secreted by the uterine glands, and the uterus will attain such proportions as to cause the enlargement to be attributed to pregnancy; the condition, is known as **hydrometra.** It is occasionally seen in women, but is more common in mammals, normally furnished with bicornate uteri, such as ewes, cows, mares, and sows. It may be unilateral or bilateral.

When occurring in mammals in which the uterus has long cornua—*e.g.* cat, bitch, hare, etc.—the distended cornua are apt to be confounded with Fallopian tubes. It may affect one or both cornua of a bicornate uterus in a woman.

The danger of retention of this kind is due not so much to the size of the cyst as to the great risk that ensues when large collections of retained secretions are invaded by putrefactive organisms. The cysts in such an event become converted into abscesses, and the life of the individual is greatly imperilled. These changes in retention cysts are indicated by special names—as **pyometra, pyonephrosis,** etc.

The Gall Bladder.—This structure illustrates very well the mode of formation of retention cysts. The gall bladder consists of three coats, of which the middle one contains unstriped muscle-fibre; the inner one is mucous membrane beset with mucous glands, its epithelium being directly continuous with that lining the hepatic ducts on the one hand and with the epithelium covering the duodenum on the other. The outer coat is derived from the peritoneum and subserous tissue. Bile from the hepatic ducts is conveyed into the gall bladder by way of the cystic duct, and when it escapes from the gall bladder it again traverses the cystic duct and passes along the common bile duct to the duodenum. The common duct just as it enters the wall of the intestine receives the duct of the pancreas. The point of junction is indicated by a slight recess known as

the diverticulum of Vater. The peculiar arrangement of the ducts leading to and from the gall bladder renders it peculiarly liable to have its communications interfered with. Obstruction may occur in the cystic duct (Fig. 249) in the common duct, in the diverticulum of Vater, or in the wall of the duodenum. The obstruction may be due to impacted gall-stones, a pancreatic concretion in the diverticulum, tumours of the pancreas, duodenum, primary cancer of the common bile duct, etc.

When obstruction in the **common duct** is complete and persistent, the gall bladder may atrophy. When incomplete, or if when complete the obstruction be only temporary, and especially if frequently repeated, the gall bladder will become greatly distended. When the cystic duct is obstructed, and no bile finds its way into the gall bladder, the latter may become so distended with mucoid fluid and attain such large proportions as to be mistaken for an ovarian cyst. The fluid that accumulates in the gall bladder under these conditions is probably the result of cholecystitis.

Fig. 249.—Gall bladder distended with mucus secondary to obstruction of the cystic duct with gall-stones. The triangular piece of liver attached to it was removed with the gall bladder.

Ranula.—This term is probably one of the oldest in surgery, and its etymology is not very obvious. Until recently it was applied to all cysts in the floor of the mouth, and as cysts in this situation are of various kinds and arise from different structures, it naturally followed that the term gradually came to possess a merely topographical significance. There is at the present time a strong tendency to restrict the name ranula to cysts arising in connection with the ducts of the three sets of salivary glands opening into the mouth, and to designate them as submaxiliary,

sublingual, or parotid ranulæ, according to the gland affected. If surgeons would use the term in this definite sense much unnecessary discussion would be saved.

In the majority of cases ranulæ are probably retention cysts due to obstruction of a duct. They are common in connection with the submaxillary and sublingual glands. The cysts are, as a rule, thin-walled, and lie in the furrow between the gum and the tongue and bulge upwards into the floor of the mouth. When large they cause a prominence in the submaxillary triangle. The cyst may be filled with saliva. Sometimes it contains mucus and a yellow substance resembling the yolk of an egg.

Occasionally the obstruction is caused by a calculus impacted in the orifice of the duct, but cases come under observation in which the duct is not completely obstructed, yet the fluid is retained. It is reasonable to believe that ranulæ sometimes arise independently of obstruction to the main duct, and, as in the case of pancreatic ranulæ, observation supports the view that there is, in all probability, a pathological cause apart from mere obstruction concerned in their production.

Parotid ranulæ are rare in the human subject, but they have been observed in calves, oxen, and horses.

Submaxillary and sublingual ranulæ occasionally follow amputation of the tongue, due, no doubt, to injury of the duct or its implication in cicatricial tissue.

Much needless discussion has taken place in regard to the sources of ranulæ, because the various writers seem to forget that in addition to salivary glands there are mucous glands, and one of variable size near the tip of the tongue known as Nuhn's gland. Any of these may dilate into a cyst. Still further to complicate the diagnosis, dermoid cysts not unfrequently arise in the floor of the mouth near the frænum of the tongue or deeply in its substance. It has also been urged, as an objection to the view that ranulæ arise in the ducts of the salivary glands, that the fluid they contain is not always saliva. This is very weak argument. Many hydronephrotic cysts contain fluid which it would be difficult to regard as urine, and an obstructed gall bladder is sometimes filled with fluid

that does not possess a single attribute of bile. So a cyst arising in connection with a salivary gland will sometimes contain fluid that fails to furnish the characteristic reactions of saliva.

Pancreatic Cysts.—It has long been known that the duct of the pancreas is liable to become dilated, and as the condition is analogous to the distension of the ducts of the buccal salivary glands, dilatation of the pancreatic duct (canal of Wirsung) is sometimes referred to as a "pancreatic ranula."

Virchow recognised two varieties of pancreatic ranula. In one variety the canal is dilated irregularly throughout its whole extent, so that it assumes the appearance of a chaplet of cysts; in the other the duct is dilated immediately behind its terminal orifice. Such cysts, he writes, may attain the size of a fist, and are consecutive to cicatricial contractions and compression by tumours. The cysts are not filled simply with pancreatic secretion, for when they attain a certain size they will be found to contain mucoid material, products of hæmorrhages, and, not rarely, calculi. Judging from what is known of retention cysts in general, it would, as a matter of simple inference, be thought that pancreatic ranulæ arise from partial obstruction to the pancreatic duct, either from impaction of a pancreatic calculus in the terminal segment of the duct, a gall-stone lodged at the duodenal orifice, or a tumour arising in connection with the ducts or tissues in the immediate neighbourhood. This, however, does not appear to be the case, for pancreatic cysts have been observed and no obstruction has been detected.* Besides this, the duct of the pancreas has been found completely obstructed by a calculus, and the gland, instead of being converted into a cyst, has atrophied, its secreting elements being largely replaced by fibrous tissue.

Experimental evidence also supports this conclusion, for it has been demonstrated that when the pancreatic duct is occluded during life by a ligature, the gland does not become cystic, but atrophies. Thus experimental and clinical evidence indicates that pancreatic cysts are the result of pathological changes which may, or may not, be associated with obstruction of the duct.

A great deal of attention has, during the past ten years,

* Clutton, *St. Thomas's Hosp. Reports*, 1893.

been devoted to pancreatic cysts in their clinical as well as their pathological aspect, and certainly the evidence indicates that other causes than obstruction, partial or complete, are responsible for their production.

Cysts described as pancreatic sometimes attain very large proportions, and examples have been reported with a capacity of two gallons or more. These very big cysts form smooth globular swellings in the upper part of the belly. They lie behind the peritoneum, and, of course, have the stomach and transverse colon in front; when very large these cysts will extend some distance below the transverse colon.

The fluid contained in large pancreatic cysts is usually turbid. Sometimes it is white or even opalescent, occasionally it is clear, and in some cysts it will have a brown or even a green tint. The specific gravity varies between 1010 and 1020, and there is a small trace of albumen. Mucin is often present, also tyrosin and blood pigment, and traces of urea have been detected. The fluid is sometimes capable of emulsifying fats.

The modes by which very large pancreatic cysts arise are not by any means clear, but it is important to bear in mind that there is, in a very significant proportion of cases, a definite history of antecedent injury. This fact gives colour to the suggestion that some of the cysts are due primarily to laceration of the pancreas and subsequent extravasation of its secretion behind the peritoneum. Another very important feature of these cysts is the liability to hæmorrhage, and this may take place so abundantly into the cyst as to jeopardise the life of the patient; indeed, in some cases it has been fatal.

Pancreatic cysts occur at almost all periods of life. Examples have been reported as early as the eighth year of life and as late as the seventy-third. They appear to be most frequent in men, but a number of cases have been reported in women.

Pancreatic cysts attributed to injury have followed a variety of accidents, such as falls from a great height, followed by abdominal pain; a crush of the abdomen between the buffers of railway waggons; fall from a horse, or from a vehicle; kicks from men, and in several cases from horses.

Jordan Lloyd * has attempted to show that the large pan-

* *Brit. Med. Journal*, 1892, vol. ii. 1051.

creatic cysts that follow injury to the abdomen are really collections of fluid in the cavity of the lesser omentum, and when the fluid has the property of rapidly converting starch into sugar it may be assumed that the pancreas has been injured. He also points out that the characteristic feature of so-called pancreatic cysts—viz. a swelling occupying the epigastric, umbilical, and left hypochondriac regions—is precisely that which would result from distension of the lesser bag of the peritoneum. It is probable that some cases of supposed pancreatic cysts were really effusions into the lesser bag of the peritoneum, for undoubted examples of distension of this cavity with fluid have been observed, dissected, and described. The whole subject of so-called pancreatic cysts has been ably handled and the literature collected by Leith.*

Dacryops.—This term is applied to cysts occurring in the upper eyelid; they are due to distension of the ducts of the lacrimal gland. They appear, as a rule, in the upper and outer part of the eyelid, the cyst extending beneath the border of the orbit towards the lacrimal gland. The cyst enlarges when the patient weeps. Dacryops may arise in two ways—either as a consequence of wound or abscess of the lid, or as a congenital defect. As a rule, they are of traumatic origin. The condition is one of extreme rarity.

Hulke,† in an interesting paper on this subject, states his belief that these cysts were first accurately described by Dr. J. A. Schmidt in 1803, and that Beer (1817) mentions that he had six cases of this kind, which he describes under the name "dacryops" which Schmidt had applied to them.

When these cysts are opened through the skin a fistula is sure to be the result. The same thing often happens when the cysts have a traumatic origin. The condition is then termed *dacryops fistulosus.*

Cysts of the Hyaloid Canal.—This tiny relic, which sometimes persists in the vitreous after the disappearance of the central hyaloid artery, may occasionally dilate and form a cyst large enough to be visible on ophthalmoscopic examination.‡

* *Ed. Med. Journal*, November, 1895.

† *R. Lond. Ophth. Hosp. Reports*, vo i. 285.

‡ Tatham Thompson, *Brit. Med. Journal*, 1899.

CHAPTER L.

RETENTION CYSTS (*continued*).

HYDRONEPHROSIS.

THE secretion (urine) of the kidneys is conducted into the bladder by means of two ducts (the ureters); from the bladder the urine is discharged at intervals through the urethra. When from various causes the urine is hindered from escaping freely, either from the bladder, or from the ureters into the bladder, it accumulates in the ureters and dilates them; the pressure of the fluid then acts upon the pelvis of the kidneys, and if maintained causes the renal pelvis to be dilated into large sacs, converts the infundibula into large tubes, and finally induces atrophy of the renal tissue until the kidneys are converted into multilocular sacs. To a kidney altered in this way the term hydronephrosis (Rayer, 1839) is applied. Hydronephrosis arises from a variety of causes, and the condition of the ureter associated with it depends on the cause and situation of the obstruction. It is also important to bear in mind that the largest examples of hydronephrosis are produced by partial obstruction to the flow of urine or to frequently recurring attacks of complete obstruction. It is also a curious fact that in many of the argest examples of hydronephrosis it is difficult to demonstrate the cause.

Hydronephrosis may be bilateral or unilateral. When the obstruction is at the neck of the bladder or in the urethra it will be bilateral.

The chief causes of **Bilateral hydronephrosis** are :—

Calculus in the urethra or in the bladder (Fig. 250).

Stricture of the urethra.

Tumours of the prostate gland, especially a pedunculated adenoma (Fig. 162).

Tumours and cysts of the pelvic organs; especially impacted uterine and cervix fibroids.

In bilateral hydronephrosis secondary to obstruction at the neck of the bladder, an interesting change may sometimes be observed at the vesical orifices of the ureters. Normally these openings scarcely admit a fine probe, but under the conditions

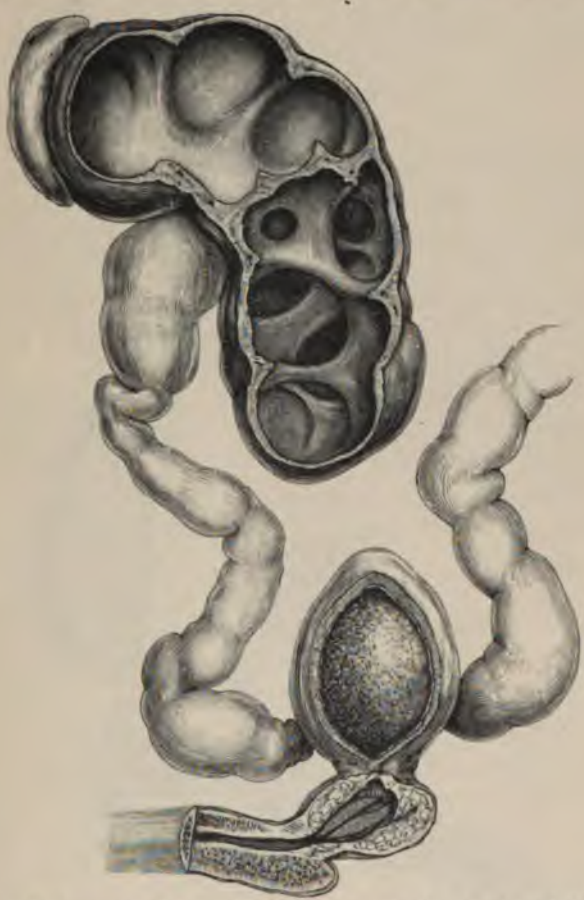

Fig. 250.—Hydronephrosis secondary to a large calculus in the bladder; two fragments of calculus occupy the prostatic portion of the urethra. The left kidney was in a similar condition. The patient, a man 26 years of age, died with complete suppression of urine. (*Museum, Middlesex Hospital.*) ($\frac{1}{3}$ *nat. size.*)

just mentioned will assume a circular form, and be large enough to admit the tip of the little finger, so that fluid injected into the bladder through the urethra will enter the ureters and gain the dilated pelves of the kidneys. This condition is particularly apt to supervene upon oft-repeated attacks of retention of

urine secondary to pressure on the urethra exercised by a uterus occupied by fibro-myomata, especially those which grow in the cervix and become impacted immediately before the incidence of a menstrual period.

Fig. 251.—The urinary organs with the right adrenal of a new-born child.

Ante-Natal Hydronephrosis.—A very large number of examples of hydronephrosis have been carefully examined and recorded in children at birth, and in some of the instances the distension of the pelves of the kidneys has been so great as to

obstruct delivery and entail embryotomy in order to allow of the extraction of the fœtus.

In many of the records the reporters state that they were unable to find anything to explain the condition; in many of the more recent cases, however, the cause of the obstruction has been determined. The chief of these are :—

Imperforate urethra (Figs. 260, 262).

Imperforate hymen (Fig. 263).

Torsion of the penis (Fig. 252).

Ante-natal hydronephrosis is a subject of great interest, because it serves to show that the kidneys are functional in the late stages of fœtal life, and supports the view that the bath of amniotic fluid (or hydrosphere) in which the fœtus floats represents, at any rate in part, fœtal urine. It also throws some light on cases of advanced hydronephrosis sometimes met with in infants and young children, and for which no adequate cause has previously been forthcoming.

The urinary organs represented in Fig. 251 were obtained from an infant which survived its birth a few days. The right kidney only was present; it occupied its normal position in the loin. Its infundibula, pelvis, and ureter were widely dilated, and at the point where the ureter opened into the bladder there was a small circular diaphragm-like valve, but this structure offered no obstruction to the flow of fluid from the ureter into the bladder when tested after death.

The bladder presented only one ureteral orifice, and its walls were thinner than usual. The penis, urethra, and testicles were normal, and the left adrenal occupied its usual position. No traces of the left renal artery, vein, or ureter were found. The anus was normal.

In this case dissection failed to bring to light anything to account for the distension of the excretory ducts of the kidney, but it clearly indicated that mechanical obstruction of some kind interfered with the flow of urine through the vesical orifice of the ureter.

Torsion of the Penis.—It is an undoubted fact that torsion of the penis and bilateral hydronephrosis are sometimes associated, and it is possible that in some cases of congenital double hydronephrosis in which there was great dilatation of

the ureters and in which careful dissection of the parts failed to detect any organic cause to account for it, twisting of the penis may have been overlooked.

An example of torsion of the penis is represented in Fig. 252. The patient, a baby three months old, had his penis directed laterally; when the organ was brought into a natural position, on being released it at once resumed its abnormal deflection to the left. This penis, as is the case with twisted penes in general, was unusually large. There was also a groove on the under surface of the glans indicating a minimum degree

Fig. 252.—A twisted penis. The small figure shows the groove on the glans and the absence of the frænum. (*Nat. size.*)

of hypospadias; the frænum was absent. At the angle of torsion there is a sac-like pouch of skin. The penis is probably distorted in this way by the pressure of the thighs whilst in the uterus, and it is possible that the penis may be nipped between the thighs and obstruct the urethra and lead to hydronephrosis without actually twisting the penis.

Unilateral Hydronephrosis has many causes:—

Retention of a calculus in the ureter.

Tumour of the bladder implicating the vesical orifice of the ureter.

Calculus lodged in the pelvis of the kidney and blocking the orifice of the ureter (Fig. 257).

Partial rotation of the kidney kinking the ureter.

Tumours and cysts of the pelvic organs pressing on the ureter.

Cicatrix of the ureter due to injury.

Inadequacy of the ureter. (Fig. 255.)

It has been suggested that the ureter is occasionally obstructed by branches of the renal artery taking an abnormal course. I have made a careful study of cases supposed to demonstrate this, and have been convinced that the unusual relation of the vessels is often due to the dilatation of the renal pelvis; and that the constricting effects supposed to be exercised by the artery are the direct outcome of the increase in the size of the pelvis.

Among uncommon varieties of unilateral hydronephrosis may be mentioned sacculation of one half of a horseshoe kidney, and the rarer anomaly in which a kidney is furnished with two ureters, one of which becomes obstructed and leads to dilatation of that portion of the renal pelvis connected with it, and corresponding atrophy of that part of the renal cortex which drains into it.

Intermitting Hydronephrosis.—When a hydronephrotic kidney is of large size it can be perceived clinically as a definite tumour. It occasionally happens that patients come under observation with a swelling in the loin which can be readily perceived at one examination but not at another, or it obviously diminishes in bulk without completely vanishing. In some of these cases the patients are able to state definitely that, coincidently with the diminution in the volume of the tumour there has been a sudden increase in the quantity of the urine voided. The urine in some instances has been found to contain traces of blood and mucus. To hydronephrosis of this kind the term **intermitting** is applied.

It must be borne in mind that there may be difficulty in some cases in deciding clinically between a very large hydronephrotic cyst and an ovarian or parovarian cyst, and it is well established that cysts of the ovary and parovarium sometimes rupture, and the fluid, escaping into the peritoneum, is absorbed into the circulation and rapidly excreted by the kidneys. Thus, *profuse diuresis following upon the sudden disappearance or diminution of an abdominal tumour is as*

characteristic of rupture of an ovarian cyst as of an intermitting renal cyst.

There can be little doubt that nearly all hydronephroses intermit, but the term intermitting hydronephrosis is reserved for those examples in which there is great diminution, and in some instances temporary disappearance, of the swelling.

Exceptionally, both kidneys when hydronephrotic may

Fig. 253.—Unilateral (intermitting) hydronephrosis (without obvious cause). The ureter, at the point where it left the renal sinus, had a diameter of 8 cm.

intermit alternately. Of this rare form I have had one case under my care; as the diagnosis was somewhat obscure, cœliotomy was performed. In the course of the operation the phenomenon of intermission was actually observed. The hydronephrosis diminished in size, and the bladder slowly filled. Intermitting hydronephrosis is also associated with the remarkable anomally known as inadequate ureter.

It is a startling fact that many of the largest specimens of hydronephrosis are those in which no obstruction could be demonstrated, and the histories of the patients fail to throw

any light on the cause (Fig. 253). The most remarkable ex-

Fig. 254.—Extreme dilatation of the ureter without obvious cause. From an old man.

ample of this is the case of Mary Nix, who died at Hampton-Poyle, near Oxford, at the age of twenty-three. She had a

hydronephrosis containing fluid to the amount of thirty gallons, wine measure. The dissection of the body was conducted by Samuel Glass * with "some learned gentlemen of the university." Nothing was found to account for the condition.

Now that we know many cases of dilated ureter and sacculated kidney to have an ante-natal cause, it is very probable

Fig. 255.—Dilated renal pelvis associated with an inadequate ureter.

that many very large hydronephroses of inexplicable origin in the adult began while the individual tenanted the uterus.

Inadequate Ureter.—It is well recognised that the junction of the renal pelvis with the ureter proper is indicated by a marked narrowing of the lumen of the duct which may be conveniently called the "ureteral strait." It occasionally happens that the ureter from this point downwards is very markedly narrow, and is sometimes even less than one-fourth its proper dimensions.

* *Phil. Trans.*, 1747, vol. xliv. 337.

Abnormally narrow ureters of the kind may be conveniently termed "inadequate." Five examples of this condition have come under my observation, and in each instance it was associated with intermitting hydronephrosis. It is an extraordinary fact in some of these cases that the urine will collect and form a sac holding two, three, or even four litres, and produce very great pain; suddenly, and without any warning, the blockade will be raised, and the urine will pass into the bladder and be

Fig. 256.—Kidney with dilated pelvis and inadequate ureter. From a woman 44 years of age.

voided, and the large cystic swelling subside in a night. This excessive narrowness of the ureter is most probably a congenital defect. On one occasion I removed one from a woman forty-four years of age, and she stated that she had suffered from "pains in her side" for twenty-five years. The view that this abnormal condition was of ante-natal origin is borne out by the lobulated condition of the vestige of the renal cortex (Fig. 256).

The silent way in which the gradual dilatation of the renal pelvis, infundibula, and calyces destroys a kidney is very extraordinary. When hydronephrosis is unilateral it rarely

betrays itself until the tumour is very large; frequently the only trouble it causes is increased frequency of micturition.

When the hydronephrosis is bilateral the signs are often in abeyance until the amount of renal capital is reduced to the minimum amount capable of meeting the ordinary demands of the individual; directly there is an extra call, then the

Fig. 257.—A pyonephrosis in section: the pelvis at its junction with the ureter is partially blocked by a calculus. (*Museum of the Royal College of Surgeons.*)

small balance of available renal tissue becomes alarmingly manifest, and the patient dies.

Pyonephrosis.—Although a hydronephrosis continues its course in silence it is almost certain to be made manifest when it suppurates, and my observations among the quick and the dead have taught me that this is one of the greatest dangers to which an individual with unilateral hydronephrosis is liable.

It is necessary to draw a distinction between pyonephrosis and suppurating hydronephrosis. In the case of a pyonephrosis

the lesion is inflammatory from the outset, whether it starts primarily in the kidney or spreads to this gland from the bladder, ureter, or elsewhere.

In some cases of suppurating hydronephrosis under my own care, I have been satisfied that the colon was the source of infection and the pus contained *bacillus coli communis*. The intimate relations existing between the kidney and colon, more especially when hydronephrotic, make one wonder that fistulous communication between these viscera is not a frequent complication.

CHAPTER LI.

CONGENITAL CYSTIC KIDNEY.

THIS term is applied to a very characteristic disease of the kidneys. In typical examples these organs are converted into cystic masses, so that they exhibit a sponge-like appearance on section. The cysts vary greatly in size; some are as small

Fig. 258.—A congenital cystic kidney in section. (*Nat. size.*) (*Museum, Royal College of Surgeons.*)

as rape-seed, other as large as cherries; they rarely exceed these dimensions. Some of the cysts project from the surface of the kidney, but though interfering with the smoothness of the gland, they do not distort it. The cortical and medullary portions of such kidneys are indistinguishably blended, but

here and there tracts of cortical tissue may be detected among the cysts (Fig. 258). In the early stages the cyst walls have a membrana propria and are lined with tesselated epithelium. In advanced stages of the disease and in the large cysts the epithelium disappears. A striking feature of these kidneys is the narrowness of the ureters, and yet in all the cases which have come under my observation these ducts have been pervious

Fig. 259.—A congenital cystic kidney ; early stage. (*Shattock.*)

throughout. The arteries supplying kidneys changed in this way are smaller than normal.

A congenitally cystic kidney sometimes attains an enormous size, so large indeed as seriously to impede labour, and in many cases embryotomy has been necessary in order to enable delivery to be effected. In a large proportion of instances in which the fœtus comes away without difficulty it is still-born and often malformed ; such conditions as anencephalia, club-foot, and spina bifida are often found associated with congenital cystic disease of the kidneys. Minor degrees of the affection

are not incompatible with life, and several instances are known in which such kidneys have been found in adult individuals.

Although this condition of kidney is very common and specimens illustrating it exist in many pathological museum, we know very little concerning the early stages. I have examined a well-marked example in a fœtus of the sixth month, and Shattock * observed one at the fourth month. The earliest stage has been observed by Shattock (Fig. 259), and a careful examination of the minute structure of the cyst, as well as a comparison of the history of the cyst with that of the mesonephros (Wolffian body), induced him to think it probable that these kidneys consisted of a combination of mesonephros and metanephros. Virchow † regarded the cysts as dilatations of the uriniferous tubules in consequence of the absence of a renal pelvis. It is, however, a curious fact that "congenital cystic kidney" occasionally occurs in association with imperforate urethra. A very remarkable case came under my notice in which a child born at full term, but with great difficulty on account of the large size of its belly, was found to have an imperforate urethra, a large dilated left ureter, and a hydronephrotic left kidney. The opposite kidney was a typical example of the congenital cystic kidney (Fig. 260). This combination of the two forms of hydronephrotic and congenital cystic kidney in the same individual, associated with imperforate urethra, supports Virchow's view that these cysts are due to ectasia of uriniferous tubules.

The large number of specimens of congenital cystic kidney preserved in museums indicates that the condition, if advanced at the time of birth, is incompatible with life. It is, however, quite certain that a precisely similar change is met with in adults, and what is also remarkable, it is very frequently associated with a similar cystic change in the liver. ‡ The available facts indicate that a moderate amount of cystic change in the kidneys is not incompatible with life, but as the disease advances the secreting tissue of the organs is slowly

* *Trans. Path. Soc.*, vol. xxxix. 185.

† "Ueber Congenitale Nierenwassersucht, Gesammelte Abhandlungen," s. 839.

‡ Pye-Smith, *Trans. Path. Soc.*, vol. xxxii. 112

but surely destroyed, and in due course uræmia supervenes and the patient dies.

There is reason to believe that this cystic change may be limited to part of a kidney. Edmunds * described a specimen (Fig. 261) which he removed from a girl of eighteen years, in

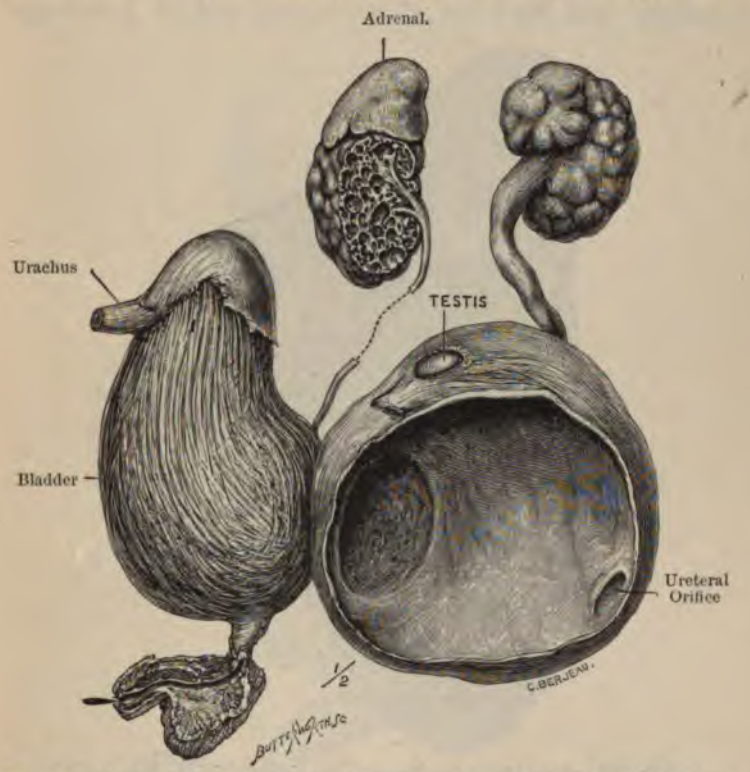

Fig. 260.—Urinary organs of a fœtus. The urethra is imperforate, the bladder hypertrophied, the left ureter dilated, and the kidney hydronephrotic. The right kidney is a congeries of cysts (congenital cystic kidney).

which "an encapsuled tumour" projected into one of the calyces of the kidney. It had a diameter of 6 cm., and was composed of a "congeries of cysts" lined with cubical epithelium.

The specimen shown in Fig. 260 is interesting from the light it throws on the conditions described as bifid bladder. Connected with the side of the bladder is a large sacculus with a capacity

* *Trans. Path. Soc.*, vol. xliii. 89.

of 300 c.c. The left ureter opens into this sacculus by a valvular orifice; the ureter itself is dilated throughout as well as the renal pelvis, and the sacculus communicates with the vesical cavity by an orifice three centimetres in diameter. A careful study of the relations of the sacculus proves that it is an enormous local dilatation of the ureter, and as it enlarged

Fig. 261.—Localised cystic disease of the kidney. (*After Edmunds.*)

it carried on its crest the testis; the spermatic vessels were seen in the fresh condition of the specimen stretched across its wall.

I am of opinion that many specimens which have been loosely described as bifid bladders were probably of the same character as this. Some specimens described as bifid bladders, are due to dilatation of the urachus (allantoic cysts), and others reported as examples of lateral bifidity of the bladder, or congenital diverticulum of the bladder, were in all probability enlargement of the vesical end of the ureter.

Assuming that the congenital cystic kidney is due to pressure leading to dilatation of the uriniferous tubules, we are met by a difficulty in dealing with the specimen, Fig. 260: the same cause has produced hydronephrosis in one kidney and general cystic disease in its fellow. I think the difference may be, in

Fig. 262.—Fœtus of the fourth month, with imperforate urethra and a large distended bladder. The kidneys were cystic, as in Fig. 260. (*Shattock.*)

part perhaps, explained by the period of intra-uterine life at which the obstruction manifests itself.

Shattock * described a fœtus of the fourth month with an imperforate urethra; this fœtus had a very large dilated bladder (Fig. 262), and both kidneys were typical examples of general cystic disease.

* *Trans. Path. Soc.*, vol. xxxix. 185.

The museum of St. Bartholomew's Hospital contains the reproductive organs of a child born at full time: the hymen was imperforate and the bladder greatly distended; the vagina was converted into a large cyst containing mucus (Fig. 263). The pressure of the distended vagina has compressed the urethra, distended the bladder, and dilated the renal pelvis,

Fig. 263.—Kidney, uterus, vagina, and bladder of a new-born child, shown in section. The distension of the vagina and uterus is due to an imperforate hymen. The ureter is widely dilated and the kidney sacculated. (*Museum, St. Bartholomew's Hospital.*)

producing the condition known as sacculated kidney. A comparison of these specimens seems to indicate that the dilatation of the uriniferous tubules which results in general cystic disease of the kidneys is due to some cause acting very early in embryonic life. When obstruction to the outlet of urinary secretion occurs in the later stages of intra-uterine life, dilatation of the renal pelvis and its recesses (hydronephrosis) is the more frequent consequence.

It is, however, a point of some importance to realise that

there are cases in which the kidneys, though the seat of general cystic disease, are capable of performing their function and the individual attains adult life. In such cases the cysts of the kidneys increase in size and the organs attain the proportions of full-grown pumpkins. Eventually the secreting substance of the kidney is destroyed and the patient slowly dies from uræmia. It is important to realise this condition of kidney, because in several instances surgeons have removed organs enlarged in this way: such interference has not been to the advantage of the patients. The museum of the Royal College of Surgeons, London, contains an excellent series of specimens illustrating general cystic disease of the kidney in man and other mammals.

CHAPTER LII.

TUBULO-CYSTS.

THE human body, in common with that of many other mammals, contains a certain number of tubes which, so far as is known, serve no useful purpose in the adult, and may be called in consequence **functionless ducts.** Some of these—*e.g.* the vitello-intestinal duct and the urachus—were probably useful to the embryo; others, like the parovarium and Gärtner's duct, are serviceable in the male, as they act as conduits to the testis. Functionless ducts must not be confounded with **obsolete canals**: these serve no useful purpose in man, but were, in all probability, functional in the ancestors of existing vertebrata. Both sets of canals are of interest to the pathologist, as they are the source of cysts which are not only inconvenient to the individual but actually dangerous to life.

The genus **Tubulo-Cysts** includes the seven following species:—(1) Cysts of the vitello-intestinal duct; (2) Cysts of the urachus; (3) Paroöphoronic cysts; (4) Parovarian cysts; (5) Cystic disease (adenoma) of the testis; (6) Cysts of Gärtner's duct; and (7) Cysts of Müller's duct.

Cysts of the Vitello-Intestinal Duct.—It is not uncommon to find connected with the umbilicus of babes and young children small tumours varying in size from a pea to a cherry. These tumours are bright red, soft and velvety to the touch, and are, as a rule, connected to the navel by slender pedicles, and in appearance resemble red currants; occasionally they are sessile.

These tumours are composed of unstriped muscle fibre, mucous membrane, Lieberkühn's follicles, and columnar epithelium, collected into a mass. Typical cases have been carefully described by many observers.

In rarer cases the umbilicus is occupied by a cyst, which may project externally or internally. Such a cyst is lined with mucous membrane furnished with villi, columnar epithelium

and follicles. A cyst of this character is easily confounded with the sac of an umbilical hernia.

The histology and position of pedunculated tumours and sessile cysts at the navel indicate the structure from which they arise—viz. a remnant of the vitello-intestinal duct which, in the embryo, traverses this part of the abdominal wall (Fig. 264). In transverse sections of the umbilical cord, close to the belly wall of the embryo at the fifth month, the vitello-

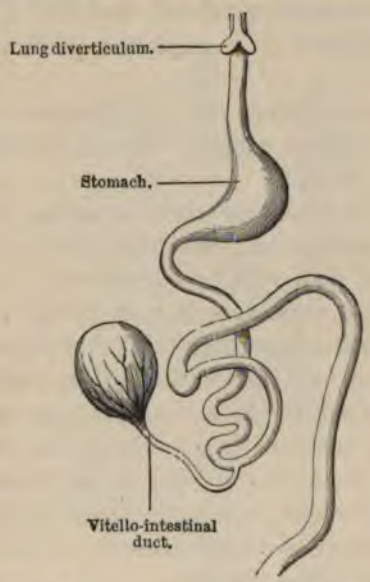

Fig. 264.—Diagram of the alimentary canal of the embryo, showing the position of the yolk sac.

intestinal duct can often be detected, with its lumen lined with sub-columnar epithelium. It is also well known that the duct, instead of shrivelling, sometimes grows *pari passu* with the gut to which it is connected, and acquires a lumen almost equal to that of the ileum. Instead of persisting from the gut to the navel the duct may atrophy, leaving a small portion attached to the intestine or to the abdominal wall. Such remnants may develop into cysts the walls of which are identical in structure with those of small intestine.

A much rarer variety of cyst arising in a remnant of the vitello-intestinal duct is due to the distension of that portion

of the duct which is connected with the ileum. In recently hatched chicks the intestinal attachment of the duct is often indicated by a nipple-like process on the free border of the gut. This is hollow, but does not communicate with the lumen of the ileum. As a rule it atrophies completely. It may, however, grow and form a large cyst. The museum of the Royal College of Surgeons contains a piece of intestine from an emu chick with a large cyst suspended from it by means of a narrow and acutely torsioned pedicle. This cyst in all probability originated in a persistent portion of the vitello-intestinal duct.

Cysts of like proportions and of identical origin have been recorded in the human subject. One of the best-known cases was reported by Roth.*

Occasionally a persistent vitello-intestinal duct will remain open at the umbilicus and discharge fæces. Such cases have been successfully dealt with by surgeons.†

There are few structures in our bodies more capable of exciting philosophical speculation than the yolk sac and its duct. This organ may in man and all the higher mammals be regarded as vestigial, for its duties have been in part abrogated by the allantois, but more completely by the placenta. In the human embryo it is the function of the allantois to convey the blood-vessels which it receives from the developing aorta and distribute them to those chorionic villi destined to form the fœtal portion of the placenta.

In some sharks the yolk sac is covered with vascular villous tufts which fit into depressions of the oviduct. Even in some mammals—*e.g.* guinea-pigs—the yolk sac enters into vascular connection with the uterine mucous membrane. There are abundant and good reasons for Balfour's conclusions that placental mammals are descendants of forms the embryos of which had large yolk sacs; but the yolk became reduced in quantity owing to the nutriment the embryo received from the maternal tissues by means of the vascular connection of the yolk sac with the uterine wall. Subsequently the function of the yolk sac became limited by the allantois and the gradual

* Virchow's *Arch.*, bd. lxxxvi., s. 371.
† Battle, *Trans. Clin. Soc.*, vol. xxvi.

evolution of the placenta, and finally, so far as man is concerned, abolished. Thus in man it is vestigial, and, like such structures in general, is liable to many vagaries.

There is good reason to believe that the vitello-intestinal duct, besides being a source of cysts, is also responsible for the curious defect in the ileum to which I have applied the name **imperforate ileum**. It occasionally happens that the lumen of the ileum is interrupted by a perforated diaphragm (Fig. 265). To such a condition the term **septate ileum** is

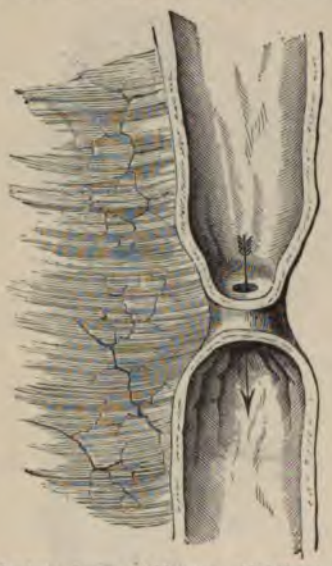

Fig. 265.—Septate ileum. (*Museum, Middlesex Hospital.*)

applicable. When such a diaphragm is present its situation is sometimes indicated by a marked constriction of the gut. In other specimens a more or less perfect valve of this kind is associated with a persistent duct. In such cases the duct opens into the ileum on the distal side of the valve. In other instances the ileum becomes greatly dilated near its middle, and the walls are much hypertrophied; to this succeeds a narrow isthmus which opens into a normal segment of ileum. Lastly, in the complete form the ileum is interrupted (Fig. 266).

These curious defects are attributable to the influence of the vitello-intestinal duct because they always occur in that portion of the ileum to which the duct, when persistent, is

attached—that is, they do not occur within 30 cm. of the ileo-cæcal valve, and are rarely found at a greater distance than 1 metre from the cæcum.

The most reliable evidence for associating these defects with the duct of the yolk sac is that furnished by specimens in which a persistent duct and a valve coexist. In my early observations I had regarded imperforate ileum as depending upon the influence of the vitello-intestinal duct, and subsequent observations put the speculation on a sound basis.* The specimens

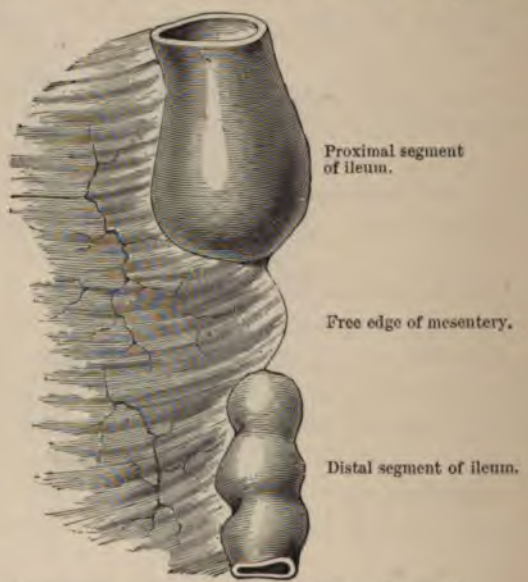

Fig. 266.—Imperforate ileum. (*Museum, Middlesex Hospital.*)

which demonstrate these views are preserved in the museum of the Middlesex Hospital.

Cysts of the Urachus.—The urinary bladder of man, in common with that of other mammals, presents at its apex an impervious cord that passes to the umbilicus. This cord, known as the *urachus*, is traversed at birth by a narrow canal lined with epithelium directly continuous with that of the bladder.

The urinary bladder with the urachus is the persistent portion of the allantois, the organ which in the early embryo conveys blood-vessels from the aorta to the developing placenta.

* *British Medical Journal*, 1891, vol. i. 342.

In the adult the urachus lies in the subperitoneal tissue exactly in the middle line of the anterior abdominal wall, between the summit of the bladder and the umbilicus. When the urachus becomes dilated it forms a cyst lying outside the peritoneum and in close relation with the bladder.

Instead of a portion of the allantois narrowing to form a urachus, the whole of its intra-abdominal portion may dilate and form a large urinary bladder.

Several cases are known in which the umbilical end of the urachus has remained patent so that urine was voided at this spot. A urinary calculus has been extracted from such a persistent urachus.*

Cysts of the dimensions of a cherry are not uncommon in the urachus, especially near the summit of the bladder; sometimes a number of small dilatations occur causing the urachus to assume a moniliform appearance.

In rare cases the urachus may dilate into a cyst as large as a distended bladder. The walls of such cysts are composed of unstriped muscle tissue. Care must be taken not to confound a sacculus at the apex of the bladder, or extending into the suspensory ligament, with the cyst arising in the urachus.

Lawson Tait † drew attention to the probable origin of some forms of extra-peritoneal cysts in the urachus, and the whole matter has been subjected to a very critical and painstaking analysis by Doran.‡

Allantoic (urachus) cysts not only occur in man, but I have observed them also in the pig, horse, ox, and mole.

* Thomas Paget, *Med.-Chir. Trans.*, vol. xxxiii. 293, and vol. xliv. 13.

† *Brit. Gyn. Journal*, vol. ii. 328; Wutz, "Ueber Urachus und Urachuscysten"; Virchow's *Arch.*, bd. xcii. 387.

‡ *Med.-Chir. Trans.*, vol. lxxxi. 302.

CHAPTER LIII.

TUBULO-CYSTS (*continued*).

CYSTS ASSOCIATED WITH VESTIGES OF THE MESONEPHROS (WOLFFIAN BODY), ITS TUBULES AND DUCT.

It is well established that in the embryo the mesonephros is closely associated with three organs, the testis, ovary, and kidney. It is also a fact that in at least two situations—viz. in the ovary and in the testis—remnants of the glandular elements of the mesonephros may be occasionally met with in the adult. Many of the tubules of the mesonephros and its duct function in the male as excretory ducts for the testis, but in the female they persist in a vestigial condition as the parovarium and Gärtner's duct.

There is abundant evidence for the belief that many cysts connected with the testis, ovary, parovarium, and vagina arise from vestiges of the mesonephros and its excretory canals. It will be convenient to begin the description of these cystic conditions by considering those which arise in vestiges of the glandular portion of the mesonephros in the **female.**

Cysts of the Paroöphoron.—The ovary consists of two parts, the oöphoron and the paroöphoron. The egg-bearing portion is the oöphoron. The paroöphoron contains no ova, but receives the tubules of the parovarium (Fig. 270). It represents the remnants of the mesonephros, and is homologous with the paradidymis of the testis. In the adult ovary the paroöphoron consists mainly of fibrous tissue permeated with blood-vessels, but in the fœtus and young child it retains, in a measure, its glandular character.

The cysts which arise in the paroöphoron are, as a rule, unilocular, and differ from those arising in the oöphoron in the following particulars:—

They do not affect the shape of the ovary until they have attained an important size.

They always burrow between the layers of the mesosalpinx, and when large make their way between the layers of the mesometrium by the side of the uterus.

The interior is beset with warts.

They are most frequent between the twenty-fifth and fiftieth years.

The warts in such cysts vary greatly in number. Sometimes only a few clusters are present, but in others they are so luxuriant as to cause the cyst containing them to rupture. These warts are very vascular, bleed freely when handled, and are frequently calcified.

Coblenz * was the first clearly to identify and distinguish these cysts from those arising in the parovarium and associate them with definite structures. His observations have been largely confirmed by Doran,† who has devoted great attention to this question.

The distinguishing feature of these paroöphoronic cysts is that they contain *papillomata; but all papillomatous cysts of the ovary are not paroöphoronic in origin.* It will therefore be convenient in this chapter to consider the subject of warts in relation to the ovary. A paroöphoronic cyst may contain one large tuft surrounded by a few scattered nodules, whereas in another example the cavity of the cyst may be so stuffed with them that it bursts. The museum of the Royal College of Surgeons, London, contains an admirable specimen illustrating this. It is thus described in the catalogue:—"An uterus with its appendages. A mass of finely lobulated and pedunculated growths springs from the site of each ovary, the substance of which, with follicles, was discovered on close search at the roots of the growths. These growths were probably enclosed at an early stage in a cyst wall" (Figs. 267 and 268)

There can be little doubt that the opinion expressed in the catalogue that the growths were probably enclosed at an early stage in a cyst is correct, for remnants of the cyst wall are still present on the specimen.

A distinction must be drawn between rupture of the cyst

* Virchow's *Arch.*, bd. lxxxiv. 26.

† *Trans. Path. Soc.*, vol. xxxii. 147.

and perforation of the cyst wall by the papillomata. In the latter condition cauliflower-like masses of warts project from the surface of the cyst into the abdominal cavity; sometimes at one spot, sometimes in three or four places. In the specimen mentioned above the cysts have ruptured, for it will be seen, on reference to Fig. 267, that the parts have been beautifully prepared, and that the anterior layer of the mesometrium is sharply indicated; below this the true cyst wall is easily recognised on the right side.

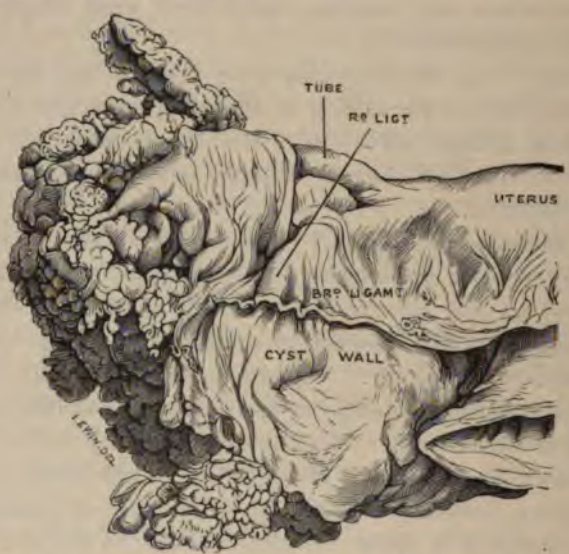

Fig. 267. Ruptured papillomatous cyst (right half of the specimen). (*Museum, Royal College of Surgeons.*)

An important pathological and clinical fact connected with these cysts is that when they rupture, the fluid they contain is scattered broadcast over the peritoneum.

When there is general epithelial infection of the peritoneum, the warts are most numerous on the serous membrane lining the recto-vaginal pouch and on the omentum.

It has been clearly established that when the abdomen has been opened for the removal of a papillomatous cyst the peritoneum has been found studded with warts. A few years later the abdomen has been reopened and all the peritoneal warts have disappeared. Thus they behave like warts on the

skin. This fact must be borne in mind, or the operator will hastily assume the disease to be malignant when he finds general peritoneal infection. The disappearance of peritoneal warts after removal of the primary tumour is an interesting fact, and may be probably explained in this way :—The life of multiple warts is often very transient, and this is probably the case with peritoneal papillomata : but as long as the seed supply continues new warts spring up, last for a time, and die, to be succeeded in their turn by a new crop. When the source of epithelium is removed by operation, the warts then existing

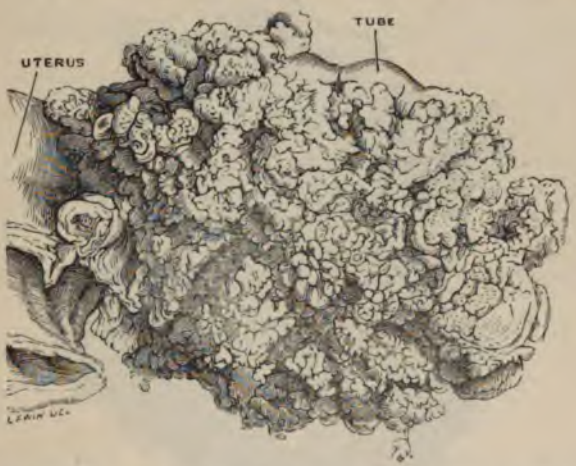

Fig. 268.—Ruptured papillomatous cyst (left half of the specimen). (*Museum, Royal College of Surgeons.*)

die, and the crop of warts is not renewed. Exceptionally these papillomatous cysts rupture into the connective tissue of the mesometrium, and I have seen them clustering around the urachus as high as the umbilicus.

The dispersal of germinating cells from these emancipated warts is, no doubt, largely effected by movements of the intestines, in addition to the sudden inundation of the belly when the cyst bursts ; but there is an additional complication which not only favours epithelial infection but is in itself inimical to life—namely, **hydroperitoneum.** This condition differs from ascites in the circumstance that it is not the consequence of hepatic, cardiac, or renal disease, but is due to

irritation of the peritoneum by secondary nodules of cancer, warts, tubal disease, and the like. Hydroperitoneum is a constant concomitant of the bursting of a papillomatous cyst. When the cyst is removed the exudation ceases.

One of the most remarkable examples of hydroperitoneum associated with papillomatous cysts on record is that described by Dr. Pye-Smith.* In this case a woman was tapped for hydroperitoneum between August, 1884, and April, 1894, 299 times. On readmission for the 300th tapping she died.

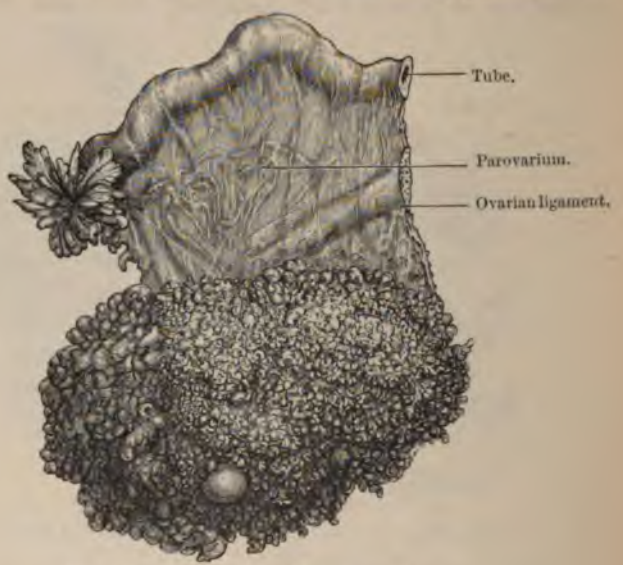

Fig 269.—Ruptured papillomatous cyst.

At the *post-mortem* examination a papillomatous cyst was found in connection with each ovary. The peritoneum was beset with warts.

Parovarian Cysts.—The parovarium consists of a series of narrow tubules situated between the layers of the mesosalpinx and closely associated with the paroöphoron. It is easily seen, when the mesosalpinx is stretched and held between the eye and the light, as a series of tubules radiating from the ovary to join a longitudinal tubule situated at a right angle to them. Although the tubules converge as they approach the

* *Trans. Path. Soc.*, vol. xliv. p. 111.

ovary, nevertheless they remain distinct. Each tubule ends blindly, and is usually lined with epithelium. In form, size, and disposition they resemble the arrangement of the vasa efferentia of the testis. This resemblance was observed by Rosenmüller, who discovered this structure in 1801 whilst prosecuting anatomical researches at Erlangen. The parovarium is homologous with the vasa efferentia and epididymis of the testis, for these tubular structures in the male and female are the persistent excretory ducts of the Wolffian body (mesonephros). In the female they are vestigial, whereas in the male they are functional.

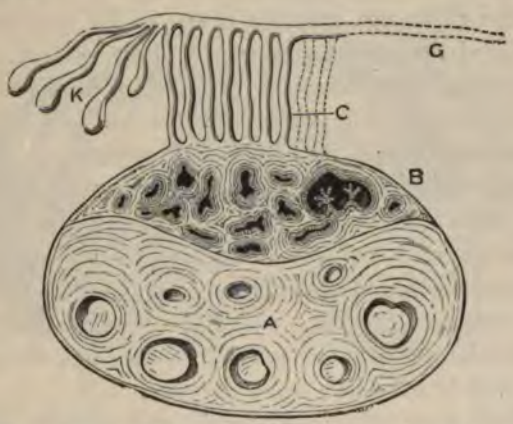

Fig. 270.—Parovarium (semi-diagrammatic). A, oöphoron; B, paroöphoron; K, Kobelt's tubes; C, vertical tubes of the parovarium; G, Gärtner's duct.

When present in its typical condition, the parovarium consists of three parts (Fig. 270): an outer series of tubules, free at one extremity, known as Kobelt's tubes; an inner set, termed the vertical tubules; and a larger tube running at right angles to the vertical tubules which may occasionally be traced downwards to the vagina. This is Gärtner's duct; it corresponds to the vas deferens in the male. The parovarium contains, as a rule, twelve tubules; sometimes as many as seventeen may be counted, and in other specimens as few as five.

The cysts that arise in the parovarium are of two kinds: The more frequent ones are small pedunculated cysts connected with Kobelt's tubes. They rarely exceed a pea in size, and do not call for much comment, as they are of no clinical importance.

They need to be mentioned, however, because they are often confounded with the hydatid of Morgagni. Occasionally some of the vertical tubules will break loose and form pedunculated cysts. Should the cyst rupture, it may be converted into a tuft of fimbriæ. The more important cysts are sessile, and remain between the layers of the mesosalpinx. In the early stages it is easy to demonstrate the relation of these cysts to the parovarium. When such a cyst enlarges, it burrows between the layers of the mesosalpinx and makes its way towards the Fallopian tube, which becomes stretched, because the abdominal end of the tube is fastened firmly to the ovary by the tubo-ovarian ligament, and the ovary in its turn is attached to the side of the uterus. In a very large cyst the Fallopian tube becomes greatly elongated, and attains a length of 40 cm. In spite of this extreme stretching, the lumen of the tube is rarely obstructed, and its abdominal ostium can usually be found, the fimbriæ being indicated by a few wattle-like processes.

Small cysts are, as a rule, transparent, but when they exceed the size of a cocoanut, this transparency is lost, and the walls become thick and tough. Small parovarian cysts are lined with columnar epithelium, which is sometimes ciliated; in cysts of moderate size the epithelium becomes stratified, and in large cysts it atrophies from pressure.

The fluid they contain is limpid and slightly opalescent; specific gravity 1002 to 1007, reaction slightly alkaline. A substance, precipitated by alcohol, is present in large quantity.

In big cysts the fluid is often turbid and may contain cholesterine. When parovarian cysts rupture into the cœlom (peritoneal cavity) the fluid is quickly absorbed and excreted by the kidneys.

The points which enable a large parovarian cyst to be distinguished from an oöphoronic cyst are these:—

1. The peritoneal coat is easily stripped off.
2. The ovary is usually found at the side of the cyst.
3. The cyst is usually unilocular.
4. The Fallopian tube is stretched over the cyst, but does not communicate with it (Fig. 271).
5. The specific gravity of the fluid does not exceed 1010, and may be much lower.

6. In some specimens the tissue of the mesosalpinx is greatly thickened.

It was formerly believed that cysts originating in the parovarium rarely exceeded the size of an orange, but in 1873 Dr. Bantock * demonstrated that parovarian cysts may attain very large proportions, and be capable of containing several litres of fluid. The largest parovarian cyst which has yet come under my care contained 20 litres of turbid fluid.

The age at which parovarian cysts occur is of some interest. It has already been mentioned that cysts of the oöphoron are encountered at any period, from fœtal life up to extreme

Fig. 271.—Cyst of the parovarium, showing its relation to ovary and tube. A, Oöphoron; B, paroöphoron; F, Fallopian tube. (⅔ *nat. size.*)

old age. The occurrence of a parovarian cyst has not, as far as I am aware, been recorded in an individual before the age of sixteen; many undoubted cases have been observed at seventeen, eighteen, and nineteen, the cysts being large enough to rise above the pubes. Before sixteen the parovarium appears to be quiescent, but on the advent of puberty it seems to undergo great stimulation; a very large proportion of cysts, generically classed as ovarian, removed between the ages of seventeen and twenty-five, arise from it.

It is difficult to come to any satisfactory conclusion as to the relative frequency of parovarian cysts as compared with cysts of the oöphoron and paroöphoron until operators become

* "On the Pathology of certain so-called Unilocular Ovarian Cysts," in *Trans. Obstet. Soc. Lond.*, vol. xv. 105.

less casual in their use of the term "ovarian cyst." With our present knowledge they form about 10 per cent.

Parovarian cysts do not often contract adhesions, even when

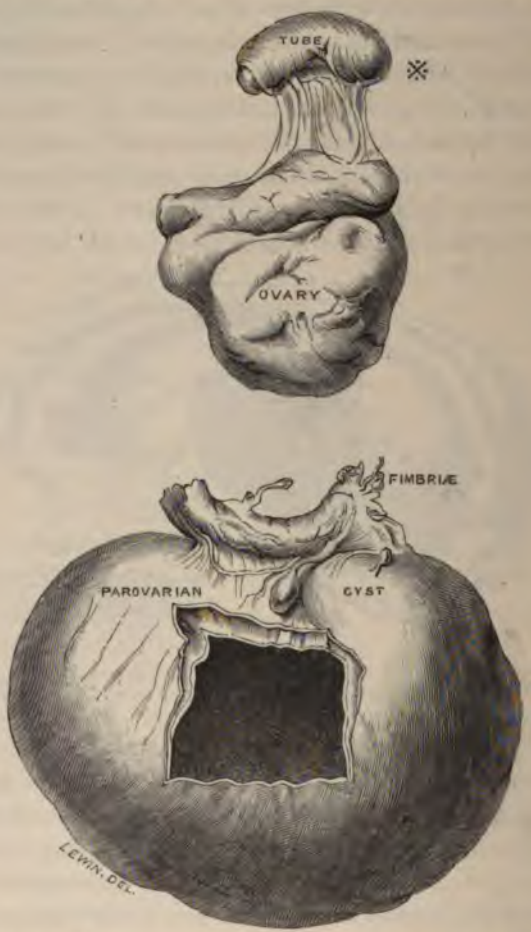

Fig. 272.—Ovary and stump of a Fallopian tube, left after axial rotation, ending in complete detachment of a parovarian cyst.
* The rounded stump of the tube at the point of detachment.

they suppurate. The layers of the mesometrium stretched over them occasionally contain an unusually large proportion of unstriped muscle-fibre; they rarely suppurate. Like other forms of cysts and tumours related to the ovary, they are liable to axial rotation and complete detachment (Fig. 272.)

Epithelium.—It was formerly the custom to believe in the immutability of epithelium; hence many writers have relied upon the characters of the epithelium lining of cysts as indicative of their origin. Mutation of epithelium has been proved so often that it is needless to do more than mention that in some parovarian cysts ciliated cells will be found; in others simple cubical; and in many large cysts no epithelium can be detected. Undoubted parovarian cysts sometimes present low, flat-topped warts.

Gärtnerian Cysts.—A larger experience of ovarian and parovarian cysts has served to convince me that many papillomatous cysts have an origin independent of the paroöphoron. A careful study of the relations of these cysts shows that many

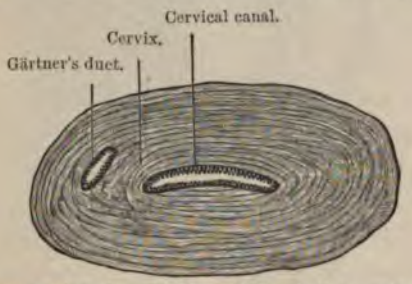

Fig 273.—Transverse section through the middle of the cervix of a fœtal uterus with persistent Gärtner's duct. Slightly magnified. (*Rieder.*)

of them burrow deeply by the side of the uterus, and even extend along the wall of the vagina.*

It is known that Gärtner's duct occasionally persists in women, and after leaving the parovarium it traverses the layers of the mesometrium and runs down the side of the uterus to reach the vagina. As it approaches the cervix, it is often embedded in its tissue (Fig. 273).

Evidence is slowly accumulating in support of the opinion that some papillomatous cysts of the mesometrium, especially those which burrow deeply by the side of the uterus, arise in persistent portions of Gärtner's duct, near its termination. Cysts arising in the lowest segment of this duct occasionally bulge into the vagina.

The cystic tendencies of Gärtner's duct can easily be studied

* Amand Routh gives an admirable summary of the literature of Gärtnerian cysts in *Trans. Obstet. Soc.*, vol. xxxvi. 152.

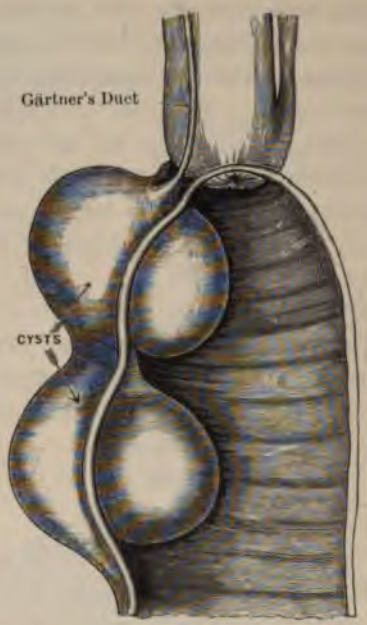

Fig. 274.—Uterine segment of a cow's vagina, showing two large cysts developed in the terminal segment of Gärtner's duct.

in cows. In these animals the ducts are sometimes as large as crow-quills. Usually they become gradually lost on the

Fig. 275.—A, Ovary; P, parovarium; F, Fallopian tube; and B, mesosalpinx. (*Nat. size.*) Two small papillomatous cysts are seen in relation with the tubo-ovarian ligament.

sides of the uterus, but occasionally they may be traced to the vagina (Fig. 274).

Warty Ov ries.—There is a variety of papillomatous cyst arising in the mesosalpinx independently of the ovary or Gärtner's duct. These cysts are usually found near the junction of the tubo-ovarian ligament with the ovary, and burrow between the layers of the mesosalpinx (Fig. 275).

When fresh they are transparent, and resemble incipient parovarian cysts, but they are unconnected with this structure. The most striking feature of these cysts is the almost invariable presence of a tuft of warts. It is difficult to be sure of the presence or absence of these warts without opening the cyst. The warts are composed of very dense fibrous tissue. In this respect they differ in a striking manner from the soft vascular processes found in typical papillomatous cysts. Wart-containing cysts also occur on the free surface of the ovary.

presence of fat; sometimes spermatozoa are present, or the fluid may be blood-stained. In size these cysts vary greatly. As a rule they do not exceed the dimensions of an egg, and often are much smaller.

An encysted hydrocele must not be confounded with a cyst arising in an unobliterated funicular process.

In addition to the sessile form of encysted hydrocele of the testis there is a pedunculated variety which is usually described as a supernumerary hydatid of Morgagni. These cysts rarely exceed a cherry in size, and arise in Kobelt's tubules. As a rule only one cyst is present, but two or three are not uncommon. Sometimes they will, like the hydatid of Morgagni, project into the cavity of the tunica vaginalis.

2. **General Cystic Disease of the Testis.**—The tumours of the testis that will be described under this heading are those to which Astley Cooper * gave the name of "hydatid disease." They were made the subject of careful study by Curling,† who designated the condition "general cystic disease of the testis."

The morphology of these tumours has been investigated independently by Eve ‡ and myself.§ We find good evidence that they originate in the remnant of the mesonephros (Wolffian body) which lies between the globus major of the epididymis and the testis proper. This remnant of the mesonephros is known as the paradidymis (Fig. 276). It often presents, as has already been mentioned, a distinctly glandular structure.

These tumours in their typical condition are made up of large numbers of cystic spaces, which vary greatly in size; some are no larger than rape-seed, others may attain the size of a cob-nut. Many are distinctly tubular, and the cysts may communicate with each other. The loculi are lined with regular columnar, cubical, or stratified epithelium, and intracystic papillomata are not uncommon. The connective tissue framework of the tumour consists mainly of simple fibrous tissue, but it may be so abundant as to form the bulk of the tumour,

* "Diseases of the Testis," 1830.
† *Med.-Chir. Trans.*, vol. xxxvi. 449.
‡ *Trans. Path. Soc.*, vol. xxxviii. 201.
§ *Lancet*, 1887, vol. i. 254.

the cysts being sparse. In some of the specimens, especially those met with in infants, plain muscle fibre has been detected.

Many of these tumours have been described as cystic sarcomata, cystic fibromata, myxomata, etc.—all unfortunate names. In size they vary greatly; specimens are known as large as melons. The best examples for investigation are those which do not exceed the size of an egg. In these the relation of the tumour to the testicular structures is very significant. As the tumour increases in size it flattens

Fig. 277.—So-called general cystic disease of the testis.
(*Museum, St. Mary's Hospital.*)

the body of the testicle until this is reduced to a narrow stratum intervening between the tunica vaginalis and the adenoma (Fig. 277). In the large specimens it is often difficult to detect any remnant of the testicle.

Treatment.—The most satisfactory method of treating **encysted hydrocele of the testis** is to expose the cyst through an incision in the scrotum, tap the cyst, and then enucleate its walls, taking care not to damage the testis or the vas deferens. The cavity is then drained and allowed to close by granulations.

Such procedures as tapping and the injection of irritating fluid are troublesome, inconvenient, and often end in disappointment.

The appropriate treatment for "general cystic disease of the testis" is castration.

Cysts of Müller's Ducts.—In many vertebrata the eggs, after their escape from the ovary, are conveyed to the exterior by means of a muscular conduit known as the oviduct. The general disposition of these ducts, for there are usually two, may be gathered from an examination of a female frog or toad. The ducts extend from the cloaca posteriorly to the roots of the lungs anteriorly; they are supported on the dorsal wall of the abdomen by means of a delicate fold of peritoneum, and each duct communicates with the peritoneal cavity by a dilated orifice known as the infundibulum. In the breeding season the ducts become greatly enlarged and convoluted, resembling coils of small intestine.

Normally, oviducts are present in the female only. It is, however, remarkable that the embryos of those forms in which the sexes are distinct in the adult condition have the rudiments of the sexual organs peculiar to the male and female; they are hermaphrodite. As development continues one set of organs usually attains a functional condition; the other atrophies more or less completely.

The distinguishing features of the internal sexual organs of a female frog are two ovaries and two oviducts. In the male the oviducts are usually absent. It is, however, an interesting fact that in many male frogs the oviducts may be detected as thin, delicate threads ascending in the peritoneum from the structures called vesiculæ seminales to the roots of the lungs. Sometimes the ducts are of large size, almost equal to the oviducts in the female. Persistent Müllerian ducts are more common in male toads than in frogs. Often they are associated with the malformation of the genital gland known as an ovo-testis; but they are fairly frequent even when the genital gland is a typical testis. No one can doubt that an oviduct in a male frog or toad is functionless, and it is not uncommon to meet with small dilatations or cysts lying in the track of, and arising from, the functionless oviducts. Persistent Müller's ducts are by no means confined to batrachians, but they have been observed in fish, lizards, stallions, birds, and men.

Good examples of cysts arising in functionless ducts are sometimes met with in birds. In birds, as in frogs and toads, the eggs are conveyed to the exterior by means of an oviduct, but in the case of birds the duct is functional on the left side only. Each chick has two oviducts, but the right ovary and duct, from some unexplained cause, atrophies, leaving, as a rule, a small, narrow tubule surmounted by a lobule of fat. This remnant of the right duct is very apt to dilate and form a cyst. When the stump of the duct is longer than usual it will sometimes become unequally dilated and form a chaplet of cysts.

CHAPTER LV.

HYDROCELE.

THE name **hydrocele** is applied to several different kinds of cystic tumours, and as the name is so deeply rooted in surgical literature it would be very inconvenient to attempt to discard it. In this work the term will be restricted to *cysts due to an excessive accumulation of fluid in a diverticulum or pouch of the peritoneum*, such as :—(1) Hydrocele of the tunica vaginalis ; (2) hydrocele of the canal of Nuck ; (3) ovarian hydrocele ; (4) omental hydrocele.

(1) **Hydrocele of the Tunica Vaginalis.**—Each testicle is preceded in its descent by a diverticulum of the parietal peritoneum, which enters the scrotum by way of the inguinal canal. As the testicle descends behind this diverticulum, or **funicular pouch**, as it is termed, it invaginates the membrane in such a way as to invest the anterior two-thirds of its surface with a double layer of peritoneum. When the testicle first gains the scrotum the funicular pouch is in free communication with the general peritoneal cavity. It is a remarkable fact that in almost every mammal, male and female, save man, this relation of the funicular pouch to the peritoneal cavity persists throughout life.

In exceptional instances this communication persists even in man, but in him it is distinctly abnormal. Normally the peritoneum becomes adherent immediately above the testis, this adhesion dividing the pouch into two parts ; that in relation to the testis persists throughout life as the **tunica vaginalis**, whilst that above the testis usually undergoes obliteration in the course of the early months of infant life. Occasionally occlusion of this pouch is delayed for some years, and in rarer cases it may persist throughout life.

Normally the only portion of the funicular pouch that persists throughout life is that which is in immediate relation

with the testis—the tunica vaginalis—and when this becomes distended with fluid it is termed *hydrocele* of the *tunica vaginalis.* When containing blood it is called *hæmatocele* of the *tunica vaginalis.* Should the whole of the funicular pouch persist and become occupied by fluid, it is called a *congenital hydrocele:* Frequently the tunica vaginalis is formed as usual, but the portion intervening between it and the internal abdominal ring persists and may become distended with fluid. This is known as *funicular hydrocele ;* it is often called *encysted hydrocele of the cord.*

Hydrocele of the tunica vaginalis appears in two forms, **acute** and **chronic.** Acute hydrocele is due to inflammatory effusion into the sac, either as the result of injury or secondary to acute orchitis. This is the rarer form, and, as a rule, the fluid is absorbed and the parts return to their normal condition as the inflammatory trouble that caused it subsides. Exceptionally a hydrocele appearing in this way persists.

The common form of hydrocele is a passive effusion into the tunica vaginalis, usually appearing about the middle period of life, and in most cases without any exciting cause, either local or constitutional. It is very common in men who have lived in the tropics. Hydrocele is met with in extreme old age, and is occasionally bilateral.

The amount of fluid in hydroceles varies greatly ; in some it amounts to one or two ounces, whilst in others it measures a pint or more.* The fluid is limpid, of a straw colour, with a sp. gr. of about 1015. It contains a large amount of albumen and the substance known as fibrinogen. When allowed to stand after withdrawal it spontaneously coagulates:

When the fluid is removed by tapping it usually quickly reaccumulates, so that the amount of fluid furnished by a large hydrocele in the course of a few years is often considerable: Even the withdrawal of large quantities of fluid from a hydrocele at frequent intervals seems to exercise no evil influence upon the health of the patient.

* Erichsen relates that Gibbon, the historian, had a hydrocele which Cline tapped and from which he drew off six quarts of fluid. W. Horrocks has looked into the records, and ascertained that the scrotal trouble was an irreducible hernia with a large quantity of fluid in the sac.—*Lancet,* 1901, vol. i. 1356.

The presence of a large quantity of fluid in the tunica vaginalis leads to changes, not only in the membrane itself but also in the testicle, for this gland, pressed upon by the fluid, will in course of time atrophy. In most specimens the testis is situated in the lower and back part of the sac, as in Fig. 278. In those cases in which the testis is inverted the hydrocele projects posteriorly, and the testis lies in front and at the upper part of the sac.

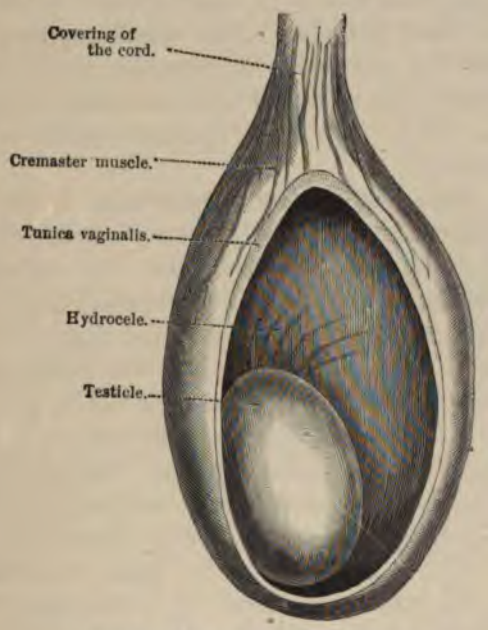

Fig. 278.—Hydrocele of the tunica vaginalis testis.

In addition to atrophy of the testis, the diminution in the size of its secreting tissue may be masked by great thickening of its tunica albuginea, a condition termed periorchitis, which is by no means infrequent in old hydroceles, especially those which have been repeatedly tapped. This thickening, or sclerosis, manifested by the immediate covering of the testis is often seen in the tunica vaginalis throughout its whole extent, and in some cases this membrane may be as thick and almost as hard as pasteboard. The hardness of these thick sacs is sometimes increased by calcareous matter. When such sacs

are dissected out they are not unlike a cocoanut in shape, size, and even in consistence. Secondary changes of this kind may be due to repeated attacks of inflammation set up by tapping. A little inflammation following this slight operation may be useful, as it may induce adhesion of the serous surfaces and lead to obliteration of the sac. This, however, is rarely complete. In some cases bands of adhesions or broad septa form, and produce a loculated cyst. In other cases suppuration ensues, which may lead to serious consequences. Occasionally loose bodies are found in the sac of the tunica vaginalis, often associated with, but sometimes independent of, hydroceles. Some are no larger than the head of a pin, others attain the dimensions of a cherry. The larger examples consist of dense, structureless laminæ.

The variety known as **congenital hydrocele** is due to the persistence of the funicular pouch throughout its whole extent. In this form we meet with two conditions—viz. the sac may retain its connection with the general peritoneal cavity, or it may be occluded at the internal abdominal ring. When the orifice of the sac is not occluded the fluid that accumulates in the sac gravitates into it from the peritoneal cavity during the day; but during the night, when the body has been in a recumbent position for a prolonged period, the fluid returns wholly or in part into the abdomen, so that in the morning the scrotal swelling will be found greatly diminished, if not entirely gone. As the day goes on the fluid will slowly reaccumulate in the tunica vaginalis. This alteration in size of the swelling is characteristic of this variety of hydrocele; but it is sometimes simulated by, and mistaken for, inguinal hernia.

When the funicular pouch is shut off at the inguinal canal and becomes distended with fluid it is sometimes difficult to distinguish it, except by dissection, from a hydrocele of the tunica vaginalis.

Congenital hydrocele is most commonly met with in children, and is very rare after the fifteenth year. An accumulation of fluid is not uncommon in the funicular pouch of infants, and it often disappears spontaneously.

Funicular hydrocele is another variety, frequently referred to as encysted hydrocele of the cord. It is due to effusion

of fluid into that portion of the funicular pouch which intervenes between the tunica vaginalis and the internal abdominal ring, and which, under normal conditions, suffers obliteration. This form of hydrocele is very frequent in infants, and presents itself as an ovoid tumour lying between the testis and the inguinal canal. Although it possesses very characteristic features, this variety of hydrocele is frequently confounded with hernia of the intestines into the funicular pouch. Funicular hydroceles occasionally occur in young adults.

It should be borne in mind that an inguinal hernia may be associated with a hydrocele, and it happens occasionally that the neck of a hernial sac may become so narrowed that gut and omentum no longer pass through it. A pouch of this kind would, if distended with fluid, simulate a hydrocele of the tunica vaginalis. In exceptional cases **hydrocele of a hernial sac** accompanies ascites. In several instances collections of ascitic fluid have been evacuated through a trocar inserted into the sac of an old hernia. "Hydrocele of a hernial sac" is common in the femoral variety of hernia.

(2) **Hydrocele of the Canal of Nuck.**—In female fœtuses a diverticulum of the parietal peritoneum descends into the inguinal canal, and is in all respects identical with the funicular pouch in the male; it is known as the canal of Nuck. Usually this pouch becomes obliterated, but it is by no means rare to find it patent in young women. Occasionally the canal becomes distended with fluid and forms a cyst occupying the inguinal canal, and is then termed a hydrocele of the canal of Nuck.

Treatment of Hydroceles.—The routine practice of treating *hydrocele of the tunica vaginalis* is to draw off the fluid by means of a narrow trocar and cannula. The cyst almost invariably refills, necessitating repeated tapping. The simplest method is to open the sac and after inverting the tunica vaginalis return it with the testis into the scrotum. *Hydrocele of the canal of Nuck* should be dissected out and the neck of the sac ligatured. The same method answers well for *hydrocele of a hernial sac*, whether inguinal or femoral.

(3) **Ovarian Hydrocele.**—The ovaries in rats and mice are contained within a serous sac derived from the peritoneum. The abdominal ostium of the Fallopian tube communicates

with the ovarian sac; hence when the ova escape from the ovary they enter the Fallopian tube and gain the uterus without entering the general peritoneal cavity, as is the case with the human ovum. This serous sac investment of the ovary reminds us of the tunica vaginalis of the testicle, and like it the ovarian sac is liable to become distended with serous fluid, a condition to which I have applied the name **ovarian hydrocele.** Cysts of this kind in rats may attain a large size, and their general features are well illustrated in Fig. 279. The Fallopian tube in the rat is coiled up between the cornu of the

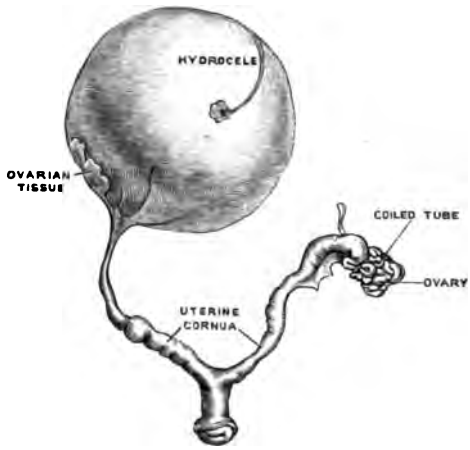

Fig. 279.—Ovarian hydrocele in a rat. (*Nat. size.*)

uterus and the ovarian sac, but when the sac becomes distended it uncoils the tube and stretches it around the circumference of the cyst; the tubal ostium opens on the inner wall of the hydrocele, and the adjacent section of the tube is, as a rule, dilated. The ovary, when the cyst is small, projects into the cyst, but in very large hydroceles it atrophies from pressure. As the ovarian sac is in communication with the uterine cornu it sometimes becomes implicated in septic conditions of the uterus, and the sac is sometimes found distended with pus.

No other mammal normally possesses such a complete ovarian sac as do rats and mice, but many have a pouch that communicates with the general peritoneal cavity by a small aperture; in others the pouch has a narrow slit; whilst in

women the ovary, in its virgin condition, lies in a shallow recess. Notwithstanding the fact that the mouth of the ovarian pouch is in women very wide, there is good reason to believe that its edges may unite when the pouch is abnormally deep and convert it into a closed sac, which subsequently becomes a hydrocele. Ovarian hydroceles occur in the human female and sometimes attain a large size. They present the following anatomical features :—

The sac projects from, and is intimately connected with, the posterior layer of the broad ligament. In small hydroceles the ovary projects into the cavity of the cyst, but in large examples it is atrophied. The Fallopian tube lies on the crown of the cyst, its outer half is dilated and tortuous ; the ostium opens into the hydrocele by a large circular or elliptical aperture. Ridges of mucous membrane issue from the interior of the tube and pass on to the walls of the hydrocele in a radiating fashion. When the specimens are examined in a fresh state it is not rare to find the aperture fringed with tubal fimbriæ. The general appearance of a typical ovarian hydrocele suggests "a retort with a convoluted delivery-tube" (Griffith).

Besides finding them in rats and women, I have detected ovarian hydrocele in a guinea-pig, and Schneidemühl has observed it in the mare.

The cysts liable to be confounded with ovarian hydroceles are parovarian cysts, small paroöphoronic cysts, and large hydrosalpinges. A parovarian or paroöphoronic cyst is distinguished from a hydrocele of the ovary by the fact that the Fallopian tube is stretched across the cyst but does not communicate with its cavity.

In the case of a large hydrosalpinx the ampulla is often so flexed on the tube as to produce a retort-shaped cyst ; but there are no fringes or ridges of the mucous membrane at the orifice of communication, and the ovary lies free of the cyst wall and is often lodged in the flexure of the tube.

Ovarian hydroceles must not be confounded with tubo-ovarian cysts and abscesses the result of salpingitis.

(4) **Omental Hydrocele.**—Under normal conditions the lesser cavity of the peritoneum extends into the great omentum ; occasionally this space becomes distended with fluid, and its

communication with the upper area of the lesser cavity becoming shut off, the omental space is isolated and converted into a cyst. Similar cysts arise in the transverse mesocolon and I have encountered them in the mesocæcum and mesosigmoid. Omental hydroceles are sometimes so big as to simulate ovarian tumours.*

Chyle Cysts.—This is perhaps the best place to mention a rare but interesting lesion known as chyle cyst of the mesentery. The sac of the cyst appears to be formed of the separated layers of the mesentery, the interspace being occupied by fluid identical in its physical and chemical characters with chyle. In their anatomical features these cysts are similar to omental hydroceles, and, like them, are occasionally big enough to simulate clinically ovarian cysts.†

There is a variety of cyst containing chyle which is met with in infants and children. Such cysts are closely connected with the mesenteric border of the intestine and push their way between the layers of the mesentery. There is reason to believe that they arise as abstrictions of the intestines during fœtal life. This variety has been particularly studied by Eve,‡ Fawcett,§ and Dowd.|| These cysts are important, for they have caused fatal intestinal obstruction.

* Doran, *Trans. Obstet. Soc.*, vol. xxiii. 164.

† Rasch, *ibid.*, vol. xxxi. 311. See also Bramann, Langenbeck's *Arch. für klin. Chir.*, bd. xxxv., s. 201; Mendes de Leon, *Am. Journal of Obstet.*, vol. xxiv., p. 168; Fetherston, *Australian Med. Journal*, 1890, p. 475.

‡ *Med.-Chir. Trans.*, vol. lxxxi. 51.

§ *Trans. Path. Soc.*, vol. liii. 406.

|| "Annals of Surgery," vol. xxxii. 515.

CHAPTER LVI.

PSEUDO-CYSTS—DIVERTICULA AND BURSÆ.

THE term **diverticulum** is used to denote hernia or protrusion of the lining membrane of a cavity through a defective spot in its walls. Such protrusions occur in connection with the œsophagus and intestines, the bladder and trachea; also in relation with joints and tendon-sheaths forming synovial cysts and ganglia; and in blood-vessels forming sacculated aneurisms and varices.

Intestinal Diverticula.—These are hernial protrusions of the mucous membrane of the bowel through interspaces in the muscular coat. Structurally they consist of mucous membrane with a covering of peritoneum. Sometimes a few strands of muscle fibre can be detected stretched across the pouch.

Frequently diverticula occur in multiples; as many as two hundred have been found in one case. These pouches occur in all parts of the intestine, but are most frequent in the colon, and especially about the sigmoid flexure. In the small intestine they usually occur along the line of the attachment of the mesentery. In the colon they are found about the attachment of the appendices epiploicæ, and may even project into them.

In dimensions diverticula vary greatly—some are as small as peas, others as large as oranges. When the pouches are numerous, as a rule they are small; when few in number, or solitary, they may be large. Intestinal diverticula are common in old persons, but they rarely lead to serious consequences.

Some writers describe diverticula of the intestines as consisting of two varieties, *true* and *false*. According to this arrangement a persistent vitello-intestinal duct would be called a true diverticulum.

Vesical Diverticula.—Hernial protrusions of the mucous membrane of the bladder between the fasciculi of the muscular

coat are of frequent occurrence. The cause of the protrusion is impediment to the free flow of urine: the obstruction may be seated in the urethra or at the neck of the bladder. Under such conditions there may be several diverticula; the bladder is then said to be sacculated. Sometimes there is only one saccule, and this may attain a large size. Vesical diverticula usually communicate with the cavity of the bladder by large orifices. A sacculus extending into the suspensory ligament of the bladder must not be confounded with a urachus cyst.

Sacculated bladders, apart from the cause that produces the sacculus, do not often give rise to trouble. Calculi are sometimes found within them, and in cases where the outflow of urine is seriously obstructed the walls of a sacculus will sometimes yield and allow the urine to extravasate into the surrounding loose connective tissue.*

As impediments to the free escape of urine from the bladder occur more frequently in men than in women, it naturally follows that sacculated bladders are more common in men. Nevertheless, vesical diverticula of large size are occasionally found in women, and in exceptional cases have caused death.†

Pharyngeal Diverticula (*Pharyngoceles*).—Localised dilatations of the pharynx are of three kinds:—

Abnormal persistence and distension of certain pouches which, as a rule, exist in the embryo only—*e.g.* the pouch of Rathké and the branchial clefts.‡

Pouching of the pharyngeal wall at its junction with the œsophagus.

Protrusions (herniæ) of the mucous membrane lining Rosenmüller's fossa.

When the pouch of Rathké persists it may dilate and form a cyst in the pharynx near the junction of its posterior wall with the roof. Such cysts have been known to attain the dimensions of a ripe cherry.

Pharyngoceles.—In order to appreciate the nature of at least one form of pharyngeal pouch it will be necessary to take

* For an interesting account of the relation of diverticula of the bladder to extravasation of urine, *cf.* Lane, *Guy's Hospital Reports*, 1885.

† Hale White, *Trans. Path. Soc.*, vol. xxxiv. 146.

‡ Pouches of the naso-pharynx have been described in detail by Kostanecki, Virchow's *Arch.*, bd. cxvii. s. 108.

into consideration an interesting congenital defect to which the pharynx is liable.

It occasionally happens that children are born with what is known as an **imperforate pharynx**, that is, instead of the pharynx and œsophagus forming a continuous tube, the pharynx terminates as a cul-de-sac near the level of the cricoid cartilage.

In such cases the upper end of the œsophagus terminates by opening into the trachea through its posterior wall. The situation of the œsophago-tracheal fistula varies in different

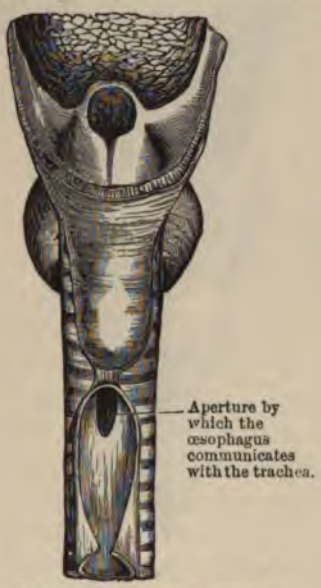

Fig. 280.—Imperforate pharynx.

specimens; sometimes it is as high as the third tracheal semi-ring, or it may be as low as the bifurcation of the trachea, and in at least one case it opened into the left bronchus. In most examples of imperforate larynx the œsophagus is connected with the lower end of the pharynx by a fibrous band, which indicates that the two structures were originally continuous, but that their continuity has been disturbed by secondary changes (Fig. 280).

The constant association of an œsophago-tracheal fistula and imperforate pharynx indicates some relation between the two conditions. The explanation which at once suggests itself

is, that it may be due to some influence exercised by the pulmonary diverticulum which leaves that portion of the embryonic fore-gut ultimately represented by the œsophagus.*

It is necessary to describe congenital imperfections at the junction of the pharynx and œsophagus, because it is at this point that pouches are apt to form. A typical example of a pharyngeal pouch, or **pharyngocele,** is shown in Fig. 281.

Fig. 281.—Pharyngeal diverticulum. (*After Worthington.*)

The case is very carefully described by Worthington.† The parts were obtained from a man sixty-nine years of age. There was a stricture of the œsophagus at the level of the cricoid cartilage that would admit merely a urethral bougie. This obstruction ultimately led to the death of the patient. He could swallow food and retain it for a time; it would then regurgitate. At the *post-mortem* dissection the pouch was detected; it was in shape like the finger of a glove, and had a

* This subject is handled with remarkable acumen by Shattock, *Trans. Path. Soc.*, vol. xli. 87.

† *Med.-Chir. Trans.*, vol. xxx. 199.

depth of 9 cm. and a circumference of 6 cm. The mucous membrane at the seat of the stricture was quite healthy. About two-thirds of the pouch was covered with muscle derived from the inferior constrictor.

An examination of pharyngeal pouches such as exist in museums would lead the observer to believe that the orifice of communication between the pharynx and the pouch was circular; but there is good reason to believe that it assumes a slit-like form even when the pouch is full of food.

So far as our knowledge at present extends in regard to this variety of pharyngocele, it would appear that such pouches arise in all probability as congenital defects, but it is important to remember that they rarely cause inconvenience until late in life. Thus Ludlow's * patient was sixty; Worthington's, sixty-nine; Chavasse's,† forty-nine; and Butlin's,‡ forty-seven. It is necessary to point out that a pharyngocele of the character represented in Fig. 281 arises in a different manner from that depicted in Fig. 209 (p. 373); the latter is probably due to a persistent branchial cleft.

Treatment.—Pharyngoceles are likely to be much more carefully studied in the future than they have been in the past, for the condition has on more than one occasion been correctly diagnosed, and the pouch removed through an incision in the neck and its slit-like orifice of communication with the pharynx occluded by sutures, a manœuvre that has been followed with complete success in the hands of Bergmann § and Butlin.

Œsophageal Diverticula.—Hernial protrusions of the mucous membrane of the œsophagus through the muscular coat are not common. They vary greatly in size. Some are no larger than cherries, others may attain the size of a closed fist. Diverticula arise in any part of the œsophagus; nothing is known as to their cause.

Tracheal Diverticula.—These are small hernial protrusions of the mucous membrane of the trachea; they are uncommon

* "Medical Observations and Inquiries," 1767, vol. iii. 85, pl. v.

† *Trans. Path. Soc.*, xlii. 82.

‡ *Med.-Chir. Trans.*, vol. lxxvi. 269

§ Langenbeck's *Arch*, bd. xliii. s. 1.

and invariably occur near the junction of the trachealis muscle with the cornua of the semi-rings of the trachea. Rokitansky regarded them as dependent on chronic catarrh of the trachea. Gruber, on the other hand, was of opinion that they are retention cysts of the glands in the tracheal mucous membrane; they are of little clinical interest.

The Tracheal Diverticulum of the Emu.—The emu (*Dromæus novæ-hollandiæ*) is normally provided with a tracheal diverticulum of great interest. In this bird there is a natural defect in the front of the trachea, at a spot varying between the fiftieth and sixty-fifth ring. The deficiency may involve six or more rings. In the emu chick the defect is scarcely noticeable, and the extremities of the rings are almost in contact. As the bird grows the tracheal mucous membrane becomes slowly herniated through the opening until it forms a huge sac between the skin of the neck and the trachea. The cyst wall is composed of connective tissue with scattered bundles of striated muscle fibre; its mucous lining is directly continuous with that of the windpipe, and is dotted with the orifices of glands. (Fig. 282.)

The adult emu inflates this sac when it produces the peculiar booming sound which resembles the noise made by blowing across the mouth of a large bottle.

This large tracheal sac may inflame and become distended with mucus. In a specimen which I secured and forwarded for preservation in the museum of the Royal College of Surgeons, London, the sac contained two pints of mucus. The bird was unfortunately drowned in this fluid, for while I was making an attempt to evacuate the contents of the sac the fluid entered the opening in the trachea and suffocated it.

Murie* has written an excellent account of the anatomy of the trachea of the emu. I can confirm his observations, having enjoyed the opportunities of dissecting the adult emu and the emu chick. Concerning the function of this pouch nothing is known.

The Guttural Pouches of the Horse.—In man the pharyngeal orifice of each Eustachian tube opens in relation with a bay or recess termed the fossa of Rossenmüller. In the horse the tubes terminate in a very different manner. When the head is removed at the occipito-atlantal articulation, and the pharynx, with the associated structures, carefully dissected from the muscles on the ventral aspect of the cervical region of the spine, it will be found, as a rule, difficult to avoid cutting into two large sacs separated from the atlas and axis by loose connective tissue. These sacs reach to the base of the skull, extend downwards to the larynx, and send processes to occupy the intervals between the long styloid processes and the mandible. These sacs are the *guttural pouches*; they abut upon, but have no communication with, each other, and occupy the whole of the

* *Proc. Zool. Soc.*, 1867, 405.

naso-pharynx. Each pouch is lined with delicate mucous membrane containing glands and furnished with ciliated epithelium.

The mucous membrane of the guttural pouches is directly continuous with that lining the Eustachian tubes. The pouches themselves appear as large saccular dilatations of the terminal ends of the tubes, and for this reason they are termed by some writers the Eustachian pouches.

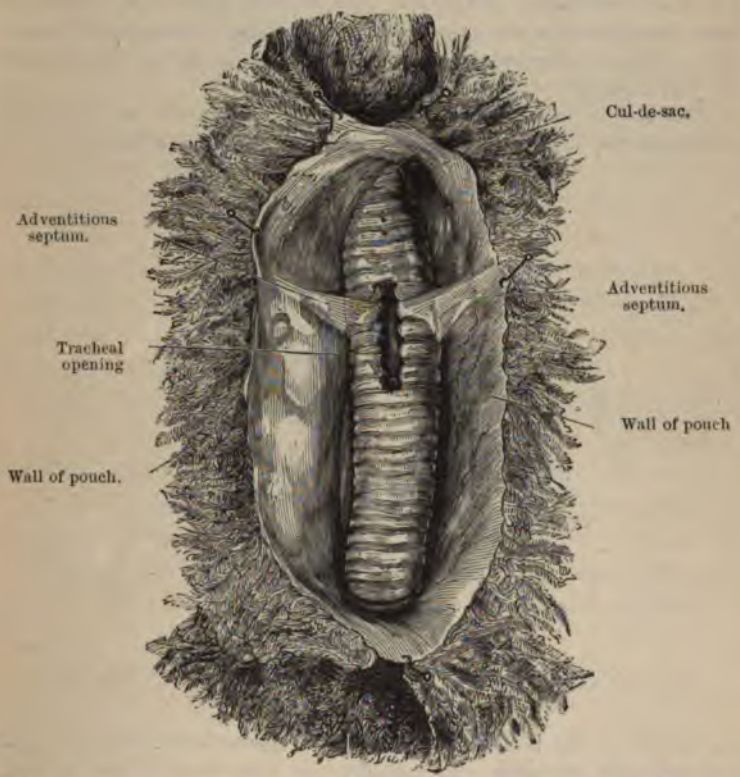

Fig. 282.—Tracheal opening and pouch of an emu. The pouch is cut so as to expose its interior. The surrounding feathers are cut short. (*After Murie.*)

Each pouch opens into the pharynx immediately above the soft palate by a valvular orifice; one side of the valve is formed by the leaf-like termination of the Eustachian tube. Of the functions of these pouches nothing is known. They are often a source of inconvenience to horses, for the mucous membrane is very prone to become inflamed, and the scanty outlet for the secretion leads to its retention and the consequent dilatation of the sacs. When enlarged in this way they may have a capacity of six or more ounces each. The retained secretion may decompose, and the sac become distended with pus, which is discharged at intervals through the

nose; or the pharyngeal orifice may be occluded, and the pouches enlarge to such an extent as to require an incision through the skin of the neck or through the mouth.

Not unfrequently the contents of the pouches become inspissated and formed into concretions. These are of different shapes and sizes, and vary in number from one, two, or three to fifty or even more. Generally they are of an oval shape; not seldom they resemble beans. In consistence these concretions are like cheese, and on section have a laminated appearance. They are composed of mucus and inflammatory products mixed up with inorganic particles (Fig. 283).

The grit in these concretions enables an explanation to be offered concerning the liability of the pouches to attacks of inflammation. As



Fig. 283.—Concretions from the guttural pouches of horses. (*Nat. size.*)

the orifices of the pouches are in direct communication with the nasal passages, dust can easily gain entrance into them when snuffed up with fragments of hay, straw, dried seeds, and other organic and inorganic particles from dusty nose-bags and mangers.

Laryngoceles.—In certain adult monkeys, particularly the chimpanzee (*Simia troglodytes*), the deep cervical fascia is undermined by diverticula from the laryngeal mucous membrane. This large sub-fascial air-chamber communicates with the larynx through the thyro-hyoid membrane; it extends downwards to within 2 cm. of the pre-sternum. Exceptionally it dips into the anterior mediastinum, and laterally into the armpits, the axillary fasciæ forming the lowest limits of the sac.

In one fine chimpanzee I injected this huge reservoir, and found it would hold three pints of injection mass. In the Howling monkeys (*Mycetes*) the air-sac is very large, and the basi-hyal is hollowed to form a resonance chamber. Cervical air-sacs exist in many mammals, and can be inflated at will. They arise as diverticula from the larynx, either from the ventricle or from the pouch of Morgagni in the middle line of the larynx below the epiglottis. In the early stages the lateral pouch resembles the human sacculus laryngis inflated. Gradually the sacs undermine the deep cervical fascia and subsequently coalesce. The air-sac of the adult chimpanzee is formed by fusion of two lateral pouches and a median pouch.

There is great variety in the degree of development of the cervical sacs in different genera and species of mammals.

In 1888 I stated the following reasons for regarding some kinds of congenital cervical cysts in children as examples of laryngeal saccules :—

The congenital nature of the cysts. Repetitions of animal structures of this kind are always congenital.

Their relation to the hyoid bone and larynx. The hollow of the basi-hyal in man represents the large cavity in the basi-hyal of many mammals.

The situations of the cysts beneath the deep cervical fascia and their occasional extension into the axillæ.

CHAPTER LVII.

PSEUDO-CYSTS (*concluded*).

SYNOVIAL CYST, GANGLION, AND BURSA.

Synovial Cysts.—Cysts containing synovia arise in three ways:—

(1) Hernial protrusions of the synovial membranes of joints.

(2) Bursæ in the immediate neighbourhood of joints.

(3) Hernial protrusions of the synovial sheaths of tendons.

Synovial cysts arise in connection with the hip, knee, ankle, shoulder, elbow, and wrist joints. They have been most carefully studied in connection with the knee joint. The cysts form swellings, in some cases as large as an orange, situated near the knee-joint, usually in close relation with the tendons of the semi-membranosus, biceps, or gastrocnemius muscles. Occasionally the cyst will be situated in the calf on the inner side, sometimes as much as 8 cm. below the knee. When the swelling is situated near the joint, pressure will cause it to disappear, the synovia it contains passing into the general cavity of the joint. When the cyst is situated at a distance from the joint, pressure upon it has no effect in diminishing its size, because in many cases the communication between the cyst and the joint cavity is by a very narrow, almost capillary channel.

The cysts arise usually in connection with joints which are chronically diseased, and seem to be common in tubercular joints. It is believed by those who have devoted special attention to these cysts that when the joints become distended with synovia, the internal pressure causes the synovial membrane to protrude through weak spots in the capsule, the diverticula making their way along the intermuscular planes. This mode of origin is similar to that which obtains in the case of sacculated bladders.

It is also certain, for it has been demonstrated by dissection,

that some synovial cysts are due to bursæ normally existing under the adjacent tendons becoming abnormally large and communicating with the joint cavity in consequence of absorption of the contiguous parts of the wall by pressure (Fig.

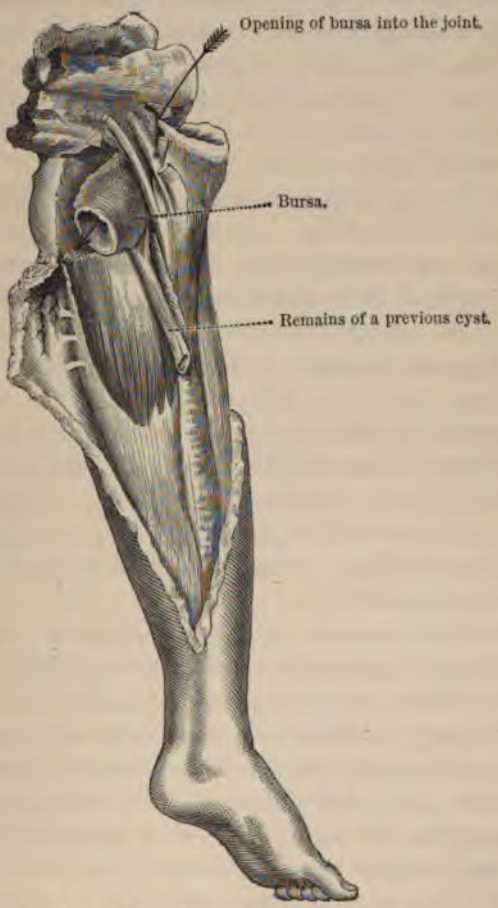

Fig. 284.—Bursa under the semi-membranosus tendon communicating with the knee-joint. A cyst had been incised and drained sixteen months previously. Its partially obliterated channel persists. (*D'Arcy Power.*)

284). This seems to happen most frequently in the case of the bursa under the semi-membranosus. It does not necessarily follow because an individual has a synovial cyst near the knee that the joint is diseased; attendance in an out-patient room will show that many synovial cysts slowly disappear without

treatment. This is important to bear in mind, for interference with these cysts is, as a rule, needless and often productive of much harm. Aspiration, injection of iodine, and the insertions of setons may lead to suppuration and destruction of the joint with which the cyst is connected. Mr. Morrant Baker, who first drew special attention to these synovial diverticula, states that when they arise in connection with the **knee** the cyst will project in the popliteal space, the upper part of the calf, or on the inner side of the calf as much as 10 cm. below the head of the tibia.

In the case of the **shoulder** the cyst projects in front of the joint a little below the clavicle, or in the upper third of the arm in the course of the long tendon of the biceps.

In the case of the **elbow,** the cyst projects on the inner side of the arm above the condyle. I have seen a cyst of this kind as high as the insertion of the coraco-brachialis, connected with the elbow joint by a tubular process of the diameter of the anterior interosseous artery. When they arise from the **carpal joints,** the cysts project on the back or front of the wrist. (See under Ganglion.) When connected with the **hip joint** the cyst forms a swelling in Scarpa's space, and in the case of the **ankle** the bulging is most marked in front and to the outer side of the joint.

The fluid contained in synovial cysts is in most cases identical with synovia, and occasionally contains "melon-seed" bodies. When the joint is the seat of tubercular disease the fluid in the cyst will contain pus cells, and occasionally it is true pus; when the skin over these swellings is red and glossy they have been mistaken for simple abscesses and incised.

Ganglion.—A ganglion is a cyst formed by the hernial protrusion of the synovial lining of a tendon sheath. There are two species—simple and compound.

A **simple ganglion** is seen in its most typical condition on the back of the carpus, where it forms a rounded, sessile elastic swelling which becomes tense when the wrist is flexed, and partially, or wholly, disappears when the wrist is extended. Many of these swellings, which are entered in clinical records as ganglions (or ganglia), are not connected with tendon sheaths. I have satisfied myself by careful dissections that

many of them are diverticula from the carpal joints, and in some instances they arise from the inferior radio-ulnar joint. During life it is difficult to distinguish between a hernia of the sheath of a tendon and a diverticulum from a carpal joint. As in the case of the larger joints, synovial cysts arising from the carpus are occasionally associated with tubercular arthritis.

Ganglia are sometimes met with on the fingers in connection with the sheaths of the long flexors and on the dorsum of the foot; as well as on the outer side of the ankle in relation with the tendons of the peroneus longus and brevis. The fluid in a simple ganglion is clear, transparent, and viscid, and resembles apple jelly.

The **compound ganglion** is a much more serious condition. It occurs mainly in connection with the flexor and extensor tendons at the wrist; it also occurs occasionally on the tendons of the peroneal muscles, where they lie in relation with the calcaneum.

A compound ganglion at the wrist assumes an irregular shape and extends for a variable distance up the forearm; it also sends a prolongation under the annular ligament to appear in the palm, when it arises in connection with the flexor tendons; a similar extension under the posterior annular ligaments is usually noticed when a ganglion is connected with the extensor tendons. A compound ganglion is usually soft and elastic, and imparts a crepitant sensation to the examining fingers when the tendons are set in action. This crepitant sensation is due to the presence in the ganglion of small bodies familiarly known as **melon-seed bodies,** from their shape and consistence; they are sometimes present in enormous numbers. There is much difference of opinion as to the source of these bodies. I have seen them hanging from the inner wall of the ganglion. An examination of many of the loose bodies will show that they have slender stalks; these appear more clearly when they are placed in water. Bodies identical in structure are met with in synovial diverticula and even in bursal sacs, particularly the prepatellar bursa.

Treatment.—A simple ganglion, such as is so common on the back of the wrist, is in a general way successfully treated by bursting it subcutaneously by the direct pressure of the

thumb, and then applying a graduated compress for a few days. When the wall is so thick that it will not rupture, the swelling may be punctured with a very narrow scalpel; this allows the mucoid contents to escape, and the application of a firm compress for a few days will obliterate the sac.

Compound ganglia require more radical treatment. Many have been successfully treated by incising the sac, squeezing out the contents—particularly any loose bodies the sac may contain—and detaching those which may happen to hang from the wall by means of a scoop. The sac should be carefully drained. Now and then severe complications have followed this method of treatment, and it has been necessary to amputate through the forearm.

In some cases the ganglion has been successfully dissected out as if it were a tumour, and it would appear that the patient runs less risk from this mode of treatment than by the common practice of incision and drainage.

It is well to bear in mind that some of these ganglia are associated with the early stages of tubercular disease of the wrist joint, and a few are undoubtedly due to tubercular infection of the tendon sheaths.

Bursæ.—On many parts of our bodies where muscles and tendons glide over osseous surfaces, or in situations where skin lies in close contact with bony prominences, membranous sacs occur filled with glairy fluids; such sacs are known as **bursæ.** Structurally a bursa consists of a thin-walled sac filled with glairy fluid. The inner wall of the cyst is quite smooth and, as a rule, devoid of epithelium.

In certain situations, such as the anterior surface of the patella and the posterior surface of the olecranon, a bursa is normally present. Bursal sacs may form in any part of the subcutaneous tissues when the overlying skin is submitted to unusual intermittent pressure, as in talipes when the patient walks on the dorsum or side of the foot; beneath corns; and at the metatarso-phalangeal joint in the condition termed bunion. Such are called **adventitious bursæ.** When bursæ arise in connection with tendons, they are spoken of as **sub-tendinous bursæ,** and they often communicate with the sheath of the tendon, and even with an adjacent joint. The

large bursa so constantly present at the insertion of the semi-membranosus often has a direct communication with the joint.

The origin of bursal sacs has been explained in the following manner:—

When the skin moves over joints, or passes over hard prominences, the intermediate connective tissue becomes torn or ruptured, thereby leading to the formation of spaces in which fluid collects. The boundary walls are at first irregular, and formed by adjacent connective tissue. Finally this becomes smooth and forms the sac wall.

Bursæ may arise during intra-uterine life when the fœtus is submitted to abnormal pressure. Many remarkable instances of this have been recorded, especially in association with talipes.

Most subcutaneous and many subtendinous bursæ arise after birth. When a subcutaneous bursa attains an abnormal size it is invariably due to unusual pressure associated with particular occupations. For instance, too much kneeling on hard material, whether in housemaids, devout persons, or carpet-layers, produces the familiar **prepatellar bursa**; repeated blows on the elbow produce **miner's elbow**; from carrying weights on the shoulder **porters** are liable to get a bursa over the acromial end of the clavicle; **tailors** from their cross-legged habit of sitting are sometimes troubled with one over the external malleolus; whilst **weavers** and **lightermen** from prolonged sitting on hard seats suffer from bursæ over their ischial tuberosities; **soldiers** when sleeping too frequently on the hard floor of the guard-room get them over their greater trochanters; the pressure of ill-fitting boots develops a bursa over the enlarged head of the metatarsal bone of the hallux; when associated with partial dislocation of the first phalanx it is known as a **bunion,** and bursæ are quite common on the ends of **amputation tumps.** Clement Lucas * has described as the **needlewoman's** bursa a cyst that formed on the palmar surface of the terminal phalanx of the middle finger in an old seamstress. A bursa is often present between the body of the hyoid bone

* *Guy's Hospital Reports*, vol. xliii. 143.

and the thyro-hyoid membrane, and **jockeys** acquire one in front of the ankle from the pressure of the stirrup.

Bursæ are liable to inflame, a process that may lead to suppuration, or stop short of that condition and become chronic or recurrent and lead to secondary changes in the walls of the sac so that its cavity becomes almost obliterated. Chronically inflamed bursæ sometimes attain the size of fists, especially the prepatellar and ischial varieties. Prepatellar bursæ sometimes rapidly solidify in syphilitics.

Jephson, in his interesting account of "Emin Pasha and the Rebellion at the Equator," relates that the women and many men of the Bari tribe whom he saw working in the fields had enlarged prepatellar bursæ due to kneeling whilst at work, and to the fact that the entrances to their huts were so low that it was necessary to enter on the hands and knees.

Treatment.—An inflamed bursa demands rest and the local treatment usually employed for inflamed parts. When the bursa is distended with fluid, it is the custom to apply a plaster of mercury and ammoniacum over the swelling and fix it firmly with a bandage. It is probable that the firm compression is the chief agent in promoting the absorption of the fluid. In some cases the swelling subsides spontaneously, and this probably explains the supposed efficacy of the application of tincture of iodine.

When bursæ are repeatedly irritated, the walls become so thick that it is necessary to excise the tumour. This mode of treatment is necessary when a bursa contains loose bodies. When the bursa is situated over the patella, malleolus, ischial tuberosity, or trochanter its removal is a very simple proceeding.

When a bunion inflames and suppurates it may involve the underlying metatarso-phalangeal joint. Many of these cases, especially in elderly individuals, demand amputation of the toe. When it is necessary to carry out this measure, it is much more satisfactory to remove the metatarsal bone as well as the toe.

When the bursa between the body of the hyoid bone and the thyro-hyoid membrane is very large it should be incised and drained. Care is necessary to avoid confounding an enlarged thyro-hyoid bursa with a cyst of an accessory thyroid gland, and *vice versâ*.

Pseudo-Cysts in connection with the Fallopian Tube.—When from any cause a clean foreign body finds its way into the peritoneal cavity, or a sterile coagulable fluid is exuded therein, a process is established whereby the foreign substance is encysted. Shattock * once found a rounded body with a

Fig. 285.—A gravid Fallopian tube with a pseudo-cyst or capsule formed around the blood effused through the cœlomic ostium. B shows the capsule entire, and in A it is in section so as to display its relation to the ostium and fimbriæ. * At fimbriæ.

diameter 6·25 cm. in the pelvis of a man between the rectum and bladder. On section a piece of iron was detected in its centre, surrounded by regular laminæ of structureless material. He regarded this as an instance in which a piece of metal taken into the alimentary canal had entered the

* *Trans. Path. Soc.*, vol. xliv. 151

peritoneal cavity by traversing the wall of the intestine; it had then become encysted by exudation (lymph) from the peritoneum.

It happens very frequently that in cases of tubal pregnancy which terminate by what is known as tubal abortion, and especially the form known as incomplete tubal abortion, in which blood slowly trickles, or even drips, from the cœlomic ostium, that the effused blood becomes surrounded by a lowly organised capsule, and this is occasionally so complete as to appear like an ovoid bulb or amphora containing blood, and its neck embracing the cœlomic ostium of the tube (Fig. 285).

Fig. 286.—Fallopian tube and ovary: the cœlomic ostium and fimbriæ are enclosed in a capsule of new formation. From a case of acute salpingitis.

This condition and the mode of formation of these capsules have been particularly studied by Saenger, Taylor, and Handley. The last observer has also proved that capsules of this kind are also formed occasionally in connection with tubal pregnancy terminating by rupture.

Capsules of this nature occasionally form around sterile inflammatory effusions (Fig. 286).

It would appear that the conditions necessary for the production of these capsules are that the intruded product—whether a solid body, an effusion of blood, or coagulable inflammatory fluid—should be free from pathogenic organisms, and, in the case of fluid, that it be slowly effused.

In this way imperfect capsules are formed on the walls of ovarian cysts, especially dermoids, and there can be little doubt that many of the reported cases in which these cysts are stated to have burrowed between the layers of the broad ligaments rest on erroneous observation, and that the supposed investment of the mesometrium was in reality a capsule of new formation.

The most perfect capsules formed in this way are met with around echinococcus cysts in the belly, especially those which project from the under-surface of the liver, or grow in the meshes of the omentum, and on occasions they may be very thick. This explains how echinococcus colonies in the belly are provided with thick spurious capsules, whereas those growing in the cerebrum have none.

The literature relating to the formation of capsules around blood slowly effused into the belly from gravid Fallopian tubes is given by Handley, *Trans. Obstet. Soc., London*, vol. xliv. 325.

CHAPTER LVIII.

NEURAL CYSTS.

UNDER this heading it is proposed to consider a number of conditions, some of which, like hydrocephalus and one variety of spina bifida, should be described with tubulo-cysts. Other varieties of spina bifida should be discussed with diverticula. On the whole it is more convenient to consider them collectively as **neural cysts.**

Hydrocephalus.—This term is applied to the head when abnormally enlarged in consequence of excessive accumulation of fluid in the ventricles of the brain. A very large majority of cases are congenital, or commence in the early month of infancy. Occasionally the condition will arise at a later period of life, when the fontanelles are obliterated; expansion of the skull is then impossible. Hydrocephalus very frequently accompanies spina bifida. Very many hydrocephalic fœtuses die during delivery, the large size of the head hindering the successful transit through the maternal passages. In some cases the head ruptures in consequence of the pressure to which it is subjected, or is intentionally perforated. In most cases of hydrocephalus which survive delivery, distension is only slight at birth.

The frequency with which hydrocephalus and hydramnion co-exist would indicate that the association is something more than mere coincidence. Statistics respecting the frequency of hydrocephalus drawn from living children are untrustworthy, as pre-natal hydrocephalus is very fatal.

In typical cases of hydrocephalus attention is arrested by the large size of the cranium and the smallness of the face. This is due to the slow accumulation of fluid within the cerebral ventricles, distending them and causing wide separation of the cranial bones, whilst the bones of the face retain their natural proportions. The two halves of the frontal bone are

separated from each other; the spaces between the parietal bones, and between these and the occipital, are far wider than usual (Fig. 287). Indeed, the bones of the cranial vault are so separated from each other, whilst those of the base retain their usual juxtaposition, that the bones of a hydrocephalic skull were compared by Trousseau * to the petals of an opening flower.

The head may become so large as to attain a circumference

Fig. 287.—Hydrocephalic skull, from an infant. (*Museum, Middlesex Hospital.*)

of a metre, or even a metre and a half when measured horizontally—that is, from the superciliary ridges to the occiput. The bones are excessively thin, and consist of a single table. The vault presents large membranous spaces irregularly dotted with ossific deposits. The sutures in relation with the parietal bones are occupied with Wormian bones; as many as two hundred have been counted in one skull (Fig. 288). In hydrocephalics who attain adult life the skull may become completely covered in with bone.

The brain presents great changes. The lateral ventricles are widely distended, and the crura cerebri, corpora striata,

* *Clinique Médicale*, tome ii. 321.

optic thalami, and other structures in the base of the brain are flattened. The cerebral hemispheres form thin boundaries to the ventricles, often less than 10 mm. in thickness; the convolutions become obliterated. In nearly all the specimens the distension is limited to the lateral and third ventricles: occasionally the fourth ventricle also is distended (Fig. 289). In some specimens each lateral ventricle has been known to

Fig. 288.—Hydrocephalic skull, showing Wormian bones. (*Museum, Middlesex Hospital.*)

attain a length of 20 cm. and to communicate with its fellow through an opening the size of an orange.

When the ventricles are very distended and the skull is proportionally thin, a wave of fluctuation may be transmitted from side to side. In exceptional cases the head is translucent.

In an account of hydrocephalus it is difficult to avoid reference to the classical case of James Cardinal, especially as a cast of his head is to be found in many pathological museums (Fig. 290).

James Cardinal died at the age of twenty-nine years in Guy's Hospital, under the care of Sir Astley Cooper, in 1824.

He was born at Coggeshall, Essex, in 1795. At birth his head was very little larger than natural. A fortnight later it began to increase, and gradually grew until he was five years old; it then appeared to remain stationary. He was unable to walk until six years of age, but went to school and learned to read and write. His head was at this period translucent when placed between the eye of the observer and a bright light.

Fig. 289.—Sagittal section of a hydrocephalic skull from a child, with the brain *in situ*. The head of the arrow is in the fourth and its feathers in the third ventricle. The infundibulum is widely dilated. (*Museum, Middlesex Hospital.*)

Cardinal continued in tolerable health until twenty-three years of age, when he began to have fits, for which he applied to the hospital. His manners were childish, otherwise his mental faculties were well developed. Death eventually supervened from lung disease.

When the head was examined the brain was found lying at the base of the skull. Between the membranes there were seven pints of fluid. The ventricles contained one pint. It appeared as if the fluid had been originally contained within

the ventricles, but had burst through an opening in the corpus callosum and compressed the brain downwards. The cranium measured 82·5 cm. (33″) in circumference, and had a capacity of ten pints. The skeleton is contained in Guy's Hospital Museum.

The fluid in hydrocephalus is identical with cerebro-spinal fluid. Occasionally it has been found to contain albumen. This may be attributed to inflammation, and has been observed in those cases where paracentesis has been performed. The

Fig. 290.—Drawing from a cast of the head of James Cardinal. The cast from which this drawing was taken appears to have been moulded April 11th, 1822.

amount of fluid may be very large. Six and eight and even ten pints have been recorded. Little is known as to the cause of hydrocephalus. In many cases obstruction to the interventricular communications has been detected. Hydrocephalus is often associated with spina bifida, and all the passages in the brain and the central canal of the cord have been found dilated. In several cases in which hydrocephalus supervened on spina bifida I found the central canal of the cord normal. Interference with the interventricular passages will produce hydrocephalus (Fig. 291).

The great difficulty encountered in investigating the pathology of this condition arises from the soft and diffluent nature of the brain of hydrocephalic fœtuses, especially when stillborn. It should also be remembered that many grave malformations of the limbs and viscera are often associated with hydrocephalus, and it is well to bear in mind the frequency with which it is accompanied by hydramnion.

Hydrocele of the Fourth Ventricle.—Leading from each lateral angle of the fourth cerebral ventricle there is a tubular process encircled by a duplicature of the ligula termed the cornucopia. These passages or **lateral recesses** are traversed by the choroid plexuses of the fourth ventricle, and the recesses

Fig. 291.—Head of a lion's whelp in section, showing great dilatation of the cerebral ventricles due to obstruction of the interventricular passages by a thickened (rickety) tentorium.

themselves open into the subarachnoid space at the base of the flocculus, close beside the root filaments of the facial, auditory, glosso-pharyngeal and vagus nerves. These passages establish free communication between the fourth ventricle and the general subarachnoid space. When one of these processes becomes occluded, the recess will dilate and form what Virchow * terms **hydrocele of the fourth ventricle.** This pathologist has figured a specimen that had attained the size of a cherry-stone and pressed upon the flocculus and the facial nerve: remnants of the choroid plexus of the fourth ventricle projected into the cyst. Though the walls of this cyst were thin, its pressure had caused paralysis of the facial nerve.†

* "Die Krankhaften Geschwülste," bd. i. 183.

† See also Recklinghausen, Virchow's *Arch.*, bd. xxx. 374.

Cranial Meningocele.—This term is applied to a hernial protrusion of the meninges of the brain through an unossified portion of the skull. When the protrusion consists of brain matter as well as membranes it is described as a **meningo-encephalocele.**

Meningoceles, using the term in its general sense, occur in definite regions. The commonest of all situations is the occiput; in about two-thirds of the cases the tumour projects in this part of the skull. Next in frequency to their appearance at the occiput, meningoceles appear at the root of the nose. In other regions of the skull they are excessively rare. It is usually stated that they may appear at the anterior fontanelle, but

Fig. 292.—Occipital meningo-encephalocele. The cyst probably represents an expanded fourth ventricle: there was no cerebellum, but a large and conspicuous flocculus.

critical examination of the descriptions of suspected cases makes it probable that many of the supposed meningoceles were dermoids (see p. 353).

Occipital meningoceles appear, during life, to protrude through the foramen magnum; when the parts are dissected the pedicle will be found to make its way through a gap in the supra-occipital between the posterior margin of the foramen magnum and the occipital protuberance. This space during early embryonic life is occupied by a fontanelle.*

When the meningocele is examined it will be found to be covered externally by skin, and usually lined internally by tissue directly continuous with the ependyma of the ventricles.

The relation of the flocculus in cases of occipital meningocele

* *Med.-Chir. Trans.*, vol. lxvii. 157.]

is of importance. In the descriptions of reported cases of this malformation the cerebellum, if referred to, is described as rudimentary or absent. As a matter of fact, in these cases the cerebellum is absent, and that which is supposed to represent this part of the brain is an enlarged flocculus (Fig. 292). Cleland * has pointed out that the flocculus is developed from a lateral outgrowth of the floor of the third encephalic vesicle, whilst the cerebellum is developed from the foremost part of the roof of that vesicle. An appreciation of this fact throws valuable light on the nature of occipital meningocele, for the absence of the cerebellum indicates that the hernial protrusion is the third encephalic vesicle; instead of its walls thickening to form a cerebellum, they become passively dilated into a cyst. Indeed, this form of meningocele bears much the same relation to the fourth ventricle and the cerebellum that hydrocephalus bears to the lateral ventricles and the cerebrum. An occipital meningocele might not inaptly be described as *hydrocephalus limited to the fourth ventricle.*

Occipital meningo-encephaloceles often hang so low as to render it difficult to decide whether the cyst belongs to the cranium or to the cervical region of the spine. There is reason to believe that the pedicle of a cranial meningocele may become obliterated so as to cut off the communication between the cyst and the subdural space. I have never had an opportunity of dissecting a specimen in which this has happened. Such an event certainly occurs with spinal meningoceles.

A cranial meningocele is sometimes associated with spina bifida; such a combination is, as a rule, accompanied by gross malformations, especially in connection with the lower limbs. It has already been mentioned that dermoids are apt to be mistaken for meningoceles, and it is certain that meningoceles are sometimes mistaken for dermoids. With careful aseptic precautions, meningoceles may be, and are often, safely excised. In some successful cases hydrocephalus has followed the excision of a cranial meningocele.

Individuals with meningoceles, particularly when the cyst is large, rarely survive their birth many weeks. Death is

* *Journal of Anat. and Phys.*, vol. xvii. 257.

usually due to sloughing of the sac and consequent septic meningitis.

Cephalhæmatoma is the name given to a collection of blood extravasated in consequence of injury between the vault of the cranium and the pericranium.

Cephalhæmatoma arises on the heads of children as a consequence of blows or falls, and in the majority of cases the effused

Fig. 293.—Monkey (*Cebus monachus*) with a huge cephalhæmatoma.

blood is slowly absorbed. In a certain proportion of cases suppuration occurs, and the hæmatoma is converted into an abscess. This is particularly liable to occur if air is admitted either through abrasion of the parts at the time of the accident or by exploratory punctures made by the surgeon. In most cephalhæmatomata, a few days after their formation a hard ridge forms around the confines, and this, when contrasted with the pulpy, yielding sensation imparted to the finger by the rest of the swelling, often gives rise to the impression that the individual has sustained a depressed fracture of the skull.

Knowledge of the fact is, as a rule, sufficient to prevent error in diagnosis.

This hard ridge is interesting in another way, for it is liable to ossify. In many cases, as the blood is absorbed this ridge likewise disappears, resembling in this respect callus around a fractured long bone. In rare instances adventitious bone thus formed may persist and form a large bony crater to the skull.

The formation of bone in the peripheral portions of a cephal-

Fig. 294.—Skull of *Cebus monachus*, showing the bony walls of the cephalhæmatoma and a group of Wormian bones. (*Museum, Royal College of Surgeons.*)

hæmatoma admits of simple explanation. Virchow long ago pointed out that the pericranium which forms the limiting capsule of the swelling is a bone-forming membrane, and though separated from the vault of the skull by blood, still pursues its bone-forming function. Another remarkable character of a cephalhæmatoma is the great length of time the blood will remain fluid within it.

The most remarkable cephalhæmatoma that has come under my notice occurred in a monkey (*Cebus monachus*). When deposited in the Zoological Gardens this monkey had on its head a large rounded tumour (Fig. 293), which was soft

and fluctuating at the top, where a feeble pulsation was perceptible. That portion of the tumour near the skull was extremely hard and felt like bone. The monkey was in excellent health and seemed in no way encumbered by its burden. It continued in this way many weeks; the tumour did not increase in size, but the hardening of its walls became more extensive. Some months later the monkey fell ill, and as it seemed in great suffering I killed it by means of chloroform. The tumour when dissected was found to be an old cephalhæmatoma with extensive ossification of its walls (Fig. 294); the crater-like arrangement of bone on the top of the skull was covered in by pericranium and contained dark fluid blood. The frontal bone where it formed the floor of the cavity was so thin that in places it yielded to the pressure of the finger, like parchment. Some of the ossicles which formed the walls of the cyst were bevelled at the edges and serrated, so as to articulate one with the other like Wormian bones. Fragments of these bones were examined microscopically and found to exhibit the structure of true bone. The serrations at the edges of these bones were probably due to the movements of the cyst during their formation, for it was noted that there was slight pulsation.

Cephalhydrocele.—This is usually defined as a pulsatile tumour containing cerebro-spinal fluid communicating with the interior of the skull through an abnormal opening, the result of injury; it does not demand further consideration here.*

* Smith, *St. Barth. Hospital Reports*, vol. xx. 233; Lucas, *Guy's Hospital Reports*, 1876, 1878, 1881, and 1884; Godlee, *Trans. Path. Soc.*, xxxvi. 313.

CHAPTER LIX.

NEURAL CYSTS (*concluded*).

Spina Bifida.—The term spina bifida is applied to congenital defect in the union of the laminæ of one or more vertebræ,

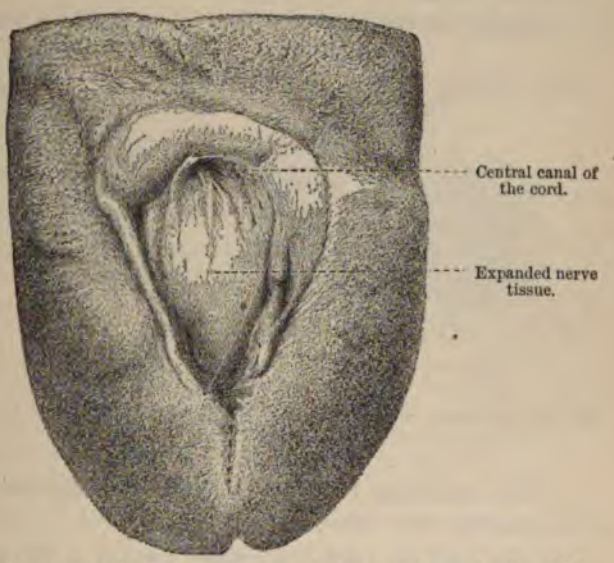

Fig. 295.—Lumbar region of a fœtus with spina bifida, variety myelocele. (After Shattock.) (*Museum, Middlesex Hospital.*)

associated with malformation of the spinal cord or its membranes.

The spinal cord and a large part of the brain are formed by the dorsal coalescence of the medullary folds. The fusion of these folds commences in the thoracic and extends into the cephalic and caudal regions. For a short time after coalescence the embryonic cord and superficial epiblast remain in contact. Gradually they become separated by the intrusion of connective tissue, some of which chondrifies and afterwards ossifies to form vertebræ and intervertebral discs. In the early stages

the cord has a longitudinal extent equal to that of the notochord, and this equality is maintained for some time after the closure of the medullary groove. Subsequently the vertebral column grows at a greater rate than the nerve-tube; the result is that at birth the medullary cone at the end of the cord is opposite the upper border of the second lumbar vertebra.

The varieties of **spina bifida** are determined according to the stage of development at which the defect occurs, as determined by the anatomy of the parts. They are:—

(1) Myelocele, (2) syringo-myelocele, (3) meningo-myelocele, (4) meningocele, (5) masked spina bifida (*spina bifida occulta*).

Fig. 296.—Diagram to represent the microscopic characters of a transverse section of a myelocele.

1. *The medullary folds may unite imperfectly and give rise to a* MYELOCELE (Fig. 295).

In this case the cord is normally formed in the cervical and thoracic regions, but in the lumbar portion the central canal suddenly opens on to a shallow depression, the sides of which are slightly intumescent and then become gradually continuous with the skin. The tissue surrounding the furrow represents the medullary folds and consists mainly of very vascular nerve tissue. When fresh this area is bright red and resembles a nævus.

When this red tissue is carefully dissected from the underlying vertebræ and prepared for the microscope, it will exhibit on each side of the furrow nerve-cells embedded in neuroglia intermixed with plexuses of arterioles, venules, and capillaries (Fig. 296). It is hard to determine the existence of epithelium

on the surface of myeloceles, because there is usually some inflammation, and occasionally sloughing.

Myeloceles are, according to my observations, more common in the stillborn than in children that survive their birth a few days.

Children with myeloceles rarely live more than a few days; the central canal of the cord, being open, allows a continual draining away of the cerebro-spinal fluid, which soon leads to death.

2. *The medullary folds unite throughout, but fail to separate from the surface epiblast. The central canal becomes subsequently dilated* :—SYRINGO-MYELOCELE.

Syringo-myelocele is an excessively rare variety of spina bifida, and cannot be determined from simpler forms during life. When the parts are dissected the distinguishing feature is that the nerves gain the intervertebral foramina by running round the convexity of the cyst (Fig. 297).

Fig. 297.—Syringo-myelocele in transverse section.

Although syringo-myelocele is very rare in a typical form, it may occur in combination with a meningocele. Clutton * has carefully described an example (Fig. 298).

3. *The cord is normally closed, but, before it separates from the surface epiblast, becomes compressed by a collection of fluid within the meningeal spaces* :—MENINGO-MYELOCELE.

Probably two-thirds of all cases of spina bifida that survive their birth are meningo-myeloceles. The condition is easily recognised; there is a deficiency in the arches of the vertebræ, usually in the lumbar region, occupied by a cyst of variable size. Unless inflamed, or flaccid in consequence of leakage, the cyst is translucent and often presents a pink tinge. Its most posterior part is somewhat flattened, and occasionally a shallow median groove is seen. In some specimens, quite in the centre of the cyst there is a small umbilicus marking the central canal of the cord. At the edge of the cyst where its walls become

* *Trans. Clin. Soc.*, vol. xix. 99.

continuous with the skin the margin is slightly raised, and immediately beyond this the skin, even in the new-born, may present a circle of long hairs.

Meningo-myeloceles are often associated with hydrocephalus and, in a large proportion of cases, with double talipes equino-varus, and other severe deformities of the lower limbs.

On transverse section of a meningo-myelocele the cord is found flattened on the posterior wall of the cyst like a strap, whilst the nerves reach their respective foramina by directly traversing the cavity of the cyst (Fig. 299).

Fig. 298.—Syringo-myelocele and meningocele in longitudinal section; from the cervical region. (*After Clutton.*)

That the strap-like band of nerve tissue on the posterior wall of the sac is the flattened spinal cord was demonstrated by Shattock.* He cut sections of this part of the cyst and detected the central canal (Fig. 300).

4. *The cord is normal, but there is a local hernia of the membranes* :—MENINGOCELE.

Protrusion of the membranes unaccompanied by the cord is by no means common in spina bifida. Although it has been met with in the cervical region of the spine, it most frequently affects the lumbo-sacral region, or may be entirely confined to the sacral portion of the spine. Some writers on this mal-

* *Trans. Clin. Soc.*, vol. xviii., Spina Bifida Report.

formation believe that the hernial protrusion may make its way between the arches of two vertebræ instead of between the laminæ of a single vertebra. It is a fact that the sac of a meningocele sometimes emerges through a very narrow orifice, and in a few instances this causes the cyst to become more or less pedunculated, and may lead to occlusion of the aperture by which the dural space and the cyst communicate and thus isolate the cyst.

Fig. 299.—Diagram showing meningo - myelocele in transverse section. The cord is flattened on the posterior wall of the cyst, and the nerves traverse its cavity.

Virchow * investigated a remarkable specimen illustrating this process. The patient was a negro child born with a large tumour pendulous from its buttock (Fig. 301). The tumour was removed in Central Africa and sent to Virchow, under the impression that it was a fatty tumour. Dissection revealed a central space in the tumour lined with dura mater, which was covered with fat intermixed with muscle tissue. The structure and arrangement of the parts were such as to lead Virchow to the opinion that the tumour was the sac of a meningocele.



Fig. 300.—Microscopical appearances of the nerve tissue from the wall of a meningo-myelocele showing the central canal. (*After Shattock.*)

A tumour in many respects similar to this, save that it occurred in the cervical region of the spine, was removed by Solly in 1856 from a woman twenty-seven years of age. The

* *Arch.* bd. c. 571.

description of the case is accompanied by an exceedingly interesting clinical history.* Protrusions of dura mater unaccompanied by cord or nerves (meningoceles) are more common in the sacral region than elsewhere. In some instances the membranes emerge through the deficiency (hiatus sacralis) normally present below the third sacral vertebra.

This will perhaps be the most convenient place in which

Fig. 301.—African child with a pedunculated tumour (an occluded spina bifida sac) attached to its buttock. (*After Virchow.*)

to refer to an abnormal disposition of the cord which I have met with in association with spina bifida. It is well known that in the early embryo the cord extends the whole length of the vertebral column, but at birth the apex of the medullary cone is on a level with the upper border of the second lumbar vertebra. I have placed in the museum of the Middlesex Hospital a spine with a large meningocele in the sacral region; the cord runs the whole length of the neural canal and terminates

* *Med.-Chir. Trans.*, vol. xl. 19.

at the tip of the sacrum. The specimen was obtained from a child three months old.

5. *The cord and its membranes are normally formed, but the arches of one or more vertebræ are defective. There is, however, no protrusion of the membranes or cord :*—MASKED SPINA BIFIDA (spina bifida occulta).

This defect, as it is unaccompanied by a cyst, is very apt to be overlooked. An interesting feature usually associated with this condition is an abnormal growth of hair in the loins. Hair fields of this description may be localised to the loin, as

Fig. 302.—Tumour from the African child (see previous figure), shown in section.

in the original case described by Virchow,* and the hair may form a long tuft (Fig. 303). In exceptional cases an abnormal growth of hair may extend from the loins over the buttocks and for a considerable distance down the thighs.

The two varieties observed in the distribution of hair in these cases are well illustrated by the arrangement adopted by artists and sculptors in their representations of fauns and the goat-footed satyrs (Fig. 304).

Many cases of spina bifida in addition to the "masked" species are accompanied by an excessive development of hair

* *Zeitschr. für Ethnologie*, 1875, bd. vii. 280, taf. xvii. fig. 2.

in the loin. Attention has already been drawn to the fact that a circlet of hairs is often observed on the skin immediately bordering the sac of a meningo-myelocele, even in new-born babes.

This excessive development of hair associated with defective closure of the neural arches is interesting when studied in connection with the luxuriant growth of feathers on the heads of Polish fowls, for in many of these birds there is defective

Fig. 303.—Hair-field overlying a spina bifida occulta; there is also a long tuft in the cervical region. (*Fischer.*)

ossification of the bones of the cranial vault. An important condition often associated with spina bifida occulta is perforating ulcer of the foot. Indeed, this association is now so well recognised that in every case of perforating ulcer of the foot, occurring in young patients, it is the duty of the surgeon, as a matter of routine, to examine the loins.

In addition to non-union of the arches in the vicinity of spina bifida, the vertebræ are liable to be defective in other ways, and of these defects the most striking is the absence of half a vertebra—that is, half the centrum, with its pedicle, lamina,

transverse, articular and spinous processes, is wholly wanting. The persistent half of such a vertebra has the characters shown in Fig. 305, and is often ankylosed to the vertebra above and below. Sometimes the half-vertebra is in excess of the ordinary number. Exceptionally, a considerable extent of the column will be replaced by an alternating series of half-vertebræ; this is especially seen when the cervical portion of the column is the seat of spina bifida.

Half-vertebræ occur occasionally independently of spina

Fig. 304.—Ægipan sporting with a faun. (Bacchus and Silenus.)

bifida; they have also been detected in the spines of snakes, calves, fish (sole), and rabbits. The amount of disturbance sometimes caused in a vertebral column by spina bifida is very remarkable. Occasionally horizontal processes of bone project from the vertebral centra into the neural canal, and sometimes transfix the cord. Several examples have been carefully described in which the cord has bifurcated and coalesced again in order to enclose a beam of bone crossing the canal in a sagittal direction.*

* Shattock, *Trans. Clin. Soc.*, vol. xviii.; Report of Spina Bifida Committee, p. 34 and plate vi.; and Sir George Humphry, *Journal of Anatomy and Physiology*, vol. xx. 585.

Complications of Spina Bifida.—Unfortunately all species of spina bifida are apt to be associated with other serious conditions, such as talipes equino-varus, single and double, and other gross deformities of the legs, hydrocephalus, meningocele, and malformations of the alimentary canal, such as imperforate anus and on rare occasions imperforate pharynx. Very exceptionally these two imperforate conditions of the alimentary canal have co-existed.

The most serious complication of spina bifida is **hydro-**

Fig. 305.—Half-vertebra. (*After Shattock.*)

cephalus: the ventricular cavities of the brain may be abnormally dilated at birth; in many cases the hydrocephalus slowly develops during the first few weeks of infant life, and the head gradually assumes enormous dimensions. In a small proportion of cases the sac of the spina bifida spontaneously shrinks; coincidently with this the fontanelles gradually widen and hydrocephalus develops. I have in several children seen hydrocephalus supervene when the sac in the loin has been made to shrink by artificial means.

We have now to consider the various modes by which spina bifida destroys life. Of all the varieties of this malformation, **myelocele** is the most fatal. A very large proportion of fœtuses in which this condition is present are stillborn; the

few that survive their birth rarely live longer than three days, the continued leakage of cerebro-spinal fluid being sufficient to explain the invariable brevity of their lives.

When a distinct sac is present life may be prolonged many weeks, even when the sac wall is thin; when it is thick, life may be prolonged several years; and when it is completely skin-covered some of these children survive and grow up to be healthy men and women. The prospects of the case are largely influenced by the thickness of the sac wall and the absence of complications, especially hydrocephalus.

In many cases, especially when the walls of the cyst are thin, the tissue is apt to slough—an event that allows the sudden escape of the cerebro-spinal fluid and may terminate the life of the child in a few hours. Children often survive this accident to succumb seven or ten days later from septic meningitis. Exceptionally, I have observed children recover from rupture of the sac, and, escaping meningitis, slowly die from hydrocephalus. Occasionally the sac in the loin and the hydrocephalus will increase simultaneously. In such a case pressure on the anterior fontanelle will increase the tension in the spina bifida sac, and *vice versâ*.

The duration of a child's life with spina bifida, excepting the "masked" species, is very uncertain; it is often prolonged when the nurse and mother are careful, and vigilantly preserve the sac from injury.

That spina bifida is a serious affection may be gathered from the figures in the Registrar-General's Reports; about 800 individuals in England die from it every year. This information is not precise, as the actual number of cases is much greater, because the birth of the stillborn is not registered. No facts are accessible that will enable an accurate estimate to be formed of the real frequency of the malformation.

Treatment.—This has undergone a great change in recent years. Instead of the slow and uncertain method of injection with iodo-glycerine solution, it has been shown that spina bifida sacs may be safely excised and with satisfactory results, immediate and remote.*

* Z. H. Evans, *International Journal of Surgery*, 1895; and especially Nicoll, *Glasgow Hospital Reports*, 1899.

The Evolution of the Central Nervous System.—The extraordinary frequency with which the membranous and bony coverings of the central nervous system are malformed induced me some years ago to investigate the abnormalities collectively classed under the term spina bifida, with the hope of obtaining some light as to the mode of evolution of the brain and spinal cord, for, as I pointed out in 1886, the pathological behaviour of the central canal of the cord indicated that it was an obsolete passage. In 1887 I came to the conclusion from embryological and pathological data that the brain and cord were in all probability *evolved from a segment of the primitive intestine.** This view has been confirmed since by the independent researches of Gaskell.†

Andriezen ‡ has demonstrated the existence in amphioxus and ammocœtes of an epithelium-lined duct extending from the buccal cavity into the ventricle (thalamocœle), and succeeded in transmitting carmine particles suspended in water into the central canal of the cord. He regards the central canal of the cord as a remnant of the water-vascular system.

Tails.—This account of spina bifida would be imperfect without a brief notice of tails, real and supposed, in the human subject. We may with Virchow § arrange tails in two classes, *true* and *false*. True tails may be *complete* or *incomplete:* the most perfect or complete tails contain bony segments (vertebræ), as in the case of cats and dogs; the less perfect or incomplete tails are like those of pigs, soft and flexible. No one has yet reported an example of a tail in the human subject containing bony elements. Several cases have been investigated in which an appendage 5 cm. long, and soft like a pig's tail, has been found directly continuous with the coccygeal vertebræ.

Most of the cases reported as tails were examples of congenital sacro-coccygeal tumours, or a tuft of hair covering a masked spina bifida. Tumours supposed to be tails were in some cases dermoids; in others fatty tumours, or the sac of a spina bifida, and in many cases teratomata.

* *Brain*, vol. x. 429.
† *Journal of Physiology*, vol. x. 153.
‡ *Brit. Med. Journal*, 1894, vol. i. 54.
§ *Berliner klin. Wochenschr.*, 1884, No. 47

CHAPTER LX.

ECHINOCOCCUS COLONIES (HYDATID CYSTS).

THE term **hydatid** formerly covered a large number of pathological productions, but the term is now restricted in human pathology to the cystic stage of *Tænia echinococcus*. This cestode, which in its mature form inhabits the intestines of dogs, is about 4 mm. in length and consists of four segments, of which the fourth is larger than the rest of the body and is the only segment that becomes mature.

The eggs of this worm are passively conveyed with either food or water into the alimentary canal of man, where they are hatched; the embryo migrates from the intestine into some vascular organ or tissue, or, by gaining entrance into a blood-vessel, is passively conveyed into some distant part of the body and becomes transformed into a cyst.

The cyst-wall has a peculiar structure; it consists of an external, highly elastic, lamellar cuticle, and an internal lining consisting of granular matter, cells, muscle tissue, and a water-vascular system.

The inner lining is often referred to as the parenchymatous layer. In addition to the proper tissues of the cyst, there is often a more or less complete fibrous capsule, especially when the cyst projects into the peritoneal cavity. The mode by which these adventitious capsules are formed is discussed on page 507. The true cyst is maintained in apposition with the fibrous capsule by the pressure of the contained fluid; when this is removed by the abstraction or escape of the fluid, the mother-cyst at once collapses.

When the hydatid attains the size of a walnut, small vesicles or **brood-capsules** develop from the parenchymatous layer. These brood-capsules develop numbers of heads or **scolices**. The scolex when fully developed is about 0.3 mm. long, is furnished with four sucking discs and a rostellum of tiny blunt hooklets; it has a water-vascular system and numerous

calcareous particles. The fore part of the scolex can be withdrawn into the hinder part; indeed this is the position in which they are usually found.

As fresh brood-capsules and scolices are formed, the cyst enlarges and, when seated in an organ or cavity of the body which imposes little restraint upon its growth, it may attain enormous proportions—*e.g.* hydatid cysts of the liver have been known to acquire a capacity of sixteen pints.

In many hydatids **daughter-cysts** are formed from brood-capsules and probably from scolices. Cysts containing large numbers of these translucent thin-walled vesicles are known as **echinococcus-colonies** (Fig. 306).

Occasionally hydatids even of large size do not contain vesicles or brood-capsules; such are said to be **sterile.** The walls of sterile hydatids exhibit the characteristic lamination, and this enables the nature of the cyst to be recognised in otherwise doubtful cases.

An exceptional mode in which hydatids manifest themselves is known as **multilocular hydatids** (*Echinococcus multilocularis*, Virchow). In this condition the vesicles are of small size, but occur in great number, and are not contained in a mother-cyst. The vesicles in such cases rarely exceed a pea in size, but the majority are much smaller; very many are no larger than millet- or rape-seed. This variety occurs most frequently in the shafts of long bones (Fig. 309). They have also been observed in the spinal canal.

The multilocular hydatid also occurs in the liver as a firm tumour, which on section presents trabeculæ of dense fibrous tissue that cause it to assume an alveolar appearance. The alveoli contain a gelatinous substance in which the shrunken vesicles are embedded.

Most of these minute vesicles are sterile, but here and there a few hooklets can with patience be demonstrated. Virchow * was the first to demonstrate the hydatid nature of such tumours in the liver; previously they had been described as colloid cancer. In very rare instances contracted and shrunken vesicles embedded in gelatinous material and surrounded by a distinct

* *Verh. d. Phys. Med. Ges. zu Wurzburg*, 1856, bd.vi. 84. (See also *Australian Med. Journal*, 1884, p. 171.)

cyst have been observed in the liver.* No satisfactory explanation has yet been advanced to account for this curious variation in the development of echinococcus colonies. Ziegler has written an exhaustive monograph on this form; he considers it a distinct species, and has met with it in the brain, lung, and liver.

The usual mode of termination of a hydatid is to cease to grow; it then dies, shrivels up, and calcifies, assuming a friable appearance like old mortar.

When the cyst continues to grow its tendency is to rupture; the great tension exerted by the accumulating fluid, and especially the formation of daughter-cysts, induces necrosis of portions of the cyst-wall.

When hydatids are contiguous to hollow viscera, such as the intestine, stomach, trachea, and the like, the cyst is apt to come into contact with them, and the mutual pressure leads to absorption of the intervening tissue, and allows of the transmission of gas, air, or the osmosis of fluids which kill the parasite, and the entrance of pathogenic micro-organisms establishes suppuration.

In many instances the communications between the colonies and hollow viscera are so free that the contents of the cyst are evacuated. In some instances this is a fortunate termination; but frequently it is a catastrophe to be dreaded, as it may immediately cause death, or lead to secondary changes that have ultimately a fatal issue.

In rare cases the contents of the cyst become converted into colloid material of about the consistence of gelatine.

Geographically, the hydatid has a very wide distribution, which corresponds with that of the dog. It is, however, far more frequent in some regions of the world than others. Iceland is notorious for the frequency with which its inhabitants fall victims to hydatids; after allowing great latitude for errors in the direction of excess in calculating its frequency, echinococcus disease must be regarded in the light of a persistent epidemic so far as that island is concerned.

Next to Iceland, Silesia is usually regarded as the most infected district in Europe. In Australia hydatids are ex-

* *Echinococcus multilocularis.*

cessively frequent, and whereas most of the monographs on this disease in its clinical aspects, written thirty years ago, were founded in a large measure on observations made in Iceland, we now look to the writings of Australian physicians and surgeons for information on the pathology, diagnosis, and treatment of echinococcus colonies.

In Asia the disease is known; it occurs in India, though it is far from common. In America the disease is not frequent; judging from the few references to it in American literature, hydatids appear to be far rarer in North America than in the British Isles.

Zoologically hydatids are not very restricted, for they have been observed in monkeys, lemurs, cows, sheep, goats, deer, camels, antelopes, giraffes, horses, asses, zebras, hogs, squirrels, and kangaroos, in addition to man.

Topographical Distribution in Man.—Although a hydatid cyst may form in almost any organ in the human body, it occurs with greater frequency in some organs and tissues than in others. A comparison of statistical tables compiled in Iceland, Germany, Australia, and America brings out most decisively the fact that hydatids are met with more frequently in the liver than in all other parts of the body together; whilst in other organs, such as the breast, thyroid gland, or spinal cord, the literature of a century would furnish probably under a score of trustworthy cases. Hydatids, in addition to the above organs, have been found in the following:—Kidneys, lung, spleen, bones, suprarenal capsule, scrotum, cerebrum, cerebellum, heart, axilla, orbit, etc. It is a curious fact that no one has recorded an undoubted example of an echinococcus cyst in the ovary or testis.

Hydatids occur singly or may be distributed over the body in great numbers. The effects to which they give rise vary with the situation and dimensions of the cyst. For instance, a cyst of such a size as to cause no inconvenience when seated in the liver would, if growing in the brain or walls of the heart, soon induce death from mechanical causes. Again, a hydatid of the liver will often attain a very large size before causing inconvenience to the patient, whereas one only half the size situated in the pelvis would produce much distress by interfering with

the function of the rectum or bladder. On the other hand, a small hydatid of the liver no larger than an orange when accidentally ruptured so that its contents escape into the peritoneal cavity may rapidly destroy life, but a cyst the size of a melon, or larger, bursting into the rectum will not lead to much trouble; though even a small cyst so seated as to rupture into the trachea will, when the event comes to pass, almost inevitably cause death by suffocation. Indeed, the ways in which hydatids kill are so many and so various that they will be dealt with under each organ.

Liver.—Hydatids, as we have said, are more common in the liver than in any other organ. The frequency with which these cysts occur in the liver as compared with other viscera is not due to any selective power on the part of the embryo, but may be attributed to the fact that it finds its way into the gastric tributaries of the portal vein and is passively conveyed into the gland. As a rule they occur singly in the liver, though many instances have been reported in which three or four hydatids have been present; but there is apparently no limit to their number, for the museum of St. Thomas's Hospital contains a portion of a liver enormously enlarged in consequence of the presence of a multitude of these cysts.

The relative frequency of hydatids in the liver, the large size they attain in this organ, and the risk they occasion to life have caused them to be very attentively studied.

When the cyst ruptures spontaneously it may take various directions. Thus it may burst into the **pleura** and give rise to fatal pleurisy. Should the **lung** be adherent to the diaphragm, the cyst may open into it and the contents be discharged through the bronchial tubes and trachea. Under these conditions gangrene of the lung may follow the rupture.

In a few instances the cyst has burst into the **pericardium.** Such an accident is rapidly fatal, as the inundation of the pericardial cavity by fluid and vesicles embarrasses the heart. In some cases death has followed from pericarditis.

Rupture of a large cyst into the peritoneal cavity leads to serious consequences, but even when the cyst is small it may lead to general infection of the peritoneum. In a case under my care there was reason to believe that a hepatic cyst had

ruptured into the lesser bag of the peritoneum, for the whole of the small omentum was thickly beset with small hydatids. Graham records a similar observation. The cyst has been known to rupture into the **stomach,** the vesicles being afterwards vomited; and in a few cases they perforated into the **intestine,** the contents of the cyst being discharged by the anus.

Among the rarer directions, hydatids have been known to rupture into the **biliary passages,** the obstruction caused by the vesicles has induced jaundice, and their subsequent passage along the common duct has produced biliary colic.

Another excessively rare direction is for the cyst to rupture into the **inferior vena cava,** the contents reaching the right side of the heart.

Cases have been reported in which the pressure of a cyst has induced atrophy of the intercostals and its contents discharged externally. Cysts have also been known to burst externally near the umbilicus. Suppurating cysts may terminate in any of the directions mentioned above.

Hepatic hydatids may cause death by their size embarrassing respiration, or by pressure on important organs, such as the **vena cava,** producing **anasarca;** or by hindering the circulation through the **vena portæ** and causing **ascites;** whilst suppuration will lead to exhaustion or induce death by septicæmia or pyæmia.

When the fluid escapes into the peritoneal cavity it is apt to produce an urticarial eruption known as the **hydatid rash.** It usually appears shortly after the cyst has been ruptured or punctured; it itches intensely, lasts two or three days, and is usually accompanied by high temperature and sometimes by abdominal pain. It is referred to by several observers. Krabbe writes:—"A curious phenomenon is habitually observed when hydatids rupture into the peritoneal cavity: it provokes a transient urticaria." *

Finsen † refers to two cases worth mentioning in relation to the rash. Paul Helgason, aged twelve years, had for four years a large tumour in the right hypochondrium extending

* "Recherches Helminthologiques en Danemark et en Islande." 1866.
† *Arch. Gén. de Méd.*, 1869, xiii. 23.

to the umbilicus. The lad received a blow from a cow's horn upon the belly that caused the tumour to disappear. Almost immediately the body was covered with a rash like an urticaria, but it soon disappeared.

In another patient, a pregnant woman had a hepatic hydatid for six years. Three days after delivery, whilst lying quietly in bed, she was suddenly seized with acute pain in the abdomen; the tumour of the liver disappeared, and in a short time the skin presented a papular rash.

Hepatic hydatids may be accidentally ruptured in a variety of ways—such as blows, falls on the belly, by the wheels of a cart, or during an embrace in "a moment of exuberant affection."*

The Heart.—Hydatids of the heart occur under two conditions:—(1) The cyst may form in the muscle tissue of the heart—that is, in the walls of the ventricles or auricles; or (2) the vesicles are conveyed to the cavities of the right side of the heart as emboli, in consequence of the rupture of a hydatid cyst into some large vessel such as the vena cava.

When a cyst forms in the heart it may develop in the walls of the auricles. Of this many cases have been recorded.† In the walls of the ventricle they appear to be rare, and never attain a large size.‡ Graham states that in the Sydney University pathological museum there is a specimen in which a hydatid occupies the interventricular septum.

Cardiac hydatids usually terminate the life of the patient suddenly, sometimes without rupture; but as a rule, the fatal event is due to this cause, the cyst-contents being discharged into the pericardial, auricular, or ventricular cavities. When the cysts open into the right cavities of the heart the vesicles may be carried as emboli into the pulmonary artery. If into the left cavities, they may be carried into the systemic arteries. Oesterlen § recorded a case in which a girl, twenty-three years of age, developed gangrene of one leg. This was amputated and she died of pyæmia. A cyst the size of a pigeon's egg situated in the cardiac wall had burst into the

* Treves, *Trans. Clin. Soc.*, vol. xxi. 82.

† Moxon, *Trans. Path. Soc.*, vol. xxi. 99; and Graham, "Hydatid Disease," p. 134.

‡ *Trans. Path. Soc.*, vol. xv. 247.

§ Virchow's *Arch.*, bd. xlii. 404.

left auricle; hydatid membrane was discovered in adherent thrombi in the common iliac artery, and an entire vesicle was found in the deep femoral artery.

The Lungs.—Echinococcus cysts occur in the lungs under two conditions:—(1) The cyst, for it is usually single, may be situated wholly within the substance of the lung, and in most cases chooses the lower lobe, especially of the right lung; or (2) it may grow in the tissue immediately beneath the pulmonary pleura and project as an outgrowth from the lung into the pleural cavity.

When the cysts are small they occasion little inconvenience, but increasing in size they compress the lung and lead to hæmoptysis.

Apart from the mere pressure effects produced by the cyst, it is liable to rupture into the bronchial tubes, and pieces of membrane and vesicles are coughed up and indicate the nature of the case. When the cyst communicates with a bronchial tube, suppuration of the cyst is the inevitable consequence. Should the cyst rupture into the pleural cavity, empyema is the usual result.

It is well to bear in mind that because vesicles and membrane are coughed up it does not necessarily follow that the cyst is seated in the lung. Hepatic cysts are sometimes evacuated by this route.

Kidney.—A large number of cases of renal hydatids have been recorded. The cyst may occupy the loose connective tissue in the sinus of the kidney (Fig. 306), or grow immediately beneath the capsule. In each situation the hydatid may attain a very large size and lead to extensive atrophy of the renal tissue. When of small size they rarely give rise to trouble or even inconvenience during life, and their existence is only known in the course of a *post-mortem* examination.

There are good reasons for believing that an echinococcus colony of the kidney may rupture into the pelvis of the organ, the fluid and vesicles passing down the ureter to be discharged by the urethra. This is, of course, the most satisfactory mode of termination, except perhaps death of the parasite with subsequent calcification.

Hydatids of the **thyroid gland** are very rare; they usually

terminate by bursting into the trachea. This is always a fatal accident. Hydatids have been observed in the **adrenal**.

Birch-Hirschfeld reported an instance of a hydatid lying in the cavity of the **vermiform appendix,** which was dilated to twice the thickness of the thumb. It contained the remains of hydatid membrane, which presented under the microscope the characteristic lamination. The appendix contained a great number of semi-transparent vesicles, varying from a pin's

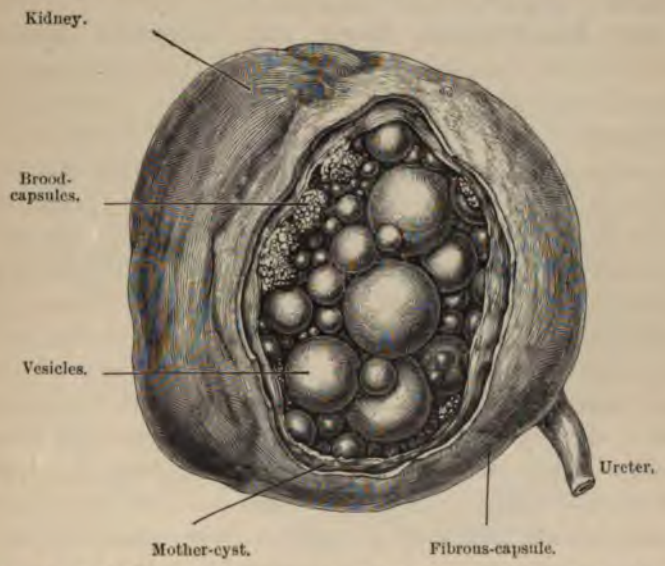

Fig. 306.—Echinococcus colony occupying the sinus of the kidney. (*Museum, Middlesex Hospital.*)

head to a pea in size: most of these were sterile. The communication between the appendix and the cæcum was obliterated. The walls of the appendix and its mucous membrane were atrophied from the pressure exerted by the cyst, and presented mosaic-like impressions caused by the pressure of the vesicles. The patient was a man thirty-eight years of age.

The Mamma.—Echinococcus cysts in this gland are very rare: records of at least twenty cases are accessible. The patients were in nearly all instances adult women. The disease takes the form of a slowly increasing, painless swelling, which may involve the whole breast or project as a smooth, elastic,

fluctuating tumour from some portion of its circumference. These cysts may exist in the breast for ten years or longer without producing much inconvenience: they have been reported with a capacity of twenty ounces. Occasionally the cyst suppurates. Diagnosis in countries where the echinococcus is not common is very difficult without the assistance of an exploratory puncture.

Drawings of echinococcus colonies of the mamma are given by Astley Cooper,* Bryant,† and others.

The Subperitoneal Tissue and Omentum.—Hydatids occur in these situations frequently in great numbers, and are often of large size. They may be pedunculated or sessile.

Muskett ‡ reported a remarkable case in which the patient was supposed to be suffering from a hydrocele the size of an emu's egg. When tapped it was found to be a hydatid cyst. As a rule, when abdominal hydatids are numerous they are of small size; when solitary they may be very large. Should a solitary cyst be sterile, its true nature is liable to be overlooked.

Hydatids grow in the mesentery, the mesorectum or between the layers of the broad ligament of the uterus. In men many cases have been recorded in which a cyst of large size grew in the connective tissue between the bladder and rectum.

Many echinococcus cysts described as growing in relation with the liver, spleen, and uterus really lie in the tissue immediately beneath the serous covering of these organs, and are in a sense subperitoneal. If these cases be included it will be clear that the subperitoneal tissue is an exceedingly favourite situation for hydatids.

Connective Tissue of the Trunk and Limbs.—Many cases have been recorded in which hydatids have been found in the axilla, orbit, posterior triangle of the neck, etc. Their nature is rarely suspected until the swelling is incised.

Uterus.—Echinococcus colonies have on several occasions been observed growing beneath the peritoneal investment of the uterus and forming a tumour as large as the patient's head. Cysts of this character clinically simulate ovarian and uterine

* "Diseases of the Breast," plate ix.

† "Diseases of the Breast," 1887, plate viii., figs. 3 and 4.

‡ *Australian Med. Gaz.*, 1886, p. 57.

tumours, especially subserous fibroids.* In one remarkable instance † an echinococcus cyst 11 cm. in diameter grew beneath the serous covering of the fundus of the uterus and opened into the right Fallopian tube, which was greatly distended, thrown into convolutions, and filled with vesicles. Freund ‡ has published an admirable report of some examples of pelvic hydatids (Fig. 307). It is the best contribution to the literature of this subject. His unique experience is probably due to the circumstance that his observations were made in

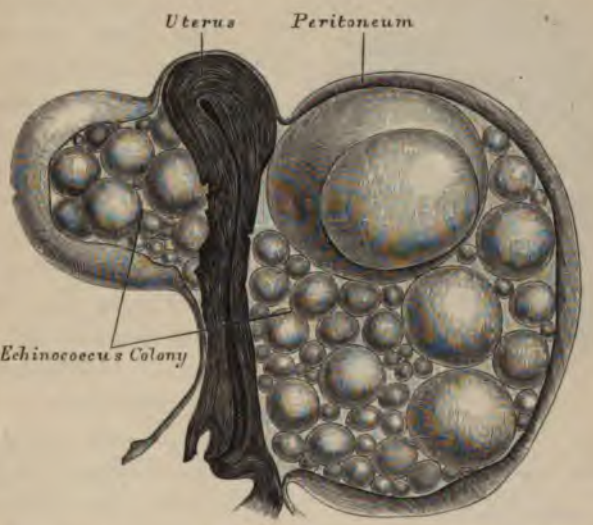

Fig. 307.—Echinococcus colonies in the mesometrium. (*After Freund.*)

Silesia—a European region second only to Iceland in the frequency with which the inhabitants become infected by echinococcus. It is exceptional to find vesicles in the Fallopian tubes, but in a woman thirty-two years of age, Doleris found them so stuffed with vesicles that they formed a large tumour reaching above the umbilicus. The mass weighed 2 kilogrammes, and consisted of the two tubes coiled upon themselves like small intestines, and so elongated that one measured 57 and the other 53 cm.

* Altormyan, *Lancet*, 1901, vol. i. 769; also Graham, "Hydatid Disease," p. 137.

† Maloney, *Australian Med. Journal*, 1879, p. 478

‡ *Gynäkologische Klinik*, Strassburg, 1885, bd. 1.

Ovary.—Neisser, in his oft-quoted paper, *Die Echinococcen Krankheit*, 1877, collected seven records of supposed hydatid cysts of the ovary, but an examination of the original reports shows that there was little reason in most of the cases to class them with hydatids. Indeed, one of the cases was an ordinary multilocular ovarian cyst. Even in the examples recorded in recent years now that the term "hydatid" is almost restricted to the true echinococcus cyst the cases recorded as "hydatid of the ovary" are conditions where the colony has grown primarily in the mesometrium, and implicated the ovary secondarily.

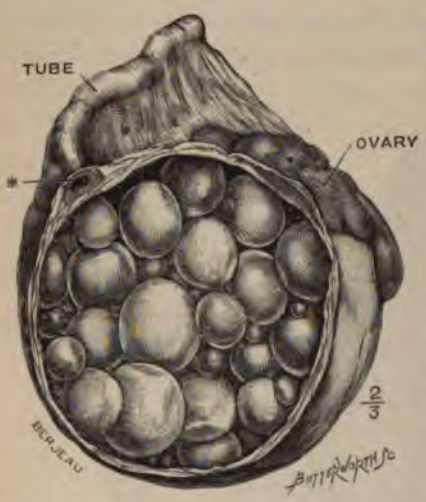

Fig. 308.—A mesosalpinx with the tube and ovary in transverse section. The ovary is flattened upon the wall of an echinococcus colony occupying the mesosalpinx. * The cut surface of the Fallopian tube.

The specimen represented in Fig. 308 was removed by the author from a woman forty-four years of age. It was as large as a turkey's egg, and freely movable in the belly. The colony arose in the mesosalpinx, and flattened out the ovary. As far as could be ascertained at the operation, there were no other cysts in the abdomen.*

Testis.—Echinococcus colonies have been seen in the scrotum, but I have never found any record of one within the tunica albuginea.

Brain.—Echinococcus cysts of the brain occur either in connection with the meninges or in the brain substance. In either situation they are not common. The cerebrum seems to be the most frequent seat of the cyst, and the right hemisphere lodges them twice as often as the left. In the cerebellum they are rare. When the cyst occupies the membranes it

* *Clinical Journal*, Oct. 23, 1901.

presses upon and produces a bay in the cortex of the cerebrum. It is often remarked by those who have recorded examples of intracranial hydatids that the damage produced by the cyst on the brain is out of proportion to the symptoms; but the same is equally true of almost all cerebral tumours. Hydatid cysts of the brain are nearly always sterile, and they are not furnished with the thick fibrous capsule which surrounds them in the liver and omentum.

Bones.—Echinococcus colonies are very rare in bones, and they seem to prefer the medullary cavities of long bones; the variety found in the bones of man is that known as *Echinococcus multilocularis*, in which there is no mother-cyst, but the medullary cavity of the bone is occupied by a multitude of vesicles (Fig. 309). The effect of these colonies on the bone is very extraordinary; they induce atrophy of its shaft, and at length the bone breaks from some trivial injury. In some instances operations have been undertaken for the relief of abscesses supposed to be due to necrosis, and when the bone has been opened up vesicles have escaped. When the colony occupies the end of a bone, the vesicles may invade the adjacent joint (Fig. 310).

Examples of echinococcus disease of bones may be seen in the following museums:—

The **Tibia.**—St. Mary's Hospital.

The **Femur.**—Royal College of Surgeons (Fig. 310); St. Thomas's Hospital.

The **Sacrum** and **Ilium.**—St. Bartholomew's Hospital.

The **Vertebra.**—St. George's Hospital (Fig. 312).

Spinal Canal.—Hydatids occur in connection with the spinal canal under three conditions:—

(1) *The hydatids are situated entirely within the canal.* Such cases are divisible into two sets: (*a*) those inside the dura mater, and (*b*) those lying in the connective tissue between the bone and dura mater (Fig. 311). In the great majority of cases the hydatid, though situated within the spinal canal, is external to the dura mater.

(2) *The hydatids affect the vertebræ and extend into the canal.* When the cysts are primary in the bone, they are of the multilocular variety (Fig. 312).

Fig. 309.-Multilocular hydatids of the shaft of the humerus: from a woman 35 years of age who suffered amputation through the shoulder joint. (*After Graham.*)

Fig. 310.—Remnants of a femur and tibia fenestrated by a colony of *Echinococcus multilocularis.* (*Museum of the Royal College of Surgeons.*)

(3) *The hydatids grow in the tissues outside the vertebræ, which are secondarily involved, the cyst extending into the canal.*

Colman * has recorded an example of hydatid cyst within the spinal canal, and collected the literature from 1807.

Treatment.—The principles on which echinococcus cysts and colonies are treated by surgeons consist—

(1) *In removing the entire cyst whenever it is possible.*

Failing this —

To incise the cyst-wall, evacuate the contents, and whenever possible remove the true cyst, and allow the cavity bounded by the capsule to close by granulation.

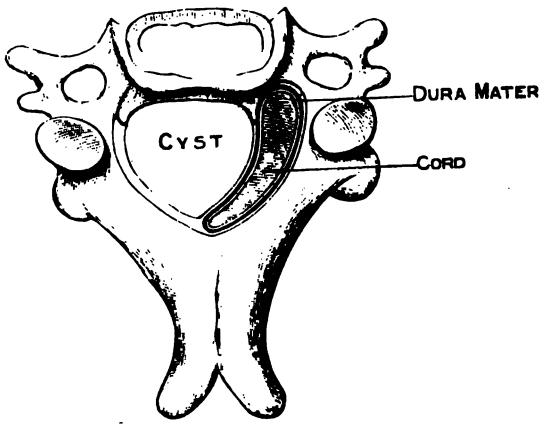

Fig. 311.—An extra-dural echinococcus cyst compressing the cord at the level of the third cervical vertebra. (*Semi-diagrammatic, modified from Colman.*)

The particular manner of carrying out the treatment varies with the situation of the cyst. When they hang as big as apples from the omentum, it is only necessary to expose the cysts through an incision in the belly wall, ligature the pedicle, and remove them. In many cases they are firmly adherent to surrounding structures. In these circumstances the fibrous capsule should be freely incised and the mother-cyst enucleated; the empty capsule rarely gives trouble. Suppurating cysts demand free incision and drainage.

In the case of the **liver** echinococcus colonies treated by incision, enucleation of the capsule, and free drainage give

* *St. Thomas's Hospital Reports*, vol. xxviii.

but little trouble. Great care should be taken thoroughly to remove the mother-cyst, for decomposition of this tissue when left is a source of grave danger. All meddling methods—as punctures with trocars, aspirations, and electrolysis—cannot be too strongly condemned.

Fig. 312.—Multilocular hydatid of the seventh cervical vertebra. Museum of St. George's Hospital. (*After Bennett.*)

Echinococcus cysts in the **lungs** require to be treated on the principles of empyema, and in this situation Lendon * particularly insists on the necessity of removing the mother-cyst.

In the case of **bones** the treatment consists of incision, evacuation of vesicles, and drainage. Exceptionally, when the bone is seriously damaged, fractured, or a large joint invaded, amputation has been found a necessity.

Echinococcus cysts within the **cranium** have been localised, exposed by trephining, and after evacuating the fluid the cyst has been successfully extracted (Verco,† Rennie and Crago ‡).

Echinococcus colonies in the **spinal canal** have been successfully submitted to surgery (Tytler and Williamson §).

* *Clinical Lectures on Hydatid Disease of the Lungs*, 1902

† *Brit. Med. Journal*, 1892, vol. ii. 1066.

‡ *Australian Medical Gazette*, 1902, 547.

§ *Brit. Med. Journal*, 1903, vol. i. 301.

INDEX TO TUMOURS.

Adenoma—
Fallopian, 328
hepatic, 290
intestinal, 226
mammary, 226
ovarian, 393
prostatic, 301
rectal, 226
sebaceous, 257
thyroid, 261
uterine cavity, 321
uterine cervix, 311

Angeioma—
cavernous, 157
nævus, 156
plexiform, 159
of breast, 157
of conjunctiva, 156
of heart, 158
of labium, 156
of larynx, 158
of lip, 156
of liver, 159
of muscles, 158
of rectum, 158
of subserous tissue, 159
of tongue, 157

Bursæ, 505

Cancer (carcinoma)—
duct, 247
gland, 232
melanotic, 83
rodent, 259
secondary 235
squamous-celled, 230
cancer-infection, 239
canceroderms 238
causes of 240
dissemination of, 235
inoperable, 253
lymph glands in, 234
nature of, 230
oöphorectomy in, 253
recurrence of, 251
treatment of, 249

Carcinoma (cancer)—
of anus, 288
of Bartholin's gland, 310

Carcinoma (cancer), *(continued)*.
of bladder, 300
of breast, 242
of cæcum, 286
of ciliary body, 83
of clitoris, 309
of conjunctiva, 231
of Cowper's gland, 308
of Fallopian tube, 331
of gall-bladder, 293
of gum, 269
of intestine, 284
of kidney, 298
of labium, 309
of larynx, 272
of lips, 266
of liver, 291
of lung, 241
of œsophagus, 275
of ovary, 333
of pancreas, 295
of penis, 307
of pharynx, 268
of pinna, 231
of prostate, 302
of rectum, 281
of scars, 231
of scrotum, 305
of sebaceous glands, 259
of stomach, 278
of testis, 306
of thyroid, 263
of tongue, 268
of tonsil, 269
of ureter, 299
of urethra, 304
of uterus, 312
of vagina, 309

Chondroma—
of bone, 32
of joints, 36
of larynx, 35
of pelvis, 33
of salivary glands, 34

Cysts—
chyle-cysts, 490
dacryops, 439
dental, 62
Gärtnerian, 475
hydroceles, 483
hydrometra, 434

Cysts (*continued*).
hydronephrosis, 440
Müllerian, 482
pancreatic, 437
paroöphoronic, 466
parovarian, 470
ranula, 435
testicular, 478
tubulo-cysts, 460
vitello-intestinal, 460
of cornea, 358
of finger, 356
of gall-bladder, 434
of hyaloid canal, 439
of iris, 358
of lacrimal gland, 439
of mamma, 228
of neck, 163, 498
of ovary, 392
of pharynx, 492
of thyroid gland, 261
of urachus, 464

Deciduoma, 76
Dermoids—
dermoid patches, 388
ovarian dermoids, 392
sequestration dermoids, 335
tubulo-dermoids, 359
of back, 336
of cæcum, 419
of conjunctiva, 388
of dura mater, 352
of face, 342
of labium, 338
of neck, 340
of nose, 351
of orbit, 348
of ovary, 392
of palate, 430
of pharynx, 430
of pinna, 382
of rectum, 366
of sacrum, 366
of scalp, 352
of scrotum, 338
of spine, 336
of sternum, 341
of testicle, 339
of thorax, 339
of tongue, 359
Diverticula—
ganglion, 502
intestinal, 491
laryngocele, 498
œsophageal, 495
pharyngeal, 492
synovial, 500
tracheal, 495
vesical, 491

Echinococcus colonies—
of adrenal, 541
of bones, 545
of brain, 544
of Fallopian tube, 543
of heart, 539
of kidney, 540
of liver, 537
of lung, 540
of mamma, 541
of omentum, 542
of ovary, 544
of spine, 545
of testis, 544
of thyroid, 540
of uterus, 542
of vermiform appendix, 541
Endothelioma—
of gum, 166
of mamma, 166
of palate, 108
of parotid, 111
of thyroid, 166
Epithelial Pearls, 430
Exostosis, 42

Fibroids—
cervix-fibroids, 174
latent fibroids, 173
mesometric, 176
ovarian, 203
uterine, 169
utero-sacral, 179
Fibroma, 16
Fistula—
auricular, 382
branchial, 370
cervical, 359
coccygeal, 337
mandibular, 344
nasal, 351
sternal, 341

Glioma—
of brain, 149
of cord, 154
of retina, 152
Guttural pouches of horses, 496

Hair-fields, 527
Horns—
cicatrix-horn, 223
nail-horn, 224
sebaceous horn, 219
wart-horn, 220
Hydroceles—
canal of Nuck, 487
congenital, 486
encysted, 481
fourth ventricle, 515

Hydroceles (*continued*).
funicular, 486
hernial sac, 487
omental, 489
ovarian, 487
tunica vaginalis, 483
Hydrocephalus, 510
Hydronephrosis—
ante-natal, 442
bilateral, 440
intermitting, 445
unilateral, 444

Ileum—
imperforate, 463
septate, 463
Implantation cysts—
cornea, 358
finger, 356
iris, 358

Lipoma—
treatment, 31
intermuscular, 25
intramuscular, 27
meningeal, 29
periosteal, 27
subcutaneous, 19
submucous, 23
subserous, 21
subsynovial, 25
arborescens, 25
of bones, 27
of broad ligament, 22
of colon, 24
of conjunctiva, 23
of fingers, 20
of foot, 20
of hand, 20
of heart, 27
of hernial sacs, 22
of jejunum, 25
of joints, 25
of labium, 22
of larynx, 24
of lips, 24
of muscles, 25
of neck, 22
of nerves, 28
of palm, 29
of scalp, 21
of scrotum, 22
of sole, 15, 20
of spermatic cord, 22
of spinal cord, 29
of stomach, 24
of tongue, 25
Lymphangeioma—
Lymphatic cyst, 161
Lymphatic nævus, 163

Melanoma (see Sarcoma)
Moles, 388
Molluscum fibrosum, 137
Myeloma—
of clavicle, 68
of femur, 65
of humerus, 65
of mandible, 65
of maxilla, 65
of patella, 68
of radius, 66, 67
of tibia, 65, 66
of ulna, 65
Myoma, 18
Myxoma, 17

Neural Cysts—
hydrocele of fourth ventricle, 515
hydrocephalus, 510, 530
meningocele (cranial), 516
spina bifida, 521
neuro-fibromatosis, 137
Neuroma—
ganglionic, 135
malignant, 142
neuro-fibroma, 134
plexiform, 143
of lingual nerve, 147
of musculo-spiral nerve, 146
of occipital nerve, 145
of optic nerve, 151
of sciatic nerve, 146

Odontomes—
cementome, 50
compound, 51
composite, 55
epithelial, 47
fibrous, 49
follicular, 48
radicular, 53
Osteoma—
cancellous, 41
compact, 40
of auditory meatus, 41
of frontal sinus, 41
of mandible, 40
of maxilla, 40
of odontoid process, 42
of orbit, 40
Painful subcutaneous tubercle, 134

Papilloma (Warts)—
cutaneous, 208
intracystic, 211
psammoma, 214
solitary, 208
villous, 212
of bladder, 212
of choroid plexus, 214

Papilloma (*continued*).
of skin, 208
of larynx, 210
of œsophagus, 210
of peritoneum, 467
of renal pelvis, 213
Post-anal dimples, 337
Pre-cancerous conditions, 268
Psammoma—
of fourth ventricle, 214
of lateral ventricle, 214
of spinal membrane, 218
Pseudo-cysts—
bursæ, 504
diverticula, 491
neural cysts, 510

Rodent ulcer, 259

Sarcoma—
alveolar, 80
chondro-, 73
lympho-, 71
melano-, 78
myo-, 73
round-celled, 70
spindle-celled, 71
of adrenal, 131
of bone, 95
of breast, 119
of digits, 81
of eyeball, 82
of gum, 108
of jaw, 106
of kidney, 121
of mamma, 119
of mediastinum, 88

Sarcoma (*continued*).
of muscles, 92
of nasal septum, 105
of naso-pharynx, 105
of nerves, 93, 142
of ovary, 116
of palate, 108
of parotid, 108
of prostate, 116
of retina, 152
of skin, 80
of teeth, 107
of testicle, 73, 115
of thyroid, 91
of tongue, 73
of uterus, 76
of uveal tract, 82
of vagina, 94
of veins, 92
Spina bifida—
complications of, 531
species of, 522
masked, 527
meningocele, 524
meningo-myelocele, 523
myelocele, 522
syringo-myelocele, 523
treatment of, 531

Tails, 532
Teratoma—
acardiacs, 427
conjoined twins, 421
parasitic acardiacs, 427
pharyngeal, 430

Warts (see Papilloma)

INDEX TO ORGANS.

Adrenal—
tumours, 121
Adrenals, accessory, 127
tumours, 127
Adrenal goitres, 128
Antrum—
cancer, 272
Anus—
cancer, 288
melanoma, 81

Bartholin's Glands—
carcinoma of, 310
Bladder—
cancer, 300
diverticula, 491
myoma, 18
villous tumours, 212
Bone—
chondroma, 32
hydatids, 545
lipoma, 27
myeloma, 65
osteoma, 39
sarcoma, 95
Brain—
glioma, 149
hydatids, 544
neuroma, 135
psammoma, 214
Breast (see Mamma)

Cicatrix—
cancer, 231
horns of, 223
Clitoris—
cancer, 309
Colon—
carcinoma of, 286
Conjunctiva—
angeioma of, 156
cancer, 231
dermoid patches, 388
lipoma, 23
moles, 388
Cowper's Gland—
carcinoma of, 308

Digits—
bursa, 505
chondroma, 32

Digits (*continued*)
cysts, 373
lipoma, 20
melanoma, 83
Ducts—
functionless, 460
obsolete, 359
Dura mater—
dermoids of, 352

Eyeball—
carcinoma, 83
cysts (of cornea), 358
cysts (of iris), 358
glioma, 152
melanoma, 83
sarcoma, 79
Eyelid—
coloboma, 389
dermoids, 342
nævi, 156

Face—
angeioma, 156
cancer, 259
dermoid, 342
fissures, 342
moles, 386
mandibular tubercles, 345
Fallopian tube—
adenoma, 328
carcinoma, 331
hydatids, 543
pseudo-cysts, 507
Fingers (see Digits)

Gall Bladder—
cancer, 293
cystic, 434
hydatids, 538
Gums—
cancer, 269
endothelioma, 166
sarcoma, 108

Hands—
chondroma, 32
cysts (implantation), 356
synovial, 500
ganglion, 500
lipoma, 20

Heart—
angeioma, 158
hydatids, 539
lipoma, 27

Intestine—
adenoma, 226
carcinoma, 284
diverticula, 491
lipoma, 24

Iris—
coloboma, 409
cysts, 358
sarcoma, 82

Jaws—
cancer, 269
endothelioma, 114
exostosis, 39, 43
odontome, 47
sarcoma, 106

Joints—
lipoma, 25
loose bodies, 36
synovial cysts, 500

Kidney—
cancer, 298
congenital cysts, 512
hydatids, 540
hydronephrosis, 440
papilloma, 213
pyonephrosis, 450
sarcoma, 121

Labium—
angeioma, 156
cancer, 309
cysts (sebaceous), 278
lipoma, 22

Lacrimal gland—
chondroma, 114
dacryops, 439

Larynx—
angeioma, 158
cancer, 272
diverticula, 498
lipoma, 24
lympho-sarcoma, 71
papilloma (warts), 210

Lips—
angeioma, 156
cancer, 267
lymphangeioma, 161

Liver—
adenoma, 290
angeioma, 159
carcinoma, 291
hydatids, 537

Lungs—
carcinoma, 241
hydatids, 539

Mamma—
adenocele, 225
adenoma, 225
angeioma, 157
carcinoma (acinous), 242
carcinoma (duct), 247
chondro-sarcoma, 73
hydatids, 541
sarcoma, 119

Mesentery—
chyle cysts, 490
lipoma, 23

Muscles—
angeioma, 158
sarcoma, 92

Neck—
cysts, 161, 498
dermoids, 340
fistulæ, 359

Nerves—
neuroma, 134
sarcoma, 142

Œsophagus—
carcinoma, 275
diverticula, 495
myoma, 18
papilloma, 210

Ovary
adenoma, 393
carcinoma, 333
cysts, 392
dermoid, 398
fibroma, 203
hydrocele, 487
papilloma, 467
sarcoma, 116

Palate—
cancer, 269
dermoid, 430
epithelial pearls, 432
moles, 388
sarcoma, 108

Pancreas—
carcinoma, 295
cysts, 437

Parotid gland—
chondro-sarcoma, 108
cysts (ranula), 435
sarcoma, 108

Parovarium—
cysts, 470

Penis—
carcinoma, 307
horns, 235
papilloma, 221
Pinna—
cancer, 231
dermoids, 382
fistula (sinus), 382
horns, 235
Pituitary body—
adenoma, 266
Prostate—
adenoma, 301
carcinoma, 302

Rectum—
adenoma, 226
angeioma, 158
carcinoma, 281
dermoids, 366
polypus, 226
Retina (see also Eyeball)—
sarcoma, 152

Sacrum—
dermoids, 366
lipoma, 30
spina bifida, 521
teratoma, 424
Scalp—
cephalhydrocele, 520
cephalhæmatoma, 518
dermoids, 352
horns, 221
lipoma, 21
meningocele, 516
molluscum fibrosum, 139
sebaceous cysts, 254
Scrotum—
cancer, 305
dermoids, 338
horns, 221
hydrocele, 483
Skin—
angeioma, 157
cysts (sebaceous), 254
fibroma (molluscum), 160
horns, 219
lymphangeioma, 161
melanoma, 83
moles, 388
papilloma, 208
Spinal column—
half-vertebra, 529
hydatids, 545
lipoma, 29
osteoma, 41

Spinal column (*continued*).
sarcoma, 109
spina bifida, 521
Spinal cord—
glioma, 154
lipoma, 29
psammoma, 214
Stomach—
carcinoma, 278
lipoma, 24
myoma, 18
Submaxillary gland
chondroma, 3
ranula, 435
Subserous tissue—
angeioma, 159
lipoma, 21

Teeth—
odontomes, 47
Testicle—
cancer, 306
dermoids, 339
hydrocele, 509
myo-sarcoma, 73
sarcoma, 115
Thymus—
lympho-sarcoma, 71
Thyroid duct, 359
Thyroid gland—
accessory thyroids, 366
adenoma, 261
bronchocele, 261
carcinoma, 263
cysts, 261
hydatids, 540
Tongue—
angeioma, 157
cancer, 268
dermoids, 359
ichthyosis, 268
lipoma, 25
lymphangeioma, 161
lympho-sarcoma, 71
macroglossia, 147, 161
Tonsil—
cancer, 269
lympho-sarcoma, 71

Ureter—
cancer, 304
inadequate, 471
Urethra—
cancer, 304

Uterus—
adenoma, 311
carcinoma, 312
deciduoma, 76
fibroids, 169
hydatids, 542
sarcoma, 76

Uveal tract—
melano-carcinoma, 83
melano-sarcoma, 79

Vagina—
cancer, 309

Vagina (*continued*).
cysts, 495
sarcoma, 94

Vermiform appendix—
cancer, 284
hydatids, 541

Vertebra—
half-vertebra, 530
osteoma, 41
sarcoma, 109

Vulva—
cancer, 308

PRINTED BY CASSELL & COMPANY, LIMITED, LA BELLE SAUVAGE, LONDON, E.C.

LANE MEDICAL LIBRARY

To avoid fine, this book should be returned on or before the date last stamped below.

M651 Bland-Sutton, Sir J.
B64 Tumours.
1903 66933

NAME	DATE DUE